



Case Report: Psoriatic Arthritis Leading to Temporomandibular Joint Ankylosis

Shaharyar Khan Niazi^{1*}, Abubakar Abdullah² and Muhammad Afzal³

¹Department of Oral And Maxillofacial Surgery, Armed Forces Institute of Dentistry, Islamabad, Pakistan

²Department of Oral Medicine, National University of Medical Sciences, Islamabad, Pakistan

³Consultant Oral And Maxillofacial Surgeon, 21 Military Dental Centre, Quetta, Pakistan

***Corresponding Author:** Shaharyar Khan Niazi, Department of Oral And Maxillofacial Surgery, Armed Forces Institute of Dentistry, Islamabad, Pakistan.

Received: January 08, 2019; **Published:** February 20, 2019

Abstract

Psoriatic arthritis is an inflammatory condition that affects 30% of patients suffering from psoriasis. Involvement of Temporomandibular joint in psoriatic arthritis leading to temporomandibular joint ankylosis is rare with less than 50 reported cases. Here, a case of severe dysfunction of TMJ as a result of Psoriatic arthritis in a young patient is reported, which was treated successfully with a combination of surgery and rigorous physical therapy.

Keywords: Psoriatic Arthritis; TMJ Ankylosis; TMJ Arthroplasty

Introduction

Psoriasis is an inflammatory disorder that primarily involves skin and joints. This disease affects roughly 2 - 3% of the population. Its peak incidence occurs between 16 to 22 years of age and then between 57 to 60 years, with no established gender predilection. About 30% of patients with psoriasis develop psoriatic arthritis, which results in significantly compromised patient's quality of life and increased risk of mortality [1,2].

Psoriatic arthritis was first identified by Bazin in 1860, and was described often in literature after that as a clinical phenomenon distinct from other rheumatic diseases [7]. However, it wasn't until 1965 that the first case of involvement of TMJ in psoriatic arthritis was reported [8]. Recent evidence suggests that psoriatic arthritis of the TMJ although rarely reported in literature, occurs frequently, with one third to one half of patients of psoriatic arthritis exhibiting some degree of TMJ involvement [12].

In this paper, we present a severe case of Psoriatic arthritis of the temporomandibular joint leading to ankylosis.

Case Report

A 23 years old male presented with a history of slowly progressing limitation of mouth opening for the past two years. Pa-

tient was diagnosed with psoriasis seven years ago when he developed cutaneous psoriatic lesions on his scalp and he was given steroids and immune modulating drugs for this condition. When the patient presented, he had a mouth opening of only 7 mm with severe limitation of lateral excursive movements. No facial asymmetry was present. Patient was negative for RA factor. Patient was on mouth opening exercises with the help of wooden sticks and mouth opening device, but mouth opening keep on decreasing with these measures. CBCT was advised which revealed ankylosis of the condylar process bilaterally.

A diagnosis of TMJ ankylosis resulting from psoriatic arthritis was made, and surgical intervention was planned.

Arthroplasty of the temporomandibular joint was done with temporalis fascia as the interpositional material, using a pre-auricular approach bilaterally. An intra-operative mouth opening of 46 mm was achieved. Post operatively, patient was advised to follow a strict regimen of rehabilitation, including vigorous mouth opening exercises and physiotherapy. Temporal branch of facial nerve was partially non-functional, which was recovered on third week follow up. The patient was advised to consult his primary physician for generalized control of psoriasis on regular basis. Mouth open-

ing and masticatory function of the jaw remained satisfactory after 6 months of follow-up.

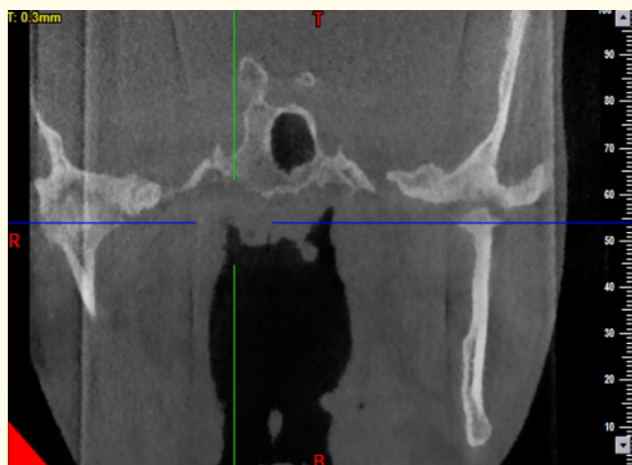


Figure 1a: Coronal view showing anykylosed right TMJ.

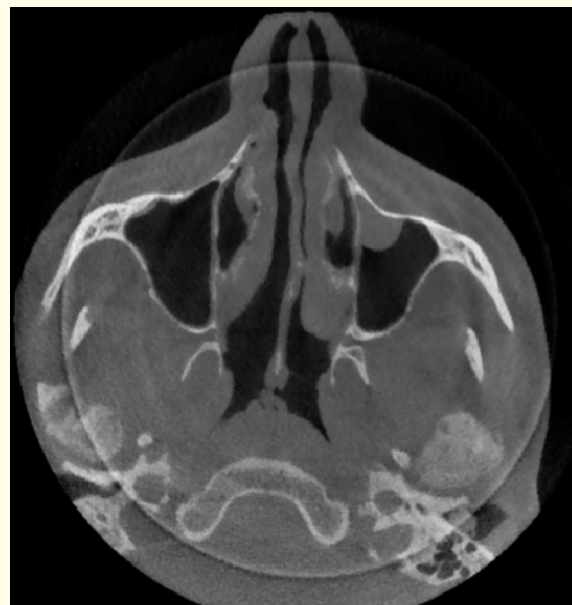

Figure 2: AAxial section of CBCT showing deformed condylar processes of mandible.

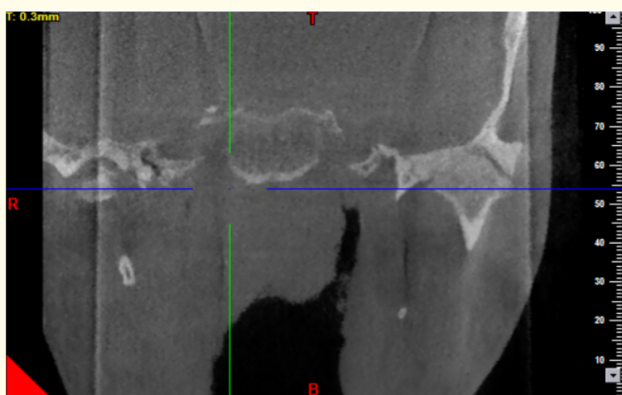


Figure 1b: Ankylosed left TMJ.

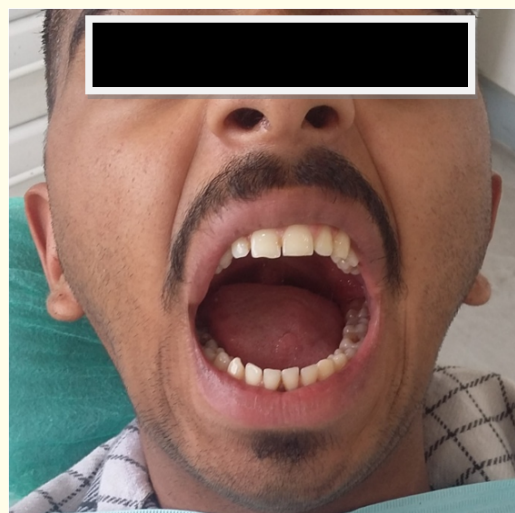

Figure 3: Post-operative mouth opening.

Discussion

Psoriasis (Pso) is a systemic inflammatory disease characterized mainly by skin lesions and joint involvement, which affects about 2 - 3% of the population. It is a multifaceted disease with immunological and genetic components. Apart from the physical manifestations of the disease, the associated disability and disfigurement has significant psychosocial implications for the patient [1].

Psoriasis is clinically classified into two groups: Pustular psoriasis and Non-pustular psoriasis. Psoriatic arthritis (PsA) is one of

the six subgroups of non-pustular psoriasis [3]. Like psoriasis, psoriatic arthritis is also a multifactorial disease with physical injury and stress affecting the classical auto-immune pathways [4]. Five patterns of joint involvement have been described in patients with PsA, with asymmetrical oligoarthritis being the most common pattern. Other patterns are distal interphalangeal arthritis, Arthritis mutilans, Symmetrical polyarthritis and ankylosing spondylitis [5].

Psoriatic arthritis classically presents as an arthritis in the presence of cutaneous psoriatic lesions and absence of serological markers for rheumatoid arthritis. It commonly affects the joints asymmetrically, with a significant predilection for the interphalangeal joints [8]. However, cutaneous psoriasis precedes psoriatic arthritis in only 60-70% of the patients, and psoriatic arthritis may develop independently in a large number of cases [4]. The rheumatoid factor may also be present in up to 5% of healthy patients [12]. Additionally, the non-specific clinical and radiographic features of PsA complicate its diagnosis [11].

PsA of the TMJ was first described in 1965 by Franks and Lundberg [8]. It occurs more frequently in males is usually characterized by non-specific clinical findings with intervening periods of spontaneous remissions. Common clinical features are pain and tenderness in TMJ and muscles of mastication, limited range of motion and clicking sounds on jaw functioning [9,11]. Radiographically, the disease presents most commonly as erosive changes in the condyle. Other findings include flattening, sclerosis, joint space narrowing, and proliferative lesions [7,11]. Due to their non-specific nature, these findings cannot differentiate PsA from other forms of arthritis.

Clinical features of PsA rarely correlate well with the radiographic findings and a diagnosis made on the basis of clinical examination tends to under-estimate the extent of the disease. Therefore, radiographic evaluation is advisable in all cases of PsA. Conventional radiography is the most widely used modality [11,12]. CT scan is superior in terms of its sensitivity in detecting early degenerative changes in the hard tissues of the joint, as well as for comparing the progress before and after treatment [10]. However, CT scan cannot detect soft tissue changes which are hallmark of the early stages of TMJ arthritis. Therefore, MRI is a more reliable tool for investigating psoriatic arthritis of the TMJ [11].

The primary aim of the treatment is to relieve the symptoms and restore function of the mandible. This is achieved initially with a combination of soft diet, anti-inflammatory drugs, physical therapy and splints. A strict regime of functional exercises can be indispensable in restoring the range of motion and functional rehabilitation. These measures can be sufficiently effective in relieving the acute exacerbations in as many as 80% of the cases. In cases where conservative management does not provide significant benefit to the patient, arthrocentesis or arthroscopy may be done. Myofascial spasms can be treated with long acting local anesthetic or botulinum injection in the masseter and temporalis muscles [9,12].

More invasive procedures may be considered only when conservative management options have been exhausted because of likelihood of the Koebner phenomenon and the possibility of secondary degenerative changes as a result of the surgical insult [9,12].

In cases where lack of functional stability can be demonstrated as a precipitating factor by use of temporary crowns and hard splints, condylotomy resulting in formation of a functionally stable pseudo-joint has been advocated as the first line surgical option for treating intractable myofascial symptoms.¹⁰ Discectomy is carried out for grossly damaged articular discs, with or without interpositional grafts, but the graft may further reduce jaw mobility due to scarring. Condyloplasty is performed to restore the function of mandible in the most severe cases where the arthritis has progressed to the ankylosis of the joint. The last resort for treating severely damaged, degenerative joints is total joint replacement, using prostheses modified from Christensen's design, which have a more predictably successful outcome as compared to a costochondral graft [12].

Conclusion

Psoriatic Arthritis involving the temporomandibular joint is a rarely reported phenomenon, therefore, the incidence of the disease may be grossly underestimated. As a result of lack of good quality literature on the subject, no evidence based guidelines are available for the treatment of this disease. In our experience, meticulous evaluation of the extent of disease and a treatment plan involving surgical intervention and rigorous physical therapy, tailored to individual patient needs results in a favorable outcome.

Bibliography

1. Kim WB, et al. "Diagnosis and management of psoriasis". *Canadian Family Physician* 63.4 (2017): 278-285.
2. Gladman DD. "Recent advances in understanding and managing psoriatic arthritis". *F1000Research* 5 (2016): 2670.
3. Kerschbaumer A, et al. "An overview of psoriatic arthritis - epidemiology, clinical features, pathophysiology and novel treatment targets". *Wiener klinische Wochenschrift* 128.21-22 (2016): 791-795.
4. Moll J and Wright V. "Psoriatic arthritis". *Seminars in Arthritis and Rheumatism* 3.1 (1973): 55-78.
5. Sarac G, et al. "A brief summary of clinical types of psoriasis". *Northern Clinics of Istanbul* 3.1 (2016): 79-82.

6. Cather JC., *et al.* "Psoriasis and Psoriatic Arthritis". *The Journal of Clinical and Aesthetic Dermatology* 10.3 (2017): S16-S25.
7. Koorbusch GF, *et al.* "Psoriatic arthritis of the temporomandibular joints with ankylosis". *Oral Surgery, Oral Medicine, Oral Pathology* 71.3 (1991): 267-274.
8. Rasmussen OC and Bakke M. "Psoriatic arthritis of the temporomandibular joint". *Oral Surgery, Oral Medicine, Oral Pathology* 53.4 (1982): 351-357.
9. Stimson CW and Leban SG. "Recurrent ankylosis of the temporomandibular joint in a patient with chronic psoriasis". *Journal of Oral and Maxillofacial Surgery* 40.10 (1982): 678-680.
10. Puricelli E., *et al.* "Clinical-surgical treatment of temporomandibular joint disorder in a psoriatic arthritis patient". *Head and Face Medicine* 9 (2013): 11.
11. Wang ZH., *et al.* "Ankylosis of Temporomandibular Joint caused by Psoriatic Arthritis: A Report of Four Cases with Literature Review". *Chinese Journal of Dental Research* 17.1 (2014): 49-55.
12. Sidebottom AJ and Salha R. "Management of the temporomandibular joint in rheumatoid disorders". *British Journal of Oral and Maxillofacial Surgery* 51.3 (2013): 191-198.

Volume 3 Issue 3 March 2019

© All rights are reserved by Shaharyar Khan Niazi, *et al.*