

## An Impression Technique for Patient with Occurrence of Strong Gag Reflex

Fellippo R Verri<sup>1\*</sup>, Ronaldo S Cruz<sup>2</sup> and Victor E de Souza Batista<sup>3</sup>

<sup>1</sup>Adjunct Professor, Department of Dental Materials and Prosthodontics, Araçatuba Dental School (UNESP), Univ Estadual Paulista, Araçatuba, Brazil

<sup>2</sup>PhD Candidate, Department of Dental Materials and Prosthodontics, Araçatuba Dental School (UNESP), Univ Estadual Paulista, Araçatuba, Brazil

<sup>3</sup>Associate Professor, Department Prosthodontics, Presidente Prudente Dental School, University of Western São Paulo - UNOESTE, Presidente Prudente, São Paulo, Brazil

\*Corresponding Author: Fellippo Ramos Verri, Adjunct Professor, Department of Dental Materials and Prosthodontics, Araçatuba Dental School (UNESP), Univ Estadual Paulista, Araçatuba, Brazil.

Received: January 21, 2019; Published: February 18, 2019

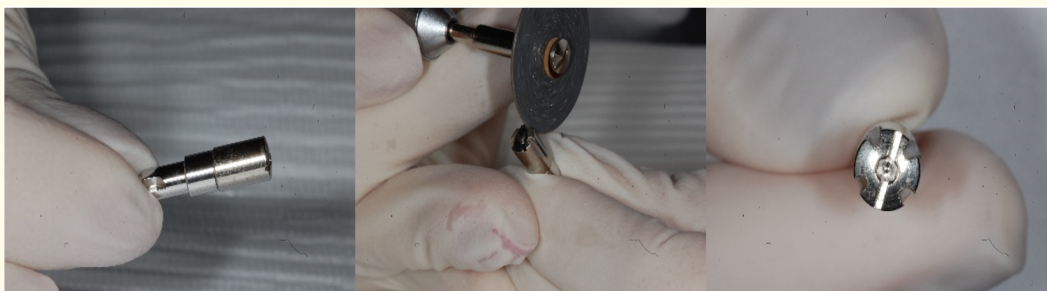
### Introduction

One of the most important factors for the success of the implant prosthesis is the accuracy of the definitive cast, which relies on the accuracy of the impression technique [1]. Traditionally, the close tray and open tray techniques are used to make an impression in implant dentistry and both techniques present advantages and disadvantages [2-4]. In the first one, the transfer technique uses tapered copings associated with a closed tray to make the impression. In the last one, the pick-up impression uses square copings and an open tray [1]. Studies report that open tray associated with square transfer is more accurate when the closed tray impression technique [2,3,5]; however, in some clinical situations, the use of open tray technique may not be used, such as for patients with a strong gag reflex caused by the tray, limited interarch space and limited mouth opening, situations which difficult the access to the transfer screw.


The present article describes a modified alternative partial impression technique for patient with occurrence of strong gag reflex and limited mouth opening.

### Procedure

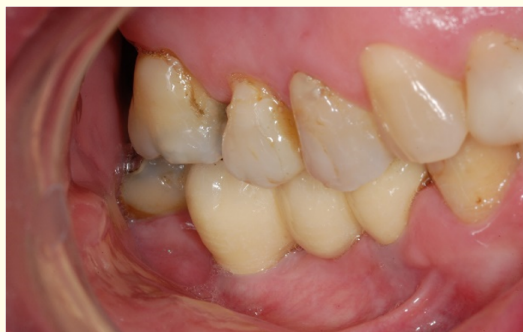1. Identify if the patient shows situations that limit the use of open tray technique
2. Select a healing screw with appropriated length (Figure 1a).
3. Perform grooves on the healing screw with a carborundum disc (Figure 1b) following polishing, creating indexes (Figure 1c).
4. Place the healing screw in the dental implant (Figure 2a)
5. Make the impression with a polyvinyl siloxane material.
6. Remove the impression from the mouth (Figure 2b). The healing screw will be retained in the dental implant when the set impression is removed. Remove it and place in the analogue of the implant (Figure 2c).
7. Place the assembly healing screw/analogue in the dental impression.
8. Send the impression for the following steps to fabricate the prosthesis fabrication.



**Figure 1:** Process to customize the healing screw. A, Healing screw. B, Performing the grooves on the healing screw. C, Healing screw customized.



**Figure 2:** A, Healing screw placed in the dental implant. B, Aspect after the dental impression. C, Assembly healing screw/analogue placed in the dental impression.



**Figure 3:** Definitive dental prosthesis.

5. Assuncao WG, *et al.* "Evaluation of transfer impressions for osseointegrated implants at various angulations". *Implant Dentistry* 13.4 (2004): 358-366.

**Volume 3 Issue 3 March 2019**

**© All rights are reserved by Fellippo R Verri, *et al.***

### Bibliography

1. Linkevicius T, *et al.* "The influence of implant placement depth and impression material on the stability of an open tray impression coping". *Journal of Prosthetic Dentistry* 108 (2012): 238-243.
2. Lee H, *et al.* "The accuracy of implant impressions: a systematic review". *Journal of Prosthetic Dentistry* 100 (2008): 285-291.
3. Burns J, *et al.* "Accuracy of open tray implant impressions: an in vitro comparison of stock versus custom trays". *Journal of Prosthetic Dentistry* 89 (2003): 250-255.
4. Marotti J, *et al.* "Accuracy of a self-perforating impression tray for dental implants". *Journal of Prosthetic Dentistry* 112.4 (2014): 843-848.