



Major Techniques for Microneedling in Reducing Acne Scarring

Carlos Alberto do Valle¹, Rhamon Ferreira do Valle¹, Rhuane Carlos Ferreira do Valle¹, Luciana Nunes de Sá Ferraz¹ and Idiberto José Zotarelli Filho^{2,3*}

¹Santa Isabel Dental Clinic, R. Dr. Luís Aires, São Paulo - SP, Brazil

²University Center North Paulista (Unorp) Dental School, São José do Rio Preto – SP, Brazil

³Post Graduate and Continuing Education (Unipos), Department of Scientific Production, São José do Rio Preto SP, Brazil

***Corresponding Author:** Idiberto José Zotarelli Filho, University Center North Paulista (Unorp) Dental School, Post Graduate and Continuing Education (Unipos), Department of Scientific Production, São José do Rio Preto SP, Brazil.

Received: November 15, 2018; **Published:** December 26, 2018

Abstract

Introduction: Acne is a chronic dermatosis that comes from the pilosebaceous follicle and its pathophysiology interfere on several factors such as: genetic, hormonal, sebaceous hyperproduction, follicular hyperkeratinization and increased colonization of *Propionibacterium acnes*.

Objective: Thus, the present study aimed to address the benefits of microneedle removal for all indications, with an emphasis on acne scars, highlighting how much the microneedle treatment is effective in reducing and deepening acne scars. Methods: The literature search was conducted through online databases: Pubmed, Periodicos.com and Google Scholar. It was stipulated deadline, and the related search covering all available literature on virtual libraries. A total of 25 articles were evaluated in full, and 15 were included and discussed in this study.

Final Considerations: The literature showed that acne is a chronic dermatosis that is classified clinically in four levels: degrees I, II, III, IV. As a form of treatment, in this study, it was suggested the micro needling that is a therapy that leads to the production of collagen in the skin from a mechanical stimulus, through a roller composed of microneedles.

Keywords: Microneedling; Acne; Healing; Growth factors; Tissue Regeneration

Introduction

Acne is a chronic dermatosis that comes from the pilosebaceous follicle and its pathophysiology interfere on several factors such as: genetic, hormonal, sebaceous hyperproduction, follicular hyperkeratinization and increased colonization of *Propionibacterium acnes* in the glandular duct (bacterium that is responsible for proteases hydrolytic) are the main causes of its emergence [1].

When clinically observed acne, it is classified as grade I, grade II, grade III and grade IV, grade I am being the mildest form of the lesion and grade IV, the most severe form of the disease [2].

Among the various treatments for the disease, it is worth mentioning the microagglutination, which induces the production of collagen in the skin from a mechanical stimulus, through a roller

composed of microneedles. The roller is made of polyethylene and consists of stainless steel and sterile needles, which are positioned proportionally in rows, totaling between 192 and 540 units. The length of the microneedles ranges from 0.25 mm to 2.5 mm in diameter [1].

In view of the effects described in the literature on microaggregation performance in cell regeneration, vasodilatation, cell maturation and type III collagen synthesis and exchange for type I collagen over a long period of time is observed.

Thus, the present study aimed to address the benefits of microneedle removal for all indications, with an emphasis on acne scars, highlighting how much the microneedle treatment is effective in reducing and deepening acne scars.

Methods

Experimental and clinical studies were included (case reports, retrospective, prospective and randomized trials) with qualitative and/or quantitative analysis. Initially, the key words were determined by searching the DeCS tool (Descriptors in Health Sciences, BIREME base) and later verified and validated by MeSh system (Medical Subject Headings, the US National Library of Medicine) in order to achieve consistent search.

Mesh Terms

The main descriptors (Mesh Terms) used were Microneedling. Acne. Healing. Growth factors. Tissue Regeneration. For further specification, the “reduction of healing” description for refinement was added during searches, following the rules of systematic

review-PRISMA (Transparent reporting of systematic reviews and meta-analyzes-<http://www.prisma-statement.org/>).

The literature search was conducted through online databases: Pubmed, Periodicos.com and Google Scholar. It was stipulated deadline, and the related search covering all available literature on virtual libraries.

Series of articles and eligibility

A total of 25 articles were evaluated in full, and 15 were included and discussed in this study.

Flow Chart

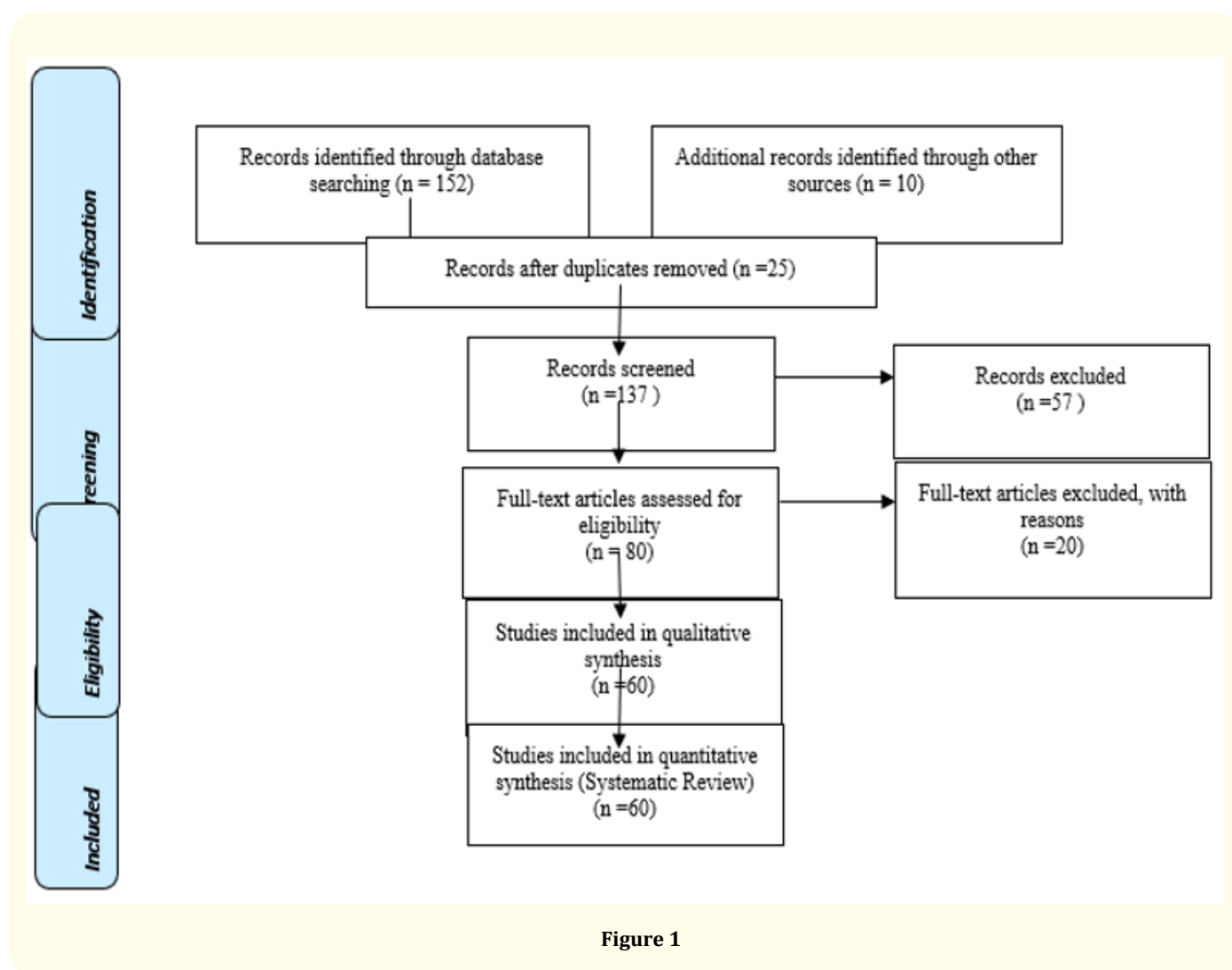


Figure 1

Literature Review

Tegument system

Those responsible for skin formation are the epidermis, the outer layers, thin and sensitive receptors. This layer has no blood vessels, nourishing through the dermis, located under the epidermis. The dermis contains connective tissue, sebaceous glands, and some hair follicles. The sebaceous glands are interconnected to the hair follicles and an oily substance is produced called sebum, which reaches the surface of the skin after the emptying of the sebaceous gland through an opening in the hair follicle. Sebum stimulates cells in the inner wall of the hair follicle, where they break off more quickly and clump together to form a buffer on the surface of the skin.

The association of sebum and cells of the inner wall of the hair follicle leads to bacterial growth within the follicle. These growing bacteria can produce substances that cause follicular wall rupture, and then sebum, bacteria, and scaly cells from the follicle wall spill into the skin causing erythema, edema, and pus. The sebaceous glands are present in regions where it is common to find acne: face, back, and thorax [1].

The subcutaneous tissue is located under the dermis, contains fats and sweat glands and the other hair follicles. In the integumentary system, there may be clinical manifestations, which include the inflammatory reaction and the formation of lesions on the skin. The inflammatory reaction is a beneficial reaction, but it presents discomfort at the site. Irritation changes the structure of the epidermis, with a resulting increase in immunoglobulin E activity.

Other classic signs of inflammatory skin responses are erythema, edema, and heat caused by bioamines released from mast cell granules and tissue basophils. Primary skin lesions appear on the previously healthy skin in response to external diseases or irritation, and secondary skin lesions occur as a result of rupture, mechanical irritation, extension, invasion or normal or abnormal scarring of primary lesions [2].

Pathophysiology of Acne

Acne is a chronic acne that is classified clinically in four levels, according to Ribas; Oliveira [3] are:

- o Degree I (Figure 1): the mildest, noninflammatory form, characterized by the presence of closed comedones that present a whitish or yellowish cutaneous elevation and open comedones that present small elevation, is hard and of black color, due to the oxidation of the tallow;

- o Degree II: inflammatory acne, in which, comedones are associated with papules which are painful inflammation that develops from the closed comedo and pustules which is the evolution of the papule which presents pruritus and pain purulent content;
- o Degree III: nodule-cystic acne, when more lumpy nodules are added;
- o Degree IV acne conglobata, in which there is the formation of abscesses and fistulas.

Acne usually appears in adolescents, it is specific to the pilosebaceous follicle and, in its pathophysiology, interfere with several factors [4].

In pathophysiology there may be individual genetic predisposition and other factors involved in the development of acne: sebaceous gland hyperplasia and sebum production in response to increased adrenal androgen levels at puberty, where the sebaceous glands may have more receptors androgen receptors, or the present receptors present increased sensitivity to these hormones; hyperkeratinization of the pilosebaceous follicle with obstruction and formation of micro-comedo as a result of the mixture of sebum and desquamated epithelium; proliferation of *Propionibacterium acnes*, an anaerobic microorganism that uses the lipids present in the sebaceous secretion as nutrients. Such microorganisms release lipases that hydrolyze the tallow triglycerides, releasing fatty acids that are irritating to the wall of the follicle; immune response with the production of numerous inflammatory mediators released within and within the follicle. Installed inflammation may be exacerbated by rupture of the follicle, with subsequent escape of the contents of the inflamed gland to the dermis. In these cases, nodules, cysts, and fistulas may form, lesions responsible for nodular-cystic acne and conglobata, which may lead to the formation of persistent scars [1].

Acne in the diagnosis can be classified as: mild, where the number of lesions is less than ten and the form is usually characterized by papules/pustules and absence of nodules; moderate, where the amount varies between ten and twenty lesions, being papules/pustules with some nodules; or severe, where there are lesions greater than twenty and the form is of papules/pustules and many nodules [5].

After the diagnosis, which is different for each patient, a treatment is proposed to minimize and treat the lesions [6]. As for the treatment of acne, it aims to avoid the most relevant complications of the disease, for example, physical scars and psychosocial sequelae, which may persist after the disappearance of the lesions [3].

Microneedling

Microneedling descends from Acupuncture. In France in the 1960s, the first findings of the technique considered Nappage, which consisted of small incisions in the skin for the administration of drugs, whose objective was facial rejuvenation appeared. In the year 1990, the technique of Microneedling appeared in Germany. In 1995, Orentreich advocated the subcision technique with needles for treatment of perioral wrinkles. Already in 2006, Fernandes elaborated the collagen induction technique (TIC), which consisted of a steel needle roller aiming to improve scars and fine wrinkles [7].

Microaggregation leads to the production of collagen in the skin from a mechanical stimulus by means of a roller composed of microneedles. According to Matos [8] "from the lesion caused by the needles, an inflammatory process of healing begins that has three phases: injury, healing and maturation".

In the first phase of injury there is release of platelets and neutrophils responsible for the release of growth factors with action on keratinocytes and fibroblasts [9].

In the second healing phase, neutrophils are replaced by monocytes, and angiogenesis, epithelization and proliferation of fibroblasts, followed by the production of collagen type III, elastin, glycosaminoglycans and proteoglycans occurs. In parallel, the fibroblast growth factor is secreted by the monocytes. Approximately five days after the injury the fibronectin matrix is formed, allowing the deposition of collagen just below the basal layer of the epidermis. In the third phase or maturation, type III collagen, which is predominant in the early stage of the healing process, is slowly replaced by type I collagen, which lasts longer, lasting for five to seven years.

In the third phase, in order for all inflammatory processes to be established, the trauma caused by the needle must reach a depth of 1 to 3 mm in the skin, preserving the epidermis, which has only been perforated and not removed. Hundreds of microleads are created, resulting in blood collection columns in the dermis, accompanied by edema of the treated area and virtually immediate hemostasis. The intensity of these reactions is proportional to the

length of the needle used in the procedure. Considering the depth of 1 mm, the hematoma will be imperceptible, unlike that of 3 mm is visible and may persist for hours. However, through Figure 07 it is possible to observe that the needle does not fully penetrate the rolling process [9].

It is estimated that a needle of 3.0 mm in length penetrates only 50 to 70.0% in its extension, that is, from 1.5 to 2.0 mm. Therefore, when the needle length is 1.0 mm the damage would be limited to the superficial dermis, and consequently, the inflammatory response would be much more limited than that caused by a longer needle [9].

This type of treatment has very positive results since it is a less invasive and ablative procedure, microneedle has been widely used in acne scars because it breaks the old collagen fibers and induces the renewal and growth of a new collagen below the epidermis [7].

Another issue that is very expressive is related to not changing the routine of the client/patient, because, generally, there is no desquamation, there is stimulation of the production of collagen, consequently a thickening of the skin.

Unlike other methods, such as chemical peels and lasers that thin the epidermis. It facilitates the permeation of cosmetics that stimulate scar regeneration, healing time is shorter and with low side effects, has no degree restriction and has a lower cost than the other techniques cited [8].

Technical Characteristics

Among the technical characteristics for this research was chosen the roller or dermaroller which is usually composed of a small roller-roller composed of a quantity of fine needles that, depending on the type of purpose of use, can vary from 190 to 1080 needles of 0.20 mm and 3.0 mm in length and ranging from 0.1 mm to 0.12 mm in diameter at the maximum penetration point (CACHAFEIRO, 2015).

This equipment gives the professional the possibility of regulating exfoliation levels. The abrasion produced in the tissues is conditioned by the number of microcrystals blasted and by the pressure used, for the projection, aspiration and also by the number of passages over the treated area [10].

It is necessary that the procedure is performed by a trained professional with specific training, that there is an evaluation to determine the functionality of the technique and the possibility of treatment for each individual.

The appearance time of the petechiae pattern varies with the thickness of the treated skin and the length of the needle chosen. Therefore, the thinner, looser skin, commonly photoaged, will have a uniform pattern of petechiae earlier than thick, fibrous skin, seen in patients with acne scars, for example. Therefore, the choice of needle length depends on the type of skin to be treated and on the final objective of the procedure [9].

Contraindications

Although the treatment seems simple and easy, it is necessary to respect the anatomy of the skin, in order to guarantee sterility and to know the handling of the instrument, because it is an invasive treatment, it is possible that lesions and skin infections occur (CACHAFEIRO, 2015). Table 1 below demonstrates the main contraindications.

Open wounds	There may be a fragment of the framework.
Burned skin/sold bronze	There may be hypersensitivity, and there is a risk of hypercromy in the virtue of the increase in melanogenesis.
Herpes and acne activas	Injury may be increased under the dissemination of the causing agent
Any skin acute inflammation or inflammation	Injured skin sensitivity injured.
History of wicker healing/diabetes	Effects of miscellaneous injury.
Collagen diseases (cushing syndrome)	Generation of collagen of bad quality or disability may be generated.
Areas with neoplasia	Refer to tumor. Independent if benigno or maligno can bring serious problems.
Allergy	Metal or cosmetic.
Use of anticoagulants	There are risks of uninterrupted bleeding.
Pregnancy	Without use of cosmetics/medicines is safe, but when choice is needed to use chemicals, the choice of the substance to be used must be made with a high criterion.
Use of roacutan (isotretinoin)	Recovery from skin drilling can generate hypertrophic scars and cause skin deformations.
Use of helmets	Generated attraction on the site.
Avoid contact with pets	After the procedure, why cause allergy.

Table 1: Contraindications (CACHAFEIRO (2015)).

Microneedling benefits for acne treatment

The treatment stimulates collagen without promoting an ablative effect on the skin. Healing occurs quickly and the chance of side effects is minimal when compared to other ablative techniques since it leaves the skin more dense and resistant. In addition, it is a low-cost technique compared to other high-tech treatments [7].

Fabbrocini *et al.* (2014) apud Lima; Souza; Grignoli (2015) performed an isolated microneedle treatment on acne scars of 60 people between grades I to IV. They were divided into groups A (grades I and II), B (grades III to IV) and underwent three micro-aggregation sessions with monthly intervals. The researchers concluded that the technique works positively in all grades without the risk of depigmentation.

In another study, Dogra, Yadav, and Sarangal (2014) apud Lima; Souza; Grignoli [7] performed a microneedle procedure on acne scars from Asian skins. Thirty-six individuals participated, of which 26 were female and 10 were male, with monthly intervals at each session. After five sessions, a significant improvement was observed in the cicatricial lesions of acne.

Kalil, *et al.* [11] also performed a study to evaluate the improvement of acne scars of the distensible type on the face after treatment with the microneedle technique, followed by the topical application of a gel containing growth factors. For this, 10 patients with acne scars, who met the inclusion criteria, were selected. All of them underwent three microwelling sessions, with intervals of one to two months, with a one-year follow-up.

The objective of the use of the applied mascara actives after microneedle was to increase hydration, stimulate fibroblasts, improve cicatrization and provoke anti-inflammatory action. In the postoperative period, all patients were able to return to their routines the day after the procedure. Immediately after treatment, the skin showed edema and erythema, which disappear rapidly. There was no complaint of postoperative pain. Physical sunscreen SPF 30 was provided for application on subsequent days [11].

Through Figure 1 it is possible to observe the before and after the treatment that presents a discrete improvement of the distensible atrophic scars of the eight patients that were part of the research, but the atrophic scar of the type ice picks (no distensible) did not show improvement with the procedure [11].

In the studies of Santana, *et al.* [12] with six patients, five females and one male, aged 21 to 33 years, whose degree in four patients was IV, and in two was III; four of the six patients used oral isotretinoin before the procedure, with a dose between 120 and 150 mg/kg. They were submitted to microneedling for at least six months after the end of the medication. None of the patients presented comorbidities or used systemic medication. At physical examination, they presented distensible and non-distensible acne scars distributed mainly in the malar and temporal regions, including some ice picks. No inflammatory lesions at the time of the procedure.

The patients who participated in this study reported a subjective improvement of the lesions, also observed by the medical team. The best result was observed for distensible scars, with little difference in the appearance of scars like ice picks. No patient evolved with infectious interurrences. The only complication was postinflammatory hyperchromia present in two patients. Bleaching creams with hydroquinone, corticoid and retinoic acid association were used, with progressive improvement [12].

As it was possible to observe through the studies presented here the results were satisfactory, presenting moderate effect on the repair of atrophic acne scars, harmonization of the skin with reduction of dilated osteoses, increase of luminosity and tissue turgor.

Microagglutination is one of the most accepted hypotheses because it creates a large number of tiny holes through the epidermis to the papillary dermis. These wounds create a confluent zone of the superficial lesion, initiating the normal process of healing wounds with the release of growth factors [7].

Stimulation of migration and proliferation of fibroblasts resulted in collagen deposition, which occurs uninterrupted for months after injury. The needles above 1.5 mm reach the dermis and trigger with bleeding, an inflammatory stimulus that results in the production of collagen [9].

O tratamento de cicatriz atrófica de acne promove discreto efeito nas cicatrizes de acne e a melhora geral da textura da pele [11].

Como fator limitante, encontram-se relacionadas ao profissional que irá executar o trabalho, uma vez que dependendo da profundidade atingida com a agulha, é exigido um tempo maior de recuperação; portanto, é necessária uma avaliação cautelosa do profissional a fim de se evitarem falsas expectativas em relação ao resultado final [7,13-15].

Final considerations

The literature showed that acne is a chronic dermatosis that is classified clinically in four levels: degrees I, II, III, IV. As a form of treatment, in this study, it was suggested the micro needling that is a therapy that leads to the production of collagen in the skin from a mechanical stimulus, through a roller composed of microneedles. In addition to the literature review that dealt with the conceptual issues, we also presented studies by authors that demonstrated the efficacy of the treatment. Thus, it was possible to conclude that microagglutination results in very positive results since it is a less invasive and ablative procedure. It is further added that it has been widely used in acne scars because it breaks down the old collagen fibers and induces the renewal and growth of a new collagen below the epidermis.

Conflict of Interest

There is no conflict of interest between authors.

Bibliography

1. Ribeiro Cláudio. "Cosmetologia Aplicada a Dermoestética". São Paulo: Pharmabooks (2006).
2. Steiner Denise. "Acne vulgar". RBM Revista Brasileira de Medicina 60 (2003): 490-495.
3. Ribas Jonas, *et al.* "Acne Vulgar e Bem-Estar em Acadêmicos de Medicina". *Anais Brasileiros de Dermatologia* 83 (2008).
4. Costa A., *et al.* "Acne vulgar: Estudo Piloto de Avaliação do uso oral de Ácidos Graxos Essências por meio de Análises Clínica, Digital e Histopatológica". *Anais Brasileiros de Dermatologia* 82 (2007).
5. Alchorne MMA and Pimentel DRN. Acne. *Revista Brasileira de Medicina* 60 (2003): 165-172.
6. Sampaio Sebastião de Almeida Prado, *et al.* "Experiência de 65 anos no Tratamento da Acne e de 26 Anos com Isotretinoína Oral". *Anais brasileiros de Dermatologia* 83 (2008).
7. Lima Angélica Aparecida de, *et al.* "Os benefícios do microagulhamento no tratamento das disfunções estéticas". *Revista Científica da FHO. Uniararas* 3 (2015).
8. Matos Marina Cruz de Oliveira. "O uso do microagulhamento no tratamento estético de cicatriz de acne". Artigo apresentado ao curso de Bacharelado em Estética do IBMR – Laureate International Universities. Rio de Janeiro (2014).

9. Lima Emerson Vasconcelos de Andrade, *et al.* "Microagulhamento: estudo experimental e classificação da injúria provocada". *Surgical And Cosmetic Dermatology* 5.2 (2013): 1104.
10. Torres Carla Alves, *et al.* "Os benefícios do microagulhamento no rejuvenescimento facial". V Encontro Científico e Simpósio de Educação Unisalesiano (2015).
11. Kalil CLPV, *et al.* "Tratamento das cicatrizes de acne com a técnica de microagulhamento e *drug delivery*". *Surgical And Cosmetic Dermatology* 7.2 (2015): 144-148.
12. Santana Candida Naira Lima e Lima, *et al.* "Microagulhamento no tratamento de cicatrizes atróficas de acne: série de casos". *Surgical And Cosmetic Dermatology* 8 (2016): S63-65.
13. Brighenti JA. Publicado em (2016).
14. Trindade Luana, *et al.* "Análise de eficácia do microagulhamento para cicatriz de acne". Artigo apresentado para o curso de Tecnologia em Estética e Cosmética da Universidade Tuiuti do Paraná. Curitiba, (2016).
15. Viana Aleksana. "Saiba qual é o melhor tratamento para cada tipo de acne". (2017).

Volume 3 Issue 1 January 2019

© All rights are reserved by Idiberto José Zotarelli Filho, *et al.*