

Traumatic Lesions of Lip and Gingiva- Appearance and Management - A Clinical Review

Joshi Bharat^{1*} and Bhandari Varun²

¹Senior lecturer, Department of Periodontology, Swami Devi Dyal Dental College and Hospital, Haryana, India

²PG Student, Department of Periodontology, Swami Devi Dyal Dental College and Hospital, Haryana, India

***Corresponding Author:** Joshi Bharat, Senior lecturer, Department of Periodontology, Swami Devi Dyal Dental College and Hospital, Golpura, Barwala, Haryana, India.

Received: August 31, 2018; **Published:** November 22, 2018

Abstract

Injuries to lip and gingiva are commonly observed as a result of either trauma or due to some irritation which may be local or systemic. These injuries often result in lot of discomfort and pain to individuals thereby causing mastication difficulties and unpleasant looks. The appearance of these injury based lesions may be either sessile or pedunculated depending upon nature and involvement. These lesions affect younger and middle age group and usually do not undergo malignant transformation. The effect of these lesions are oral functional disability and systemic disturbances. Irritational injuries to lip and gingiva include a variety of lesions namely mucocele, fibroma, pyogenic granuloma and peripheral ossifying fibroma (POF). Clinical management of these lesions involve variety of procedures like surgical excision, electrocautery or lasers. In this paper, a clinical review depicting clinical features and management of major irritational lesions of lip and gingiva has been presented to update the knowledge of fresh clinicians for diagnosis and treatment.

Keywords: Trauma; Swelling; Scalpel; Excision; Granuloma

Introduction

Irritational injuries can sometimes pose a greater challenge to an individual. They can cause both esthetic and functional difficulties. Trauma or presence of chronic irritation can result in variety of lesions ranging from mucocele to pyogenic granuloma [1,10]. However, the management of these lesions depends upon various factors like site, amount of vascularity and progression [14]. This paper has tried to depict the clinical features and management of some of the common irritational lesions of lips and gingiva.

Mucocele

Mucocele (Figure 1) is a non-cancerous slow growing bluish or translucent swelling which can occur as a result of disruption or blockage of a minor salivary gland duct followed by extravasation and collection of mucins in the connective tissue [1]. A local trauma is the most common etiology, but certain cases present with an unknown etiology. It occurs most commonly in the inner aspect of lower lip but can also occur in buccal mucosa, tongue and floor of the mouth, without predilection for gender.

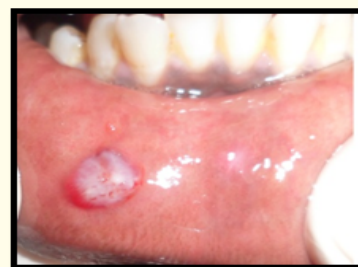

Figure 1: Mucocele.

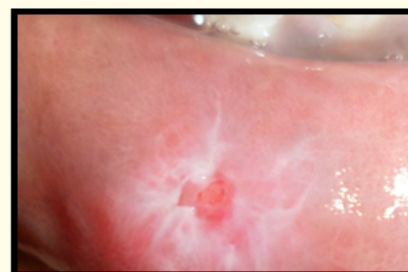

Figure 2: Post-operative.

Fibromas

Fibromas (Figure 3) are slow growing asymptomatic benign tumor of connective tissue origin occurring most frequently in buccal mucosa with predilection for occurrence in females. Histologically it is characterized by proliferation of fibroblast and abundant deposition of collagen fibers [1]. Oral fibromas usually result from chronic irritation such as cheek or lip biting, and chronic irritation by ill-fitting dentures [2]. Oral fibromas are mostly firm and nodular but can be soft and vascular. It is lighter in color than the surrounding tissues because of reduced vascularity [3]. It has another variant called as peripheral ossifying fibromas.

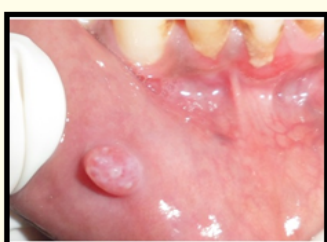

Figure 3: Fibroma.

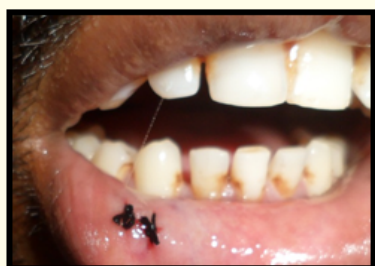

Figure 4: Post-operative.

Peripheral ossifying fibroma

Peripheral ossifying fibroma (POF) is a rare condition which may arise due to trauma or chronic irritation from plaque, calculus or dental appliances. It occurs most commonly in anterior maxilla, occurring exclusively in gingiva with predilection for occurrence in females [4]. Clinically, (figure 5) it appears as a slow growing well defined non-neoplastic enlargement with a sessile or pedunculated base having either similar color to gingiva or may present a slightly reddish appearance. Size of the lesion mostly vary between 0.4 to 4 cm, but lesions can sometime reach up to 9 mm [7]. POF occurs exclusively on gingiva. Histologically there is excessive prolif-

eration of mature fibrous connective tissue. Radiographic appearance includes presence of calcifications scattered in the central area of the lesion. It usually does not involve the underlying bone, but superficial erosion may be seen in some cases [6]. The condition is believed to be arising from periodontal ligament. Diagnosis is confirmed by histopathological examination (Figure 7).

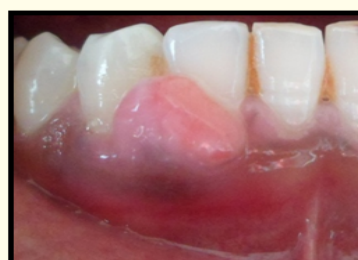

Figure 5: Peripheral ossifying Fibroma.

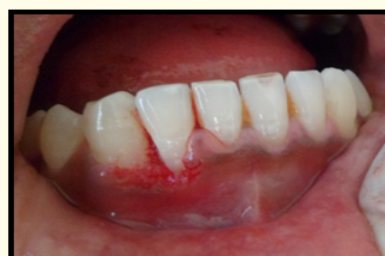

Figure 6: Post-operative.

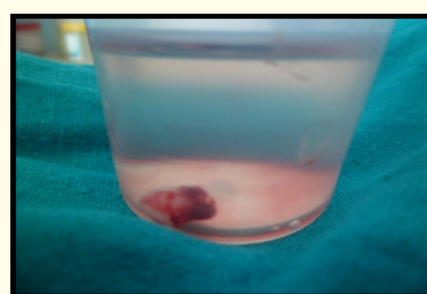


Figure 7: Specimen for histopathological examination.

Pyogenic granuloma

Pyogenic granuloma (Figure 8) is a non-neoplastic inflammatory hyperplastic growth of the connective tissue resulting from an exaggerated response towards localized lesion or an irritation like calculus or defective restorations, traumatic injury or hormonal

factos.5 Histologically it shows great vascular proliferation lined by thick endothelial cells with epithelium ranging from being hyperplastic to thin or even ulcerated.

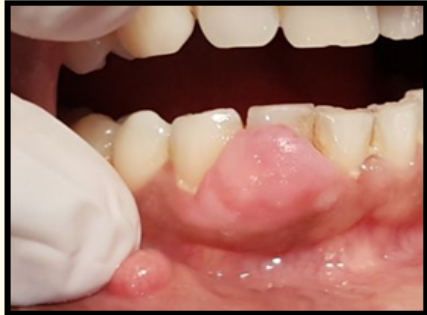

Figure 8: Pyogenic granuloma.

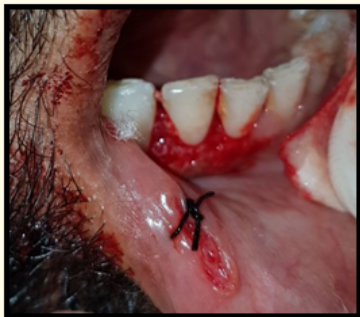

Figure 9: Post-operative.

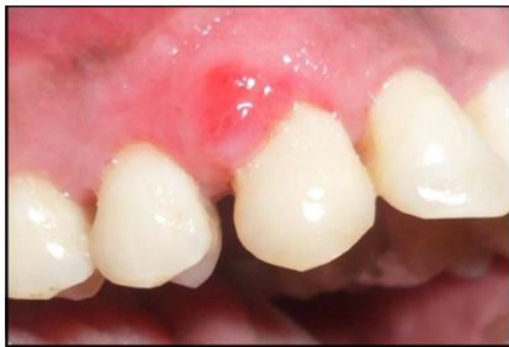

Figure 10: Pyogenic Granuloma (case-2).

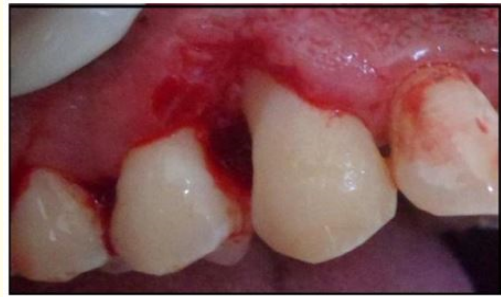

Figure 11: Post-operative.

Discussion

Enlargements in the oral cavity whether it is of gingiva, lip, buccal mucosa or any other region present as a diagnostic challenge. A correct diagnosis is paramount as different lesions can have different treatment modalities. Differential diagnosis plays an important role for further treatment planning. Lesions namely lipoma, fibroma, pyogenic granuloma and peripheral giant cell granuloma offer a significant challenge for a clinician to manage and prevent recurrence of oral lesions [11-13]. However, final diagnosis should be made on the basis of clinical, histopathological and radiographical findings [16].

Lipoma has a typical appearance of yellowish-orange protuberant growth with preference at buccal mucosa while hemangioma has preference on the lip and tongue with red-blue tinge [12,13]. Peripheral giant cell granuloma has bony involvement with gingival preference while peripheral ossifying fibroma may occur on palate also and is relatively less common. However, if not surgically removed in early stages of the condition, it can lead to extensive bone loss. Most common site for occurrence for pyogenic granuloma is gingiva followed by lips, tongue, palate and buccal mucosa [11]. The lesion present as an exophytic growth with a smooth and shiny surface having numerous hemorrhagic papules or may be ulcerated and covered by a yellow fibrinous membrane [12]. Radiographic changes are not seen but in long standing cases of pyogenic granuloma localized alveolar bone resorption has been reported [13]. Treatment involves surgical excision and removal of local irritants and scaling and root planning of the adjacent teeth. Mucocele and fibroma can pose a diagnostic challenge as these may be misdiagnosed as other pathologies like fibrous hyperplasia, focal papilloma, hemangioma, lymphangioma, or lipoma. Diagnosis is confirmed by histopathological examination and correlation with clinical presentation [9]. Etiology of mucocele is trauma while fi-

broma is associated with chronic irritation [11]. In contrast a fibroma may have smooth or a irregular surface and most of the lesion appear hard on palpation either with a sessile or a pedunculated base [15].

Treatment options include marsupialisation, laser ablation and excision by scalpel or electrosurgery. (Figure 2,4,6,9). Excision by laser have an advantage of minimal post-operative pain, no, minimal bleeding, need of suturing the site and excellent healing at one week [8]. However, chances of recurrence are more with lasers than electrocautery or scalpel [13].

Conclusion

This paper gives an overview and summarizes the common irritational lesions of Lip and Gingiva. Diverse array of causative factors can be identified. Commonly encountered lesions are generally easier to diagnose therefore can be easily managed by elimination of the causative factor and enhancing the healing of the lesion. A biopsy should be done to confirm the diagnosis. Thorough clinical examination and attention to all possible aspects of causative factors are mandatory for complete resolution of the lesion.

Bibliography

1. Valério RA., et al. "Mucocele and Fibroma: Treatment and Clinical Features for Differential Diagnosis". *Brazilian Dental Journal* 24.5 (2013): 537-541.
2. Younwook Jeong., et al. "Irritation Fibroma Associated with Ectopic Eruption of the Maxillary Incisor". *Journal of The Korean Academy of Pediatric Dentistry* 43 (2016).
3. Verghese R., et al. "Fibroma - A misnomer: Case Series". *NUJHS* 4. (2015).
4. Amberkar VS., et al. "Peripheral ossifying fibroma: Revisited". *International Journal of Oral Health Sciences* 7 (2017): 35-40
5. Rosa CG., et al. "Oral pyogenic granuloma diagnosis and treatment: a series of cases". *Revista Odontológica Mexicana* 21 4 (2017): 253-261.
6. Kendrick F and Waggoner WF. "Managing a peripheral ossifying fibroma". *ASDC Journal of Dental Child* 63 (1996): 135-138.
7. Poon CK., et al. "Giant peripheral ossifying fibroma of the maxilla: Report of a case". *Journal of Oral and Maxillofacial Surgery* 53 (1995): 695-698.
8. Alam T., et al. "Surgical diode laser excision for peripheral cementoOssifying fibroma: A case report and literature review". *The Journal of Oral Laser Applications* 8 (2008): 434-9.
9. Regezi., et al. "Oral Pathology: Clinical Pathologic Correlations. 5th ed. Philadelphia: Saunders Elsevier (2008).
10. Bahadure RN., et al. "Conventional surgical treatment of oral mucocele: a series of 23 cases". *European Journal of Paediatric Dentistry* 13 (2012):143-146.
11. Avelar RL., et al. "Oral pyogenic granuloma: A epidemiologic study of 191 cases". *RGO* 56 (2008): 131-135.
12. Hosseini FH., et al. "Immunohistochemical analysis of estrogen and progesterone receptor expression in gingival lesions". *Iranian Journal of Public Health* 35 (2006): 38-41.
13. Angelopoulos AP. "Pyogenic granuloma of the oral cavity: Statistical analysis of its clinical features". *Journal of Oral and Maxillofacial Surgery* 29 (1971): 840-847.
14. Nishant., et al. "Pyogenic Granuloma in Deciduous Dentition of A 4-Year-Old Pediatric Patient: A Rare Case Report". *Indian Journal of Dental Sciences* 5 (2014): 49-51.
15. Mortazavi H., et al. "Peripheral Exophytic Oral Lesions: A Clinical Decision Tree". *International Journal of Dentistry* (2017).
16. Rajendran R and Sivapathasundharam B. "Benign and malignant tumours of the oral cavity". Shafer's textbook of Oral Pathology 7 edition Missouri. Elsevier: (2012).

Volume 2 Issue 12 December 2018

© All rights are reserved by Joshi Bharat and Bhandari Varun.