



Extracapsular Dissection of Pleomorphic Adenoma of Hard Palate - An Unconventional Approach with Promising Result

Abdus Sami¹, GS Hashmi², Md Kalim Ansari^{3*}, Tabishur Rahman⁴ and Ravirajsinh Aniruddhsinh Gohil¹

¹Junior Resident, Department of Oral and Maxillofacial Surgery, Dr. Z.A Dental College, AMU, Aligarh, UP, India

²Associate Professor, Department of Oral and Maxillofacial Surgery, Dr. Z.A Dental College, AMU, Aligarh, UP, India

³Assistant Professor, Department of Oral and Maxillofacial Surgery, Dr. Z.A Dental College, AMU, Aligarh, UP, India

⁴Senior Resident, Department of Oral and Maxillofacial Surgery, Dr. Z.A Dental College, AMU, Aligarh, UP, India

***Corresponding Author:** Md Kalim Ansari, Assistant professor, Department of Oral and Maxillofacial Surgery, Dr. Z.A Dental College, AMU, Aligarh, UP, India.

Received: August 3, 2018; **Published:** November 08, 2018

Abstract

Minor salivary gland tumors are relatively rare but have a higher chance of malignancy than tumors of major salivary gland. The palate appears to be the most commonly involved site. The most frequent benign tumor is the pleomorphic adenoma. The treatment of such lesion is complete excision along with overlying mucosa. We report a case of a pleomorphic adenoma of palatal minor salivary glands in a 14yr old female patient in which the lesion was successfully treated by Extracapsular dissection (ECD) as an alternative to conventional excision. The postoperative final histopathology report came to be pleomorphic adenoma and the healing was uneventful.

Keywords: Extracapsular Dissection; Pleomorphic Adenoma

Introduction

Salivary gland in humans includes three pairs of major glands; the parotid, submandibular, and sublingual glands and about 600-1000 minor salivary glands located mainly in the submucosa of oral cavity except the gingiva and anterior hard palate [1].

Most studies have shown minor salivary gland tumors are more common in 4th-6th decade of life in females. Among the benign tumors of oral cavity, pleomorphic adenoma (PA) is the most common in both major and minor salivary glands [2-6]. The most common intraoral site for PA affecting minor salivary gland is palate [3-6]. About 40% - 52% of all palatal minor salivary gland tumors are pleomorphic adenoma [2-4]. The next most common sites are the lips (10.1%) and the cheeks (5.5%). They are also occasionally found at other sites such as the tongue, retromolar fossa, pharynx or tonsil. Tumors develop in an insidious fashion, growing slowly over a long period of time without causing any other symptom.

Pain is extremely uncommon and, if present, usually heralds malignant change. The tumor is readily palpable, bosselated surface and bluish areas maybe discernable through the mucosa. In addition, these tumors, like any others in the mouth and particularly those in the palate, can become ulcerated by friction or trauma. The differential diagnosis includes torus, palatal abscess, odontogenic and non-odontogenic cyst, fibroma, lipoma, neurofibroma, neurilemmoma, condyloma acuminata, oral papilloma and squamous cell carcinoma. Malignancy presents with erosion of the overlying mucosa, bleeding or pain. The benign growth-like torus palatines will be bony hard on palpation with an irregular appearance.

The treatment of choice for pleomorphic adenoma in minor salivary gland is wide local excision with the removal of periosteum or bone if they are involved. We report a case of pleomorphic adenoma of hard palate in which we did Extracapsular dissection as an alternative to conventional excision.

Case Report

A 14 years old female patient came to our dental outpatient department with complain of swelling over the right side of palate. Clinically, a solitary swelling on the right side of the posterior palate was seen abutting the marginal gingiva in relation to premolars and molars anterior-posteriorly and lateral to the midpalate raphe. The size of lesion was around 4 x 2 cm. The swelling was oval in shape having well defined borders. The overlying mucosa was normal. The swelling was slight tender, soft and compressible. There was no previous history of dental pain and adjacent teeth were vital without caries (Figure 1).

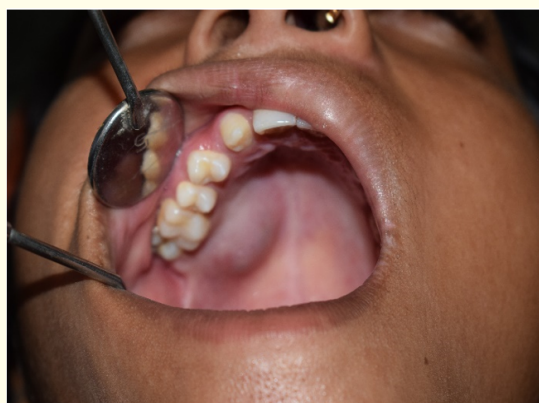

Figure 1: Preoperative Clinical view.

Contrast enhanced computed tomography (CECT) revealed a well-defined enhancing soft tissue lesion of right side palate with cupped out resorption of underlying bone due to pressure (Figure 2). Fine needle aspiration cytology (FNAC) confirmed the lesion to be Pleomorphic Adenoma.

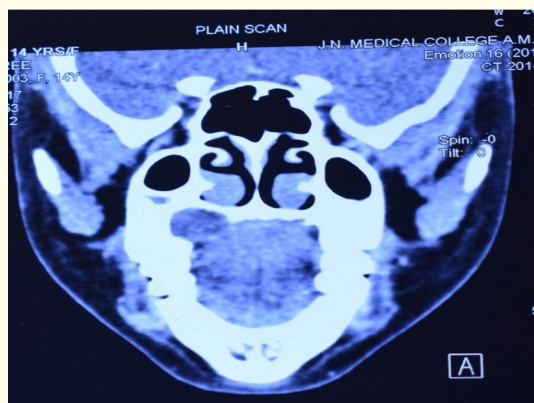


Figure 2: Coronal image of CT Showing Cupped out resorption of underlying bone.

Excisional biopsy was planned under general anesthesia. The mucosal incision as described by Subramaniam, *et al.* [7] was given and submucosal flap was raised with the help of sharp tenotomy scissor (Figure 3). After that tumor was removed in toto and mucosal flap was closed with interrupted 4-0 silk suture and the patient were extubated. Histopathology of the biopsy specimen confirmed the lesion to be pleomorphic adenoma. The patient was followed up for 6 months with excellent healing and no clinically evident signs of recurrence (Figure 4).

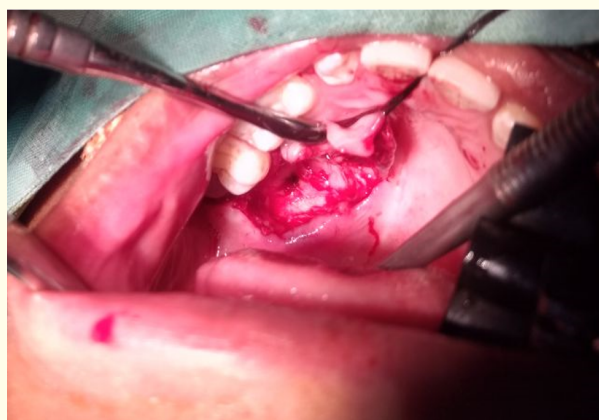


Figure 3: Intraoperative View.

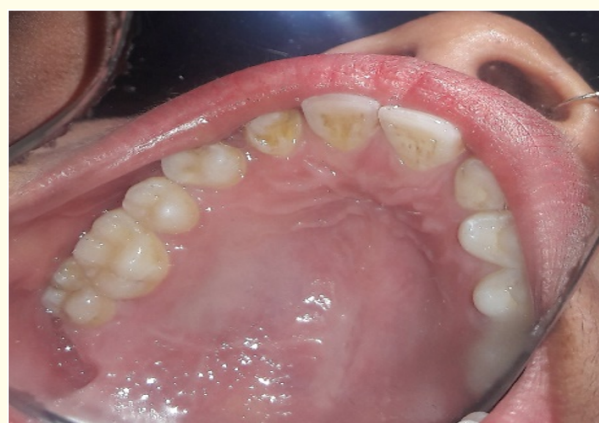

Figure 4: Postoperative view.

Discussion

Pleomorphic adenoma is the most common salivary gland tumor and accounts for about 60% of all salivary neoplasms [8]. In the minor salivary glands, the incidence of pleomorphic adenoma ranges from 33% - 70% of all tumors with highest occurrence in palatal minor glands [9].

The differential diagnosis includes torus, palatal abscess, odontogenic and non-odontogenic cyst, fibroma, lipoma, neurofibroma, neurilemmoma, condyloma acuminata, oral papilloma and squamous cell carcinoma [10]. Malignancy presents with erosion of the overlying mucosa, bleeding or pain. The benign growth-like torus palatines will be bony hard on palpation with an irregular appearance [10]. The soft tissue benign tumor can be differentiated through cytological/ histopathological investigation like FNAC or incisional biopsy. CT is helpful in determining the extension of the lesion.

Histopathologic ally, the sections show complex morphology with epithelial and myoepithelial elements arranged in variety of patterns and embedded in a mucopolysaccharide stroma [11]. The histopathological examination of our surgical specimen revealed small foci of clusters and trabeculae of epithelial cells with bland nuclear morphology in a chondromyxoid stroma. Foci of squamous metaplasia was also observed.

Surgical excision is the treatment of choice as the lesion has moderately high potential of malignant transformation [12]. Surgery of the lesions of palate require removal of overlying mucosa also along with the tumor. But the disadvantages of the conventional approach include longer healing time and healing by secondary intention with some palatal defect. Also, the chances of oronasal fistula formation are high in conventional excision approach. Recently extracapsular dissection of pleomorphic adenoma of soft palate has been reported by Subramaniam., *et al.* as an alternative to conventional excision particularly where there is a risk for oronasal fistula. However, this approach is suitable where there has been no previous incisional biopsy which could lead to mucosal scarring thus making the flap reflection difficult. In our case, excellent healing was observed without recurrence.

Conclusion

The extracapsular dissection of major salivary gland is a commonly used technique but its application in lesion of minor salivary gland is rare. The conventional treatment for palatal pleomorphic adenoma is excision of lesion with overlying mucosa. But the problem with this approach is longer healing time, healing by secondary intention with remaining defect and formation of oro-nasal fistula. To our knowledge only one such case has been reported in which extracapsular dissection was done. In our experience this ECD technique provide good functional result and comparable or may even better than conventional excision technique. However further studies with larger sample size and longer follow-up are needed to see the outcome of this approach as the chances of recurrence are high due to more conservative approach in ECD.

Bibliography

1. Nanci A. "Ten Cate's oral histology. Development, structure, and function". 8th edition. St Louis: Mosby Elsevier (2013): 253e77.
2. Pires FR., *et al.* "Intra-oral minor salivary gland tumors: a clinicopathological study of 546 cases". *Oral Oncology* 43 (2007): 463-470.
3. Yih WY., *et al.* "Intraoral minor salivary gland neoplasms: review of 213 cases". *International Journal of Oral and Maxillofacial Surgery* 63 (2005): 805-810.
4. Waldron CA., *et al.* "Tumors of the intraoral minor salivary glands: a demographic and histologic study of 426 cases". *Oral Surgery, Oral Medicine, Oral Pathology, and Oral Radiology* 66 (1988): 323-333.
5. Ellis GL., *et al.* "Surgical pathology of the salivary glands. Philadelphia: WB Saunders (1991).
6. Eveson JW., *et al.* "Salivary gland tumors. A review of 2410 cases with particular reference to histological type, site, age and sex distribution". *Journal of Pathology* 146 (1985): 51e8.
7. Shiva Subramaniam., *et al.* "Use of extracapsular dissection for benign, minor palatal tumours of the salivary gland – a technical note". *British Journal of Oral and Maxillofacial Surgery* (2016).
8. Andreasen S., *et al.* "Pleomorphic Adenoma of the Parotid Gland 1985-2010: A Danish Nationwide Study of Incidence, Recurrence Rate, and Malignant Transformation". *Head Neck* (2015): E1364-E1369.
9. Rivera-Bastidas., *et al.* "Intraoral Minor Salivary Gland Tumors: A Retrospective Study of 62 Cases in a Venezuelan Population". *Journal of Oral Pathology and Medicine* 25 (1996): 1-4.
10. Gupta M and Gupta M. "Pleomorphic Adenoma of the Hard Palate". *BMJ Case Report* (2013).
11. Chau MN and Radden BG. "A clinical pathological study of 53 intraoral pleomorphic adenoma". *International Journal of Oral and Maxillofacial Surgery* 18 (1989): 158-162.
12. Ethunandan M., *et al.* "A Typical Features in Pleomorphic Adenoma: A Clinicopathologic Study and Implications for Management". *International Journal of Oral and Maxillofacial Surgery* 35 (2006): 608-612.

Volume 2 Issue 12 December 2018

© All rights are reserved by Md Kalim Ansari., *et al.*