



Frontal Sinus Dimensions: An Aid in Gender Determination

Suzanne Tanya Nethan*, Shruti Sinha and Sunira Chandra

Department of Oral Medicine & Radiology, Saraswati Dental College, Lucknow, India

*Corresponding Author: Suzanne Tanya Nethan, Department of Oral Medicine & Radiology, Saraswati Dental College, Lucknow, India.

Received: September 14, 2018; Published: November 02, 2018

Abstract

Forensic science utilizes human anatomical structures like fingerprints, face, iris and retina for personal identification and gender determination. However, due to their unavailability in deceased individuals, human skeletal structures like teeth, thorax, and the paranasal sinuses are utilized for this purpose. Among the paranasal sinuses, the frontal sinuses are of particular significance, due to their inter-individual variability and uniqueness. Frontal sinuses dimensions in 100 digital PNS radiographs (of 50 males and females each) were assessed using the Kodak Digital Imaging software and statistical analysis. An individual was considered male, if the Discriminant Function Coefficient was more than 0 and female, if less. This technique proved to be 62% and 46% accurate in predicting females and males respectively. Thus, the frontal sinuses can be utilized in forensic odontology for gender determination, however keeping in mind the variations which may occur due to environmental or genetic factors.

Keywords: Forensic Science; Forensic Odontology; Frontal Sinus; Gender Determination; Sexual Dimorphism; Paranasal Sinus

Abbreviations

Ma: Milliampere; Kvp: Peak Kilovoltage; Di: Discriminant Function Coefficient; PNS: Paranasal Sinus

Introduction

Forensic odontology includes identification of the unknown (by teeth, jaws, craniofacial bones, paranasal sinuses), sex determination, age determination, bite marks investigations, personal abuse and dental jurisprudence. Gender determination is the current focus of forensic science and comprise of numerous methods for the same as cheiloscopy, palatoscopy, mandibular canine index, paranasal sinuses etc., among which Paranasal sinuses are gaining popularity. These are pneumatic cavities present in the human skull and among them, the frontal sinus is of particular significance in forensics because of its inter-individual variability/ uniqueness [1]. Several studies in the literature have mentioned the uniqueness of frontal sinus and has been successfully used in person identification. Despite of the correlation existing with gender differentiation using the morphology of frontal sinus, studies done on its use in determining sex is limited. Thus, the present study was carried out to determine the gender of individuals via the frontal sinus dimensions.

Materials and Methods

The study was conducted after obtaining ethical clearance and comprised of 50 males and 50 females, aged 20 years and above, as the frontal sinuses are said to attain maximum size by the age of 20 years [2]. However, individuals with history of internal sinus pathologies, orthodontic treatment or orthognathic surgery, trauma, or any surgery of the skull, history or clinical characteristics of endocrine disturbances, nutritional diseases or hereditary facial asymmetries, were excluded from the study group.

After obtaining written consents from the individuals (in their own language), which explained the nature of the study and the probable radiation hazards and protective measures to avoid the same, Digital Paranasal Sinus (PNS) view radiographs, the most preferred projection for paranasal sinus imaging, were taken using the Kodak 8000C Digital Panoramic and Cephalometric system at standard exposure parameters (of ten mA, 84 kvp, 0.63 seconds) (Figure 1).

The dimensions of the frontal sinuses were then determined with the help of the Kodak Digital Imaging software wherein first, the lower border (superior border of the orbit) of the frontal sinus/ baseline was standardized (A). The greatest height of each side (B

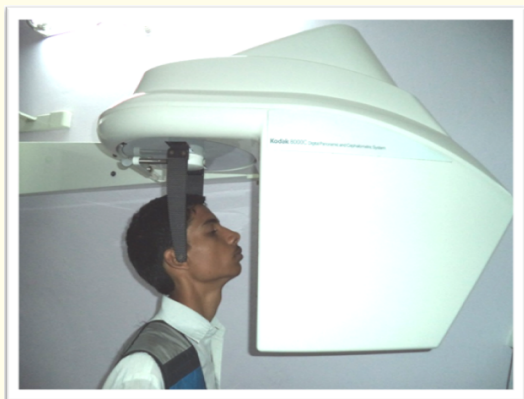

Figure 1: Digital PNS view radiographs, to record the frontal sinuses, were taken (with proper radiation protection measures) using the Kodak 8000C Digital Panoramic and Cephalometric system.

and C) was determined from the maximum distance between the base and upper lines of the frontal sinus, and the largest width (F and G) of the frontal sinus was determined from the maximum distance between the medial and lateral lines of the right and left side of the frontal sinus, as illustrated in Figure 2. The area of each of the frontal sinuses and the total area of both the sinuses was determined by calculating the products of the widths and heights of each. The linear measurements obtained from each radiograph were expressed in linear centimeters (cm) and the areas in square centimeters (cm²).

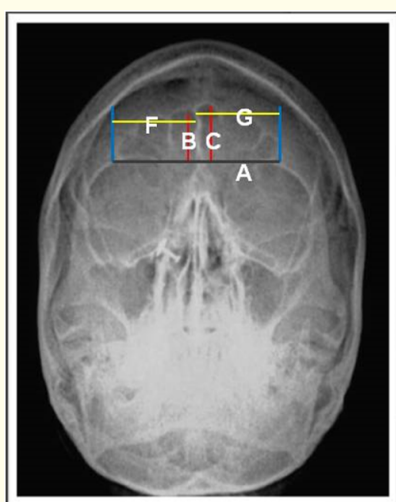


Figure 2: Digital PNS radiograph showing borders of the frontal sinus and identification of the measurements. A (baseline): The lower border of the frontal sinus. B, C: The greatest height of each side. F, G: The largest width of the frontal sinus.

The data thus obtained was subjected to statistical analysis i.e. the student’s t-test and the discriminant analysis, using the SPSS software version 21.

Results

In the present study, wherein the frontal sinuses of 100 individuals were analyzed, the descriptive statistic means, standard deviation and 'P' value using student's t-test for the samples were determined, as depicted in Table 1. No significant difference was observed in the mean value of all response variables between males and females (Figure 3).

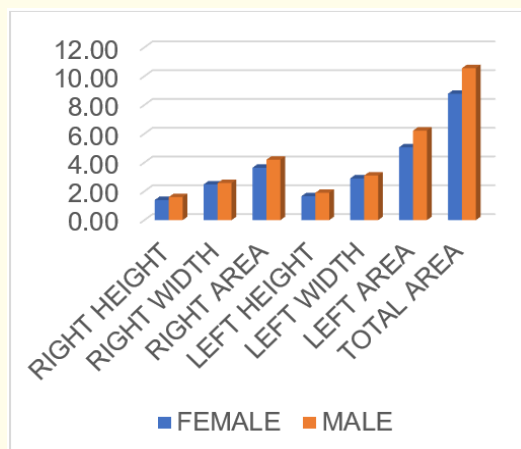


Figure 3: Student t-test to compare gender among the study group.

With the help of the Discriminant Analysis, a Discriminant Function Coefficient (Di) was obtained and the following equation was derived:

$$Di = -1.276 * (\text{constant}) + .994 * \text{RIGHT HEIGHT} - .150 * \text{RIGHT WIDTH} - .435 * \text{RIGHT AREA} - .113 * \text{LEFT HEIGHT} - .446 * \text{LEFT WIDTH} - .232 * \text{LEFT AREA} + .488 * \text{TOTAL AREA}.$$

On the basis of this equation it was assumed that if the value of Di was greater than 0, then the individual was a male and if less than 0, then female. In our study group, the value of Di was -.212 for females and .212 for males (Table 2). Also, excessive overlapping of these values was observed for both males and females (Figure 4).

In terms of accuracy, out of the 50 females, 31 were identified correctly (and 19 misidentified) as females and of the 50 males, only 23 were correctly identified, as the same. Hence, this technique was found to be 62% accurate in predicting females and 46% accurate in predicting males i.e. statistically insignificant as it does not lie in the range of 80-90% (Table 3).

| | Gender | N | Mean | Std. Deviation | T | Df | p VALUE |
|--------------|--------|----|-------|----------------|--------|--------|---------|
| Right height | Female | 50 | 1.4 | 0.53452 | -1.698 | 98 | 0.093 |
| | Male | 50 | 1.6 | 0.63888 | | | |
| Right width | Female | 50 | 2.48 | 0.7887 | -0.589 | 98 | 0.557 |
| | Male | 50 | 2.58 | 0.90554 | | | |
| Right area | Female | 50 | 3.64 | 1.9458 | -1.287 | 98 | 0.201 |
| | Male | 50 | 4.2 | 2.3819 | | | |
| Left height | Female | 50 | 1.66 | 0.62629 | -1.488 | 84.673 | 0.14 |
| | Male | 50 | 1.9 | 0.95298 | | | |
| Left width | Female | 50 | 2.9 | 0.88641 | -1.074 | 98 | 0.286 |
| | Male | 50 | 3.1 | 0.97416 | | | |
| Left area | Female | 50 | 5.06 | 2.89553 | -1.619 | 87.492 | 0.109 |
| | Male | 50 | 6.22 | 4.15658 | | | |
| Total area | Female | 50 | 8.78 | 3.85603 | -1.826 | 85.987 | 0.071 |
| | Male | 50 | 10.56 | 5.71128 | | | |
| Age | Female | 50 | 37.28 | 12.773 | -0.286 | 98 | 0.775 |
| | Male | 50 | 38.06 | 14.427 | | | |

Table 1: Means, standard deviation and P value (Student’s t-test) for two independent samples of right and left frontal sinus.

| Gender | Function |
|--|----------|
| | |
| Female | -.212 |
| Male | .212 |
| Unstandardized canonical discriminant functions evaluated at group means | |

Table 2: Discriminant Function Coefficient (Di) for the study group.

| | Gender | Predicted group membership | | Total |
|-------|--------|----------------------------|------|-------|
| | | Female | Male | |
| Count | Female | 31 | 19 | 50 |
| | Male | 27 | 23 | 50 |
| % | Female | 62.0 | 38.0 | 100.0 |
| | Male | 54.0 | 46.0 | 100.0 |

Table 3: Predicted gender pattern and accuracy.

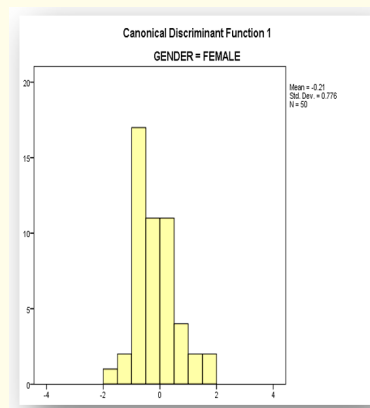
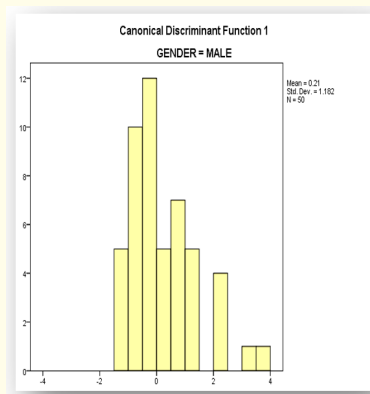


Figure 4: Discriminant Analysis to classify gender among the study group.

Discussion

One of the major problems faced by man in earlier days, was to establish the identity of an individual. Identification is the establishment of a person's individuality. Identification of humans is required for personal, social and legal reasons. It may also include cases of mass disasters and insurance claims. The traditional methods for personal identification include anthropometry, fingerprints, age determination and gender determination.

Among the four paranasal sinuses present in the human skull, the frontal sinuses are considered to be specific and unique and hence can be helpful in identifying a person positively. The frontal sinuses are paired sinuses/ two in number, divided by a median septum, which often deviates from the midline. They lie in the posterior part of the super ciliary arcs, in between the external and internal faces of the frontal bone. These sinuses begin to develop as upward extensions of the anterior portion of the nasal capsule around the fourth fetal month. They may also arise from the laterally placed anterior ethmoidal cells, the anterior part of the frontal recess or from the frontal furrows. Anatomically, the frontal sinuses appear at the age of one year, grow larger after puberty, attaining maximum size by the age of 20 years (they remain stable throughout adult life). Radiographically, they become evident by the age of seven to nine years [2,3].

As mentioned above, the frontal sinuses are unique for every individual, which was first proposed by Zukerkandl in 1875 [3]. The first human identification through frontal sinus analysis to be accepted in a court case in the United States was described by Culbert and Law in 1927 [4].

The use of frontal sinus radiographs in confirming the identity of human remains of an unknown individual has a relatively long history in forensics. The present study comprised of 100 subjects (50 males and 50 females). Similar studies were conducted by Goyal, *et al*, Verma, *et al*, and Camargo, *et al*. on 100 individuals (50 males and 50 females) [3,5,6].

Our study was conducted on individuals aged 20 years and above (mean age = 38.06 years for males, 37.28 years for females), as the frontal sinuses are said to attain full maturity by this age [2]. Similar studies were conducted by Verma, *et al*. in subjects aged 20 years and above, by Kaur, *et al*. with age ranging from 20 to 36 years, Uthman, *et al*. 20 to 49 years, Camargo, *et al*. 20 to 30 years,

Etugrul, *et al*. 20 to 83 years and by Mathur, *et al*. in individuals with the mean age of 21 years [3,6-10].

We utilized the digital PNS view radiographs for studying the frontal sinuses. Similar studies, making use of the same, were conducted by Goyal, *et al*, while a modification of the PNS view - the Caldwell view, was used by Verma, *et al*, Mathur, *et al*, Kaur, *et al*, and Camargo, *et al* [3,5-7,10]. However, Belaldavar, *et al*. used the digital Postero Anterior view radiograph while Shim, *et al*, Uthman, *et al*, and Etugrul, *et al*. studied the frontal sinuses with the help of Computerised Tomographic Scans [8,9,11,12].

The Kodak Digital Imaging Software 6.12.32.0 was used for measuring the right and left width and height of the frontal sinuses in our study and the areas were calculated manually by determining the products of the widths and heights thus obtained. The various other softwares utilized by Kaur, *et al*, Camargo, *et al*, Belaldavar, *et al*, and Etugrul, *et al*. were the Auto CAD 2010, SIARCS 3.0 (EMBRAPA), Adobe Photoshop CS3 Extended and Di com Viewer program software's respectively [6,7,9,11]. However, Verma, *et al*, and Mathur, *et al*. determined the dimensions of the frontal sinuses manually [3,10].

In the current study, no significant difference was seen in the frontal sinus dimensions between males and females. Similar observation was quoted by Kaur *et al*, however larger frontal sinus dimensions were observed in males in comparison to females, by Shim, *et al*, Camargo, *et al*, and Etugrul, *et al* [6,7,9,12]. Also, in our study, the frontal sinuses showed low accuracy in predicting gender i.e. 62% accuracy in predicting females and 46% accuracy in predicting males (similar to Belaldavar, *et al*, Verma, *et al*, and Goyal, *et al*), as opposed to statistically significant/ high accuracy rates in the range of 80 - 90%, as noted by Camargo, *et al*. and Uthman, *et al*. in their studies [3,5,6,8,11].

Conclusion

To conclude, the frontal sinuses may be utilized in forensic odontology for gender determination. However, it should be kept in mind that there may be a scope for variations in the dimensions of the frontal sinuses or their inter-individual variability, owing to environmental or genetic factors. Hence, as gender determination is such an important aspect of forensic odontology and no studies with regard to the frontal sinus, quoting definitive values for the

same, are available yet, thus, further studies with incorporation of new parameters and the use of larger samples, which would be more representative of the Indian population, are recommended.

Conflict of Interest

The authors do not wish to declare any conflict of interest.

Bibliography

1. Marana AN, *et al.* "Towards an Automatic Frontal Sinus Identification System 1". (2008).
2. Schuller A. "A note on the identification of skulls by x-ray pictures of the frontal sinuses". *The Medical Journal of Australia* 1 (1943): 554-557.
3. Verma S, *et al.* "Radiomorphometric Analysis of Frontal Sinus for Sex Determination." *Journal of Forensic Dental Sciences* 6 (2014): 177-182.
4. Culbert W and FM Law. "Identification by Comparison of Roentgenograms: Of Nasal Accessory Sinuses and Mastoid Processes". *Journal of the American Medical Association* 88 (1927): 1634-1636.
5. Goyal M., *et al.* "Are Frontal Sinuses Useful Indicators of Sex?" *Journal of Forensic Dental Sciences* 20 (2013): 91-94.
6. Camargo JR, *et al.* "The Frontal Sinus Morphology in Radiographs of Brazilian Subjects: Its Forensic Importance". 24 (2007): 239-243.
7. Kaur N., *et al.* "The Forensic Importance of Frontal Sinus in Gender Discrimination the Forensic Importance of Frontal Sinus in Gender Discrimination: A Morphometric Study". 5 (2013): 2-5.
8. Uthman AT, *et al.* "Evaluation of Frontal Sinus and Skull Measurements Using Spiral Ct Scanning: An Aid in Unknown Person Identification". *Forensic Science International* 197 (2010): 124.e1-7.
9. Tatlisumak E, *et al.* "Ct Study on Morphometry of Frontal Sinus, Poster Presentation". 5 (2006): 44.
10. Mathur H., *et al.* Conventional Frontal Sinus Imaging in Identification of Sex: Original Study. In Population of Udaipur City 1 (2013): 33-37.
11. Belaldavar C, *et al.* "Assessment of Frontal Sinus Dimensions to Determine Sexual Dimorphism among Indian Adults". *Journal of Forensic Dental Sciences* 6 (2014): 25-30.
12. Shim BK, *et al.* "Anthropometric Analysis of Frontal Sinus Using 3D CT in Koreans". *Journal of the Korean Society Plastic and Reconstructive Surgeons* 38 (2011): 594-601.

Volume 2 Issue 12 December 2018

© All rights are reserved by Suzanne Tanya Nethan, et al.