

## Schwannoma of the Tongue- A Case Report

Kanchan Shah<sup>1\*</sup>, Prashant Pandilwar<sup>2</sup>, Suday G Rajurkar<sup>3</sup>, Abhishek Akare<sup>3</sup>, Priyanka Chawle<sup>4</sup> and Neha Lanjewar<sup>5</sup>

<sup>1</sup>Professor, Department of Oral and Maxillofacial Surgery, GDC, Aurangabad, India

<sup>2</sup>Professor and H.O.D, Department of Oral and Maxillofacial Surgery, GDC, Aurangabad, India

<sup>3</sup>Assistant Professor, Department of Oral and Maxillofacial Surgery, GDC, Aurangabad, India

<sup>4</sup>Clinical Assistant, Government Dental College, Nagpur, India

<sup>5</sup>Intern, V S P MDental College, Nagpur, India

\*Corresponding Author: Kanchan Shah, Professor, Department of Oral and Maxillofacial Surgery, GDC, Aurangabad, India.

Received: September 10, 2018; Published: September 28, 2018

### Abstract

Schwannoma of the tongue is a benign, usually solitary encapsulated neoplasm of nerve sheath origin. Its presentation in the head and neck region is approximately 25 - 45% and only 1 - 2% in the oral cavity. Tongue is considered to be the most common site. We report here a case of schwannoma of the tongue in an 11-year-old female who presented with a painless, slow growing swelling on the dorsal aspect of the tongue for 6 months. Complete excision was carried out under local anaesthesia. No recurrence has been noted till date.

**Keywords:** Neurilemmoma; Schwannoma; Tongue

### Introduction

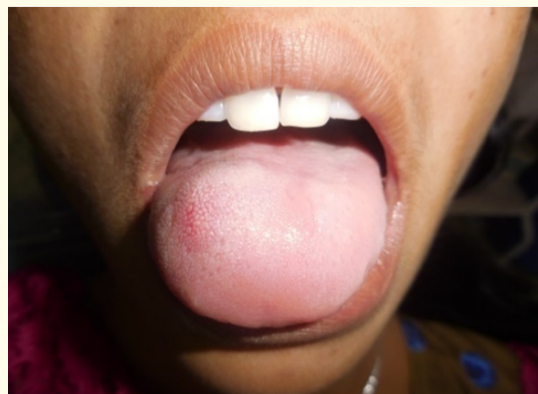
Neurilemmoma, also known as schwannoma is a benign, usually solitary, encapsulated mass originating from the nerve sheath tumour. Its presentation in the head and neck region is approximately 25 - 45% and only 1 - 2% in the oral cavity [1]. We present here a case of neurilemmoma(schwannoma) of the tongue.

### Case Report

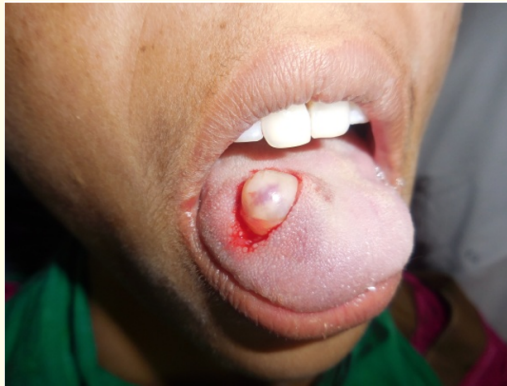An 11-year-old female presented to the Department of Oral and Maxillofacial Surgery patient presented with a complaint of a slow growing, painless swelling on the dorsal aspect of the tongue. The patient reported that the mass had been there for approximately 1 - 1.5 years and had not grown significantly over the time. On examination, the swelling was firm, sessile mass of approximately 1.5 x 1.5 cms in size on the dorsal aspect of the anterior two thirds of the tongue; close to the right lateral border into the substance of the tongue. Overlying mucosa was normal with no signs of inflammation or ulceration. No lymphadenopathy was noted. Radiologic examination of the swelling to aid in diagnosis was not carried out as the mass was easily accessible and palpable and was close to the tip of the tongue. The rest of the oral cavity did not

yield any significant findings. Complete excision of the mass was hence carried out under local anaesthesia.

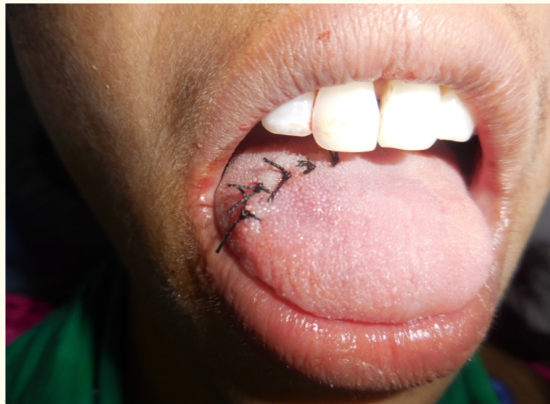The excised specimen was an encapsulated mass, greyish-yellow in colour with encapsulation. The histopathological examination showed an evidence of Antoni A and Antoni B cells with hyalinization around the vessels which was suggestive of neurilemmoma. No recurrence has been seen till date.



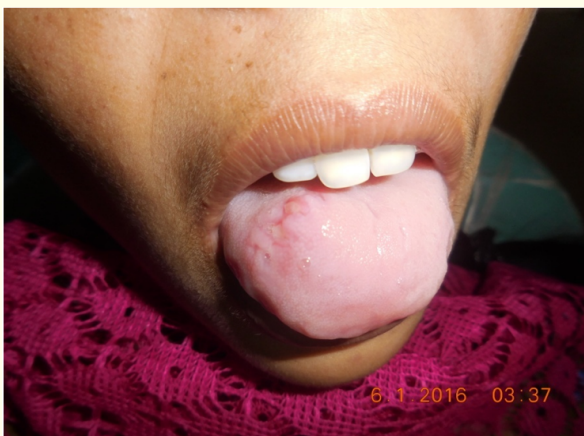**Figure 1:** Showing swelling in tongue.



**Figure 2:** Tumour mass exposed via an elliptical incision over the swelling.



**Figure 3:** Closure achieved.



**Figure 4:** Post-operative follow up 1 month later.

## Discussion

The term Schwannoma was coined by Ackerman and Taylor [2]. Neurilemmoma arises from the schwann cells of the peripheral, autonomic and cranial nerve [3,4]. It can be solitary or multiple. The etiology of neurilemmoma is not yet well elucidated. Head and neck are more commonly involved in this neoplasm. Intraoral schwannoma is most commonly seen in tongue followed by palate, floor of the mouth, buccal mucosa, gingival, lip and vestibule [5,6]. No age and gender predilection are seen. Clinically, it presents as a slow growing painless mass [7]. Associated symptoms can be dysphagia, pain, voice changes usually seen when schwannoma involves posterior one third of the tongue [8]. Paraesthesia is rarely seen. Computed tomography usually shows well defined homologous lesions. However Magnetic Resonance Imaging (MRI) is superior in mass localization and its relation to other structures, accurate measurement of mass size and also malignant transformation [9]. Treatment of schwannoma is always surgical excision. Complete surgical excision with adequate safe margins proves to be the ideal treatment and also avoids recurrence [10,11]. Currently, the use of CO<sub>2</sub> laser and electrocautery for excision of tongue schwannoma has been reported [12]. If adequate surgical excision is carried out, chances of recurrence are rare [4].

Histological examination shows schwannoma to be an encapsulated tumour. Two types of cells are observed in schwannoma: Antoni A and Antoni B [13]. Antoni A consists of closely packed Schwann cells forming bundles or palisading pattern. These cells show elongated nuclei. A characteristic Vero cay body is seen which is described as an amorphous substance in between the rows of nuclei. Whereas in Antoni B type the Schwann cells are arranged in a very loose pattern in the reticulum fibres and microcysts. Formation of microcysts can be attributed to the fact that the increasing tumour size leads to vascular insufficiency.

## Conclusion

For a long standing swelling in the tongue, the differential diagnosis of neurofibroma, granular cell tumour, benign salivary gland tumors, leiomyoma, rhabdomyoma etc. need to be considered. Since the lesion was small, an excisional biopsy was performed directly. Early diagnosis and adequate excision of tumour mass with long term follow up is the mainstay of the treatment. Long term follows up to check for any recurrence is mandatory.

## Bibliography

1. Katz AD, *et al.* "Neurosurgeons neoplasms of major nerves of head and neck". *Surgery, Gynaecology, and Obstetrics* 111 (1971).
2. Ackerman LV and Taylor FH. "Neurogenesis tumors within the thorax: a clinicopathologic evaluation of forty-eight cases". *Cancer* 4 (1951): 669-691.
3. Arda H., *et al.* "An unusual site for an intraoral schwannoma: a case report". *American Journal of Otolaryngology* 24 (2003): 348-350.
4. Hsu Y., *et al.* "Schwannoma (neurilemmoma) of the tongue". *Acta Otolaryngology* 126 (2006): 861-865.
5. Tsushima F, *et al.* "Schwannoma in the floor of the mouth: a case report and clinicopathological studies of 10 cases in the oral region". *Journal of Oral and Maxillofacial Surgery, Medicine, and Pathology* 24 (2012): 175-179.
6. Gallo W, *et al.* "Neurilemmoma: review of the literature and report of five cases". *Journal of Oral Surgery* 35 (1977): 235-236.
7. De Bree R, *et al.* "Submandibular approach for excision of a large schwannoma in the base of tongue". *European Archives of Oto-Rhino-Laryngology* 257 (2000): 283-286.
8. Ying YL, *et al.* "Base of tongue schwannoma: a case report". *Laryngoscope* 116.7 (2006): 1284-1287.
9. Sawhney R, *et al.* "Tongue base schwannoma: report, review, and unique surgical approach". *American Journal of Otolaryngology* 29.2 (2008): 119-122.
10. George NA, *et al.* "Schwannoma base tongue: Case report and review of literature". *Gulf Journal of Oncology* 1.16 (2014): 94-100.
11. Sharma S and Rai G. "Schwannoma (neurilemmoma) on the base of the tongue: a rare clinical case". *American Journal of Case Reports* 17 (2016): 203-206.
12. Mehrzad H, *et al.* "Schwannoma of the tongue base treated with transoral carbon dioxide laser". *Lasers Medical Science* 21 (2006): 235-237.
13. Ballesteros F, *et al.* "Base of tongue neurilemmoma: excision by transoral laser microsurgery". *Acta Otolaryngology* 127 (2007):1005-1007.

**Volume 2 Issue 10 October 2018**

**© All rights are reserved by Kanchan Shah., et al.**