



Irritational Fibroma: A Case Report

Parkavi A^{1*}, Mala Dixit Baburaj², Sandeep Pimpale³ and Rajiv S Desai⁴

¹Postgraduate Student, Department of Periodontics, Nair Hospital Dental College, Maharashtra University of Health Sciences, Mumbai, India

²Professor and Head, Department of Periodontics, Nair Hospital Dental College, Maharashtra University of Health Sciences, Mumbai, India

³Assistant Professor, Department of Periodontics, Nair Hospital Dental College, Maharashtra University of Health Sciences, Mumbai, India

⁴Professor and Head, Department of Oral Pathology and Microbiology, Nair Hospital Dental College, Maharashtra University of Health Sciences, Mumbai, India

***Corresponding Author:** Parkavi A, Postgraduate Student, Department of Periodontics, Nair Hospital Dental College, Maharashtra University of Health Sciences, Mumbai, India.

Received: August 09, 2018; **Published:** September 21, 2018

Abstract

Irritational fibroma is a reactive lesion that is among the most common oral soft -tissue lesions, caused due to local trauma or irritation by plaque, calculus, overhanging margins, and restorations, that may cause esthetic and functional problems. This article addresses the diagnosis, histological features and treatment of a case of irritational fibroma in a young female patient.

Keywords: Fibro-Epithelial Hyperplasia; Irritational Fibroma; Gingival Growth; Mandibular Anterior Region

Abbreviation

IOPA: Intra Oral Periapical Radiograph

Introduction

Fibroma is considered the most common benign growth in the oral cavity [1]. Irritational fibroma is a common, benign, slow-growing, soft tissue tumor. It usually presents as an asymptomatic mass which gradually increases in size [2]. The etiological factors for these lesions can be imputed to the irritants like plaque, calculus, overhanging margins and restorations [3-5]. Irritational fibroma represents a reactive focal fibrous hyperplasia due to trauma or local irritation [3,6,7]. Here we are presenting a case of irritational fibroma in an 18-years old female in mandibular anterior region.

Case Report

Clinical examination

An 18 years old female had reported to the Department of Periodontics, Nair Hospital Dental College, Mumbai, India, with the chief complaint of growth in the gums in the lower front teeth region, present since the last 4 months.

The patient was apparently all right 4 months back, when she noticed a small growth in the mandibular anterior teeth region. The growth was gradual in onset, slowly progressing and with time had increased to present day size. It was associated with bleeding, but no associated pain was seen. Her past medical, dental and drug history were not significant. There were no contributory family and habit history.

On extraoral examination, the face appeared bilaterally symmetrical, with competent lips and the lymph nodes were not palpable. On intraoral examination, a 7 mm x 5 mm x 5 mm roughly ovoid gingival growth was seen in the interproximal region extending mesio-distally from the distal line angle of 42 to the mesial line angle of 43 and apico-coronally from gingival margin till the incisal third of the crown and the growth also had a lingual extension. The growth was pinkish, firm, well defined, mobile, pedunculated, non-pulsating, smooth surfaced and associated with bleeding. Hard tissue examination revealed normal complement of teeth with mild crowding in the mandibular anterior region with plaque and calculus deposits.

On the basis of the history and clinical findings a provisional diagnosis of irritational fibroma with respect to 42, 43 was given.

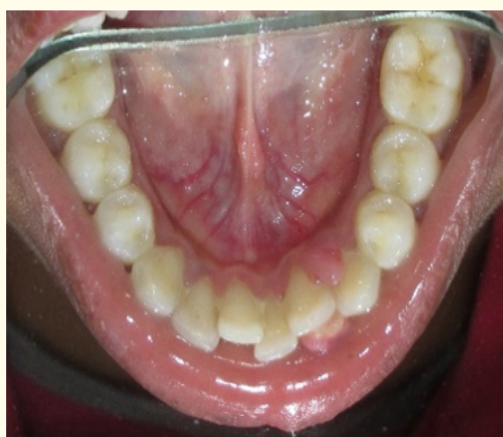
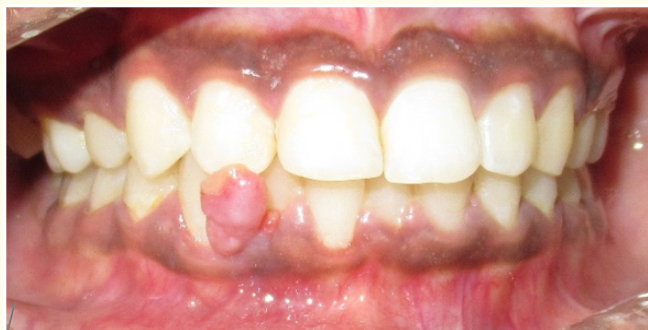
Figure 1: Pre-operative presentation of growth
- a) buccal view and b) lingual view.

Investigations

IOPA of the region revealed no significant bone loss with respect to 42, 43. Routine hematological examinations including hemogram, bleeding and clotting time were found to be within normal physiological limits.

Differential diagnosis

Hyperplastic fibroma, peripheral giant cell granuloma, peripheral ossifying fibroma, pyogenic granuloma was considered in differential diagnosis. Due to the presence of local factors, crowding of teeth, no significant bone loss or calcifications, the clinical appearance and the site of the lesion, a final diagnosis of irritational fibroma was considered.

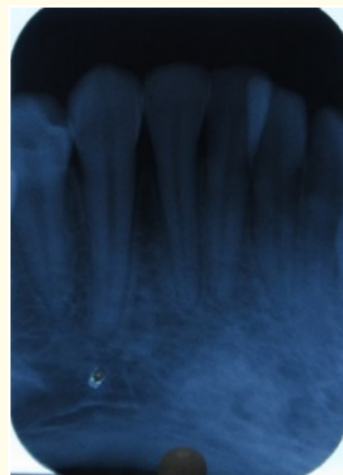

Figure 2: IOPA.

Treatment

Phase 1 therapy consisted of a thorough scaling and root planing and oral hygiene instruction were given. The patient was demonstrated the proper brushing technique (Modified Bass Technique). Patient was advised 0.2% chlorhexidine mouth-rinse 10 ml, 1:1 dilution, twice daily for 15 days. The patient was reviewed after 1 week and there was considerable reduction in the size of the growth.

Phase II therapy consisting of surgical excision of the growth was planned and executed under local anesthesia following which periodontal dressing was placed and antibiotic and analgesic were prescribed. At 1week post-operative, the surgical site had healed uneventfully. The patient was kept on periodontal maintenance therapy and proper brushing technique and oral hygiene instructions were re-instated. There was no recurrence of the lesion seen on 4 months recall post-operatively. The patient was then referred to the Department of Orthodontics, for correction of the crowding of mandibular anterior teeth, to prevent the recurrence of the gingival growth.

Histopathology

The overall histopathological features were suggestive of fibroepithelial hyperplasia which were suggestive of irritational fibroma.

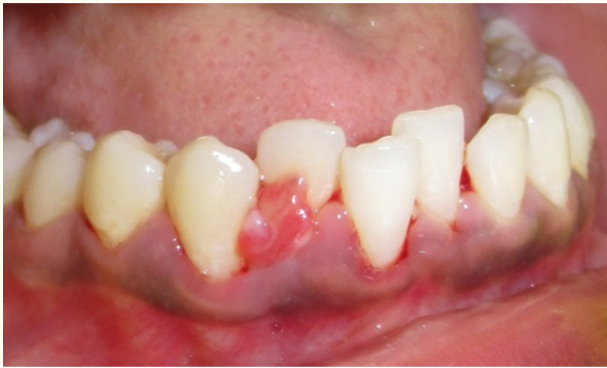

Figure 3: After Phase I therapy.

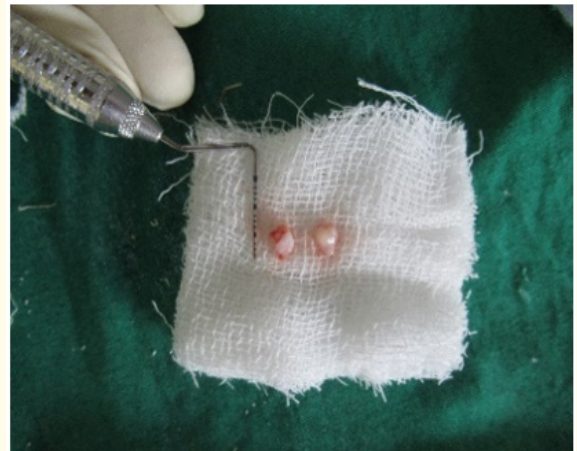


Figure 6: Specimen for histopathologic examination.

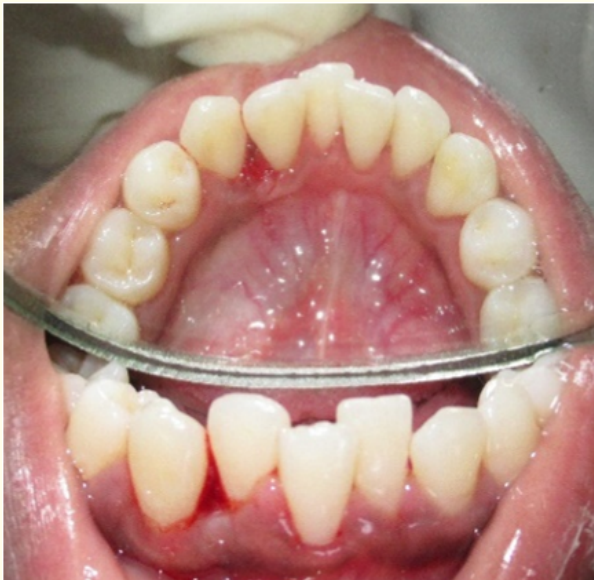

Figure 4: After surgical excision.

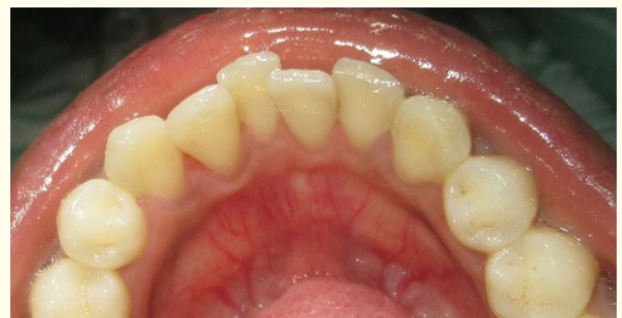
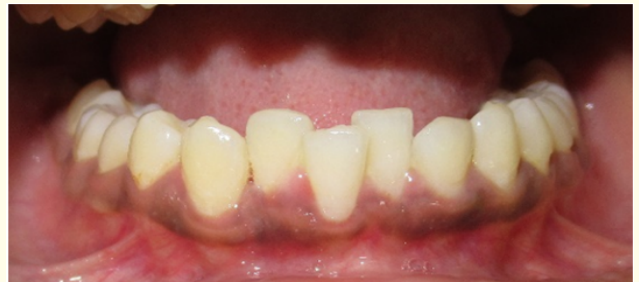
Figure 7: 1 week post-surgery a) buccal view b) lingual view.

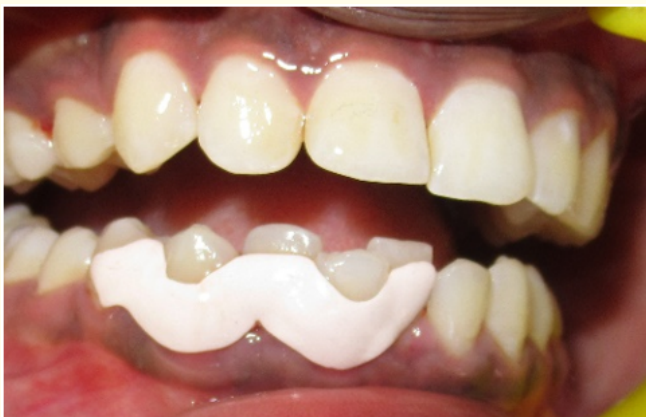

Figure 5: Periodontal dressing.

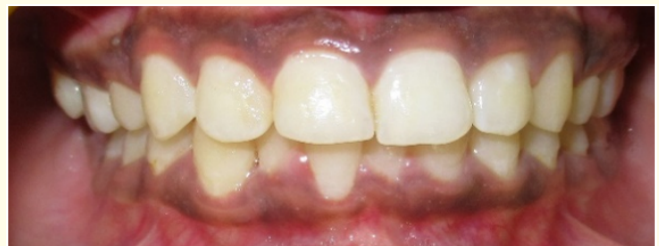

Figure 8: 4 months post-surgery.

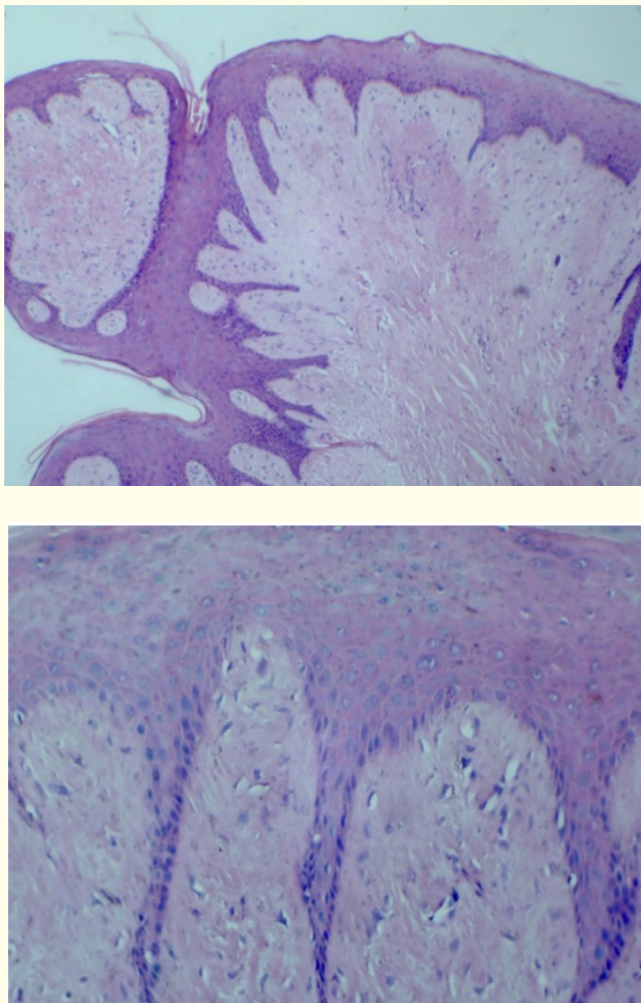


Figure 9: a) and b): Histopathology.

Discussion

As the oral mucosa is constantly under the influence of various internal and external stimuli, it exhibits a variety of developmental disorders, irritation, inflammation, and neoplastic conditions [2,8]. One of these conditions is reactive focal overgrowths [2,9]. Reactive lesions are tumor-like hyperplasias and show a response to a low-grade irritation or injury, such as chewing, food impaction, calculus, iatrogenic injuries like broken teeth, overhanging dental restorations, and extended flanges of the denture [2,10,11]. Traumatic or irritational fibroma is a common, benign, exophytic, and reactive oral lesion that develops secondary to injury and constitutes about 7.4% of oral soft-tissue lesions [2,12,13]. Irritational fibroma is also known as focal fibrous hyperplasia, oral

fibroma, or fibromatosis fibroma [2]. It shows female predilection than males and is seen more frequently in the third and fourth decade of life [2,9].

The high female predilection and a peak occurrence in the second decade of life suggested hormonal influences [14]. Approximately, 60% of irritation fibromas involve the maxilla and more often found in the anterior region, with 55 - 60% present at the incisor-cuspid region [2,15]. It is usually reported with the diameter of 1.5 rarely reaching 3 cm; very few case reports are present in the literature with the lesion measures about 6 - 9 cm [9,14]. In the present case, the lesion was present in the mandibular anterior region with respect to 42, 43 and measured 7 mm x 5 mm x 5 mm.

Clinical features comprise sessile or pedunculated masses with smooth or injured surfaces and are seen in different colors ranging from pale to bright pink to red [2,16,17]. The size of these reactive hyperplastic masses can be greater or lesser, depending on the components of the inflammatory reaction and healing response exaggerated in the particular lesion [2,4,18].

Irritational fibroma can also produce migration of teeth with destruction of the interdental bone [2,17]. Differential diagnosis includes pyogenic granuloma, peripheral giant-cell granuloma, and peripheral ossifying fibroma, which may also arise as a result of irritation due to plaque microorganisms and other local irritants [2,19].

Histopathologically, the sections show hyperplastic stratified squamous epithelium which is partly hyperkeratotic and hyperorthokeratotic at some places. Thin, finger-like rete ridges extend into underlying fibro-cellular connective tissue stroma. Solid nodular mass of dense hyalinized fibrous connective tissue arranged in haphazard fascicles with moderate chronic inflammatory cell infiltrate can also be seen at a few sites [1,2,20].

Treatment of irritation fibroma aims at elimination of etiological factors followed by scaling of adjacent teeth and total surgical excision along with involved periodontal ligament and periosteum to minimize recurrence. Any identifiable irritant should be removed. If left untreated, it may increase in size and may affect the mastication, speech and esthetics. On infection, may cause pain, bleeding and may lead to abscess formation. It is imperative to locate the etiology and correct it completely. For the myriad

histological patterns observed in reactive hyperplasia, connective tissue response to varied intensities of gingival irritation may be responsible. So, it is of prime importance to distinguish between hyperplasia and neoplasia as neoplasia's are not self-limiting conditions and long-standing hyperplastic lesions in presence of chronic irritation can get converted to neoplasia [21].

Long-term post-operative follow-up is very important because of the high growth potential of an incompletely removed lesion [2,9,22]. Recurrences are rare and may be caused by repetitive trauma at the same site. The lesion does not have a risk for malignancy [2,15].

Conclusion

Irritational fibromas are one of the most common oral fibromas. A thorough history, clinical, radiographic and histologic examination should be carried out to rule out other oral lesions and arrive at an accurate diagnosis. Early detection, elimination of the irritations and the treatment of the lesions is of utmost importance.

Conflict of Interest

There are no conflicts of interest.

Bibliography

1. Esmeili T, et al. "Common benign oral soft tissue masses". *Dental Clinics of North America* 49 (2005) 223-240.
2. Kirti Saharan, et al. "Irritational fibroma of gingiva in a young female: A case report". *Journal of Medicine, Radiology, Pathology and Surgery* 4 (2017): 15-17.
3. Sachit Anand Arora, et al. "Irritational Fibroma: A Case Report". *International Journal of Oral Health and Medical Research* 2.5 (2015).
4. Mathur LK, et al. "Focal fibrous hyperplasia: a case report". *International Journal of Dental Clinics* 2.4 (2010).
5. Nartey NO, et al. "Localized inflammatory hyperplasia of the oral cavity: clinico-pathological study of 164 cases". *Saudi Dental Journal* 6.3 (1994): 145-150.
6. Jafarzadeh H, et al. "Oral pyogenic granuloma: a review". *Journal of oral science* 48.4 (2006): 167-175.
7. Baldawa R, et al. "An unusually large oral pregnancy tumor". *Pravara Medical Review* 3.4 (2011): 23-26.
8. Kadeh H, et al. "Reactive hyperplastic lesions of the oral cavity". *Iran Journal Otorhinolaryngology* 27 (2015): 137-144.
9. Bagde H, et al. "Irritation fi broma - A case report". *International Journal of Dental Clinics* 5.1 (2013): 39-40.
10. Naderi NJ, et al. "Reactive lesions of the oral cavity: A retrospective study on 2068 cases". *Dental Research Journal (Isfahan)* 9 (2012): 251-255.
11. Reddy V, et al. "Reactive hyperplastic lesions of the oral cavity: A ten-year observational study on North Indian population". *Journal of Clinical and Experimental Dentistry* 4.3 (2012): e136-e140.
12. Rathva VJ. "Traumatic fi broma of tongue". *BMJ Case Reports* (2013).
13. Yeatts D and Burns JC. "Common oral mucosal lesions in adults". *American Family Physician* 44 (1991): 2043-2050.
14. Ashish Lanjekar, et al. "An Unusually Large Irritation Fibroma Associated with Gingiva of Lower Left Posterior Teeth Region". *Case Reports in Dentistry* (2016).
15. Das U and Azher U. "Peripheral ossifying fi broma". *Journal of Indian Society of Pedodontics and Preventive Dentistry* 27.1 (2009): 49-51.
16. Effi om OA, et al. "Focal reactive lesions of the gingiva: An analysis of 314 cases at a tertiary health institution in Nigeria". *Nigerian Medical Journal* 52.1 (2011): 35-40.
17. Amirchaghmaghi M, et al. "Survey of reactive hyperplastic lesions of the oral cavity in Mashhad, Northeast Iran". *Journal of Dental Research, Dental Clinics, Dental Prospects* 5.4 (2011): 128-131.
18. Macleod RI and Soames J. "Epulides: A clinicopathological study of a series of 200 consecutive lesions". *British Dental Journal* 163.2 (1987): 51-53.
19. Kolte AP, et al. "Focal fibrous overgrowths: A case series and review of literature". *Contemporary Clinical Dentistry* 1.4 (2010): 271-274.
20. Barker DS and Lucas R. "Localized fibrous overgrowths of the oral mucosa". *British Journal of Oral Surgery* 5 (1967): 86-92.
21. Navnita Singh, et al. "Traumatic Fibroma: A Case Series". *Journal of Health Science Research* 7.1 (2016): 28-31.
22. Walters JD, et al. "Excision and repair of the peripheral ossifying fibroma: A report of 3 cases". *Journal of Periodontology* 72.7 (2001): 939-944.

Volume 2 Issue 10 October 2018

© All rights are reserved by Parkavi A, et al.