Acta Scientific Dental Sciences (ISSN: 2581-4893)

Volume 2 Issue 7 July 2018

Case Report

# MTA Pulpotomy in Cariously Exposed Pulp – A Report of 3 Cases

**C Nandha Kumar[1], S Sandhya[1]*, C Diji Johny[1], P Adhitya Vasun[1], K Manigandan[1] and Saravana Selvam S[2]**

*[1]Postgraduate Student, Department of Conservative Dentistry and Endodontics, Thai Moogambigai Dental College, Chennai, India*

*[2]Senior Lecturer, Department of Oral medicine and Radiology, Thai Moogambigai Dental College, Chennai, India*

***Corresponding Author:** S Sandhya, Postgraduate Student, Department of Conservative Dentistry and Endodontics, Thai Moogambigai Dental College, Chennai, India.

**Received:** June 15, 2018; **Published:** June 20, 2018

## Abstract

The removal of the coronal portion of a cariously exposed vital pulp to preserve the vitality of the remaining radicular portion may be performed as an alternative procedure over conventional root canal therapy.

**Objective:** Aim of this case report is to evaluate the clinical outcome of pulpotomy using MTA.

**Methodology:** Permanent molars with caries involving pulp were treated by MTA pulpotomy and reviewed after 6 months.

**Result:** 6 months review showed favourable and predictable result.

**Conclusion:** In our present case series, a successful outcome was achieved at the end of 6 months for MTA pulpotomy.

**Keywords:** Pulpotomy; Coronal Pulpotomy; MTA

## Introduction

Preservation of pulp is the primary goal of restorative procedures, especially in the young permanent dentition [1]. The treatment of teeth with carious pulp exposure has been a controversial issue in endodontics [2]. However, clinical success rate was found to be high when mineral trioxide aggregate (MTA) was used for vital pulp therapy of cariously exposed permanent teeth diagnosed with reversible pulpitis [3].

In carious exposures of young permanent teeth, the inflamed pulp tissue beneath an exposure is removed to reach healthy pulp tissue (pulpotomy) [1]. The inflamed but vital pulp of a permanent tooth may have a chance to return to a healthy, functional status after MTA pulpotomy [4].

MTA was introduced by Torabinejad in the field of endodontics for its applications in pulp capping, pulpotomy cases, and sealing accidental perforations of the root canal, because of excellent biocompatibility and sealing ability [5].

MTA stimulates new hard tissue formation and promotes pulp repair [6]. Thicker dentinal bridges are formed and the presence of an odontoblastic layer was reported in histological evaluation of teeth restored with MTA [6]. Therefore, in our case series three patients with carious pulpal exposures were treated with MTA pulpotomy.

## Case Report

### Case 1

A 35-year old female patient was referred to the Department of Conservative Dentistry and Endodontics at Thai Moogambigai Dental College with the chief complaint of sensitivity in the right lower back restored tooth (Figure 1). Examination revealed a fractured composite restoration in tooth with secondary caries #46 which was close to the pulp. Sensibility test revealed positive response to thermal and electric pulp test (EPT). A provisional diagnosis of reversible pulpitis was determined based on clinical and radiographic examination. MTA pulpotomy was done (Figure 2 and 3).

**Figure 1:** Pre- operative radiograph.

**Figure 2:** MTA placed.

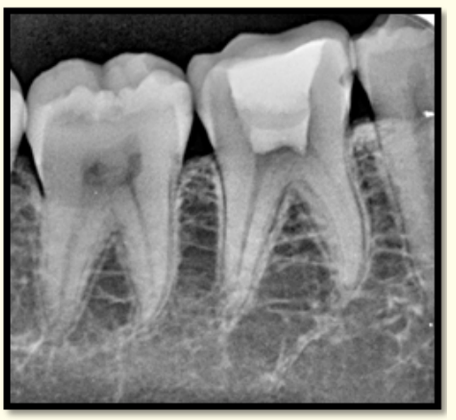

**Figure 3:** Post OP 6-months follow up.

## Case 2

A 28-year old female patient was referred to the Department of Conservative Dentistry and Endodontics at Thai Moogambigai Dental College with the chief complaint of sensitivity on the left lower back tooth (Figure 4). Examination revealed a fractured composite restoration with secondary caries in tooth #36 which was close to the pulp. Sensibility test revealed positive response to thermal and electric pulp test (EPT). A provisional diagnosis of reversible pulpitis was determined based on clinical and radiographic examination. MTA pulpotomy was done (Figure 5 ad 6).

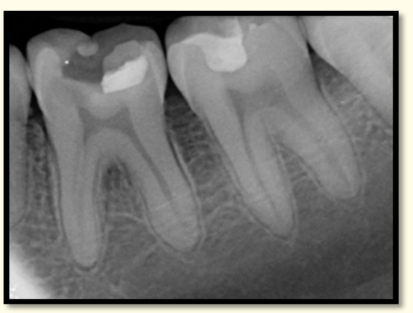

**Figure 4:** Pre-operative radiograph.

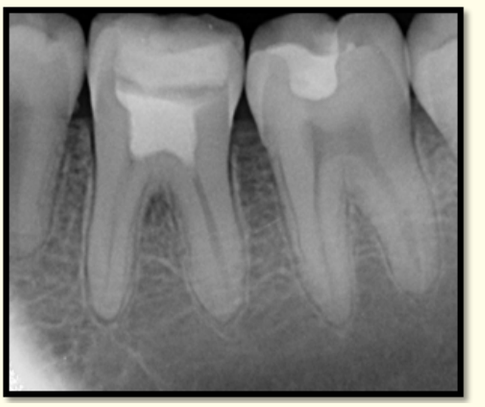

**Figure 5:** MTA placed.

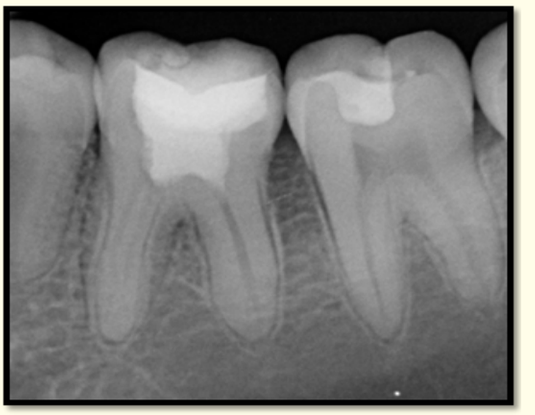

**Figure 6:** Post OP 6-months follow up.

## Case 3

A 41-year old female patient was referred to the Department of Conservative Dentistry and Endodontics at Thai Moogambigai Dental College with the chief complaint of sensitivity on the left lower back tooth region (Figure 7). Sensibility test revealed positive response to thermal and electric pulp test (EPT). A radiographic examination revealed presence of caries involving pulp in #36 and the tooth was diagnosed based on the clinical and radiographic examination as reversible pulpitis. MTA pulpotomy was done (Figure 8 and 9).

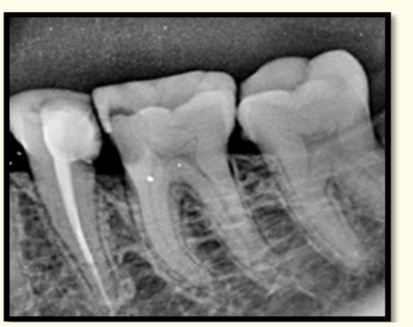

**Figure 7:** Pre- operative radiograph.

**Figure 8:** Post OP 3-months follow up

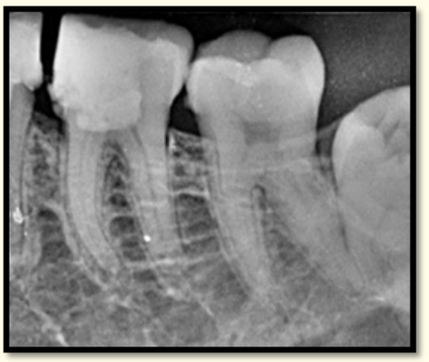

**Figure 9:** Post OP 6-months follow up.

**Clinical protocol for pulpotomy** (Based on Bogen and Chandler) [7]

Local anaesthesia was administered and rubber dam isolation was done. Access cavity was prepared with sterile diamond burs under copious water irrigation. The pulp chamber was irrigated with 2% sodium hypochlorite (NaOCl) to remove inflamed tissue and then haemostasis was achieved in 5 - 10 minutes. MTA was placed on the remaining vital radicular pulp tissue [3]. Moist cotton pellet was placed above the MTA and the cavity was restored with 3.5 mm of Glass ionomer cement [8]. After 24hr, the Glass ionomer restoration and moist cotton pellet were removed and set of MTA was verified. Final composite restoration was done. At the 6-month follow-up visit, the radiographic findings revealed no periapical radiolucency and the patient was asymptomatic.

## Discussion

With the advancement in progression of materials and techniques along with better understanding of healing of pulp in recent years, coronal pulpotomy has gained importance and is practiced as an alternative to RCT for carious exposure of teeth with vital pulps [9]. Coronal pulpotomy treatment involves removal of entire coronal pulp tissue leaving the radicular pulp vital [10].

Coronal pulpotomy has been considered as a definitive treatment to manage carious pulp exposure for primary teeth and young immature tooth [11]. It has been shown that the cariously exposed vital pulp after the elimination of bacteria can return to a healthy status [4].

In our study, we performed coronal pulpotomy in all the three cases over the partial pulpotomy. With coronal pulpotomy, the pulp present in the pulp chamber floor was completely removed leaving the residual radicular pulp. In partial pulpotomy, it is difficult to determine the disease progression clinically, thus we choose coronal pulpotomy in all the three cases [12].

Success of coronal pulpotomy is based on the disinfection and haemorrhage control from the pulp chamber. NaOCl has been demonstrated to be effective in achieving the haemorrhage control [12].

The most important factors contributing to the success of coronal pulpotomy are diagnosis of the pulpal conditions, complete isolation during the procedure along with maximum sealing of the pulpal complex by using a well sealing pulp cap material and proper final restoration to ensure adequate seal and prevent bacterial leakage towards the remaining pulp in the canal [13].

In our study we used MTA as a pulpotomy material; MTA has got a better sealing ability along with excellent marginal adaptation and success rate over 90% [3].

Based on the European society of Endodontology, success is considered when there is absence of clinical symptoms, absence of radiographic changes and radiographic evidence of reparative dentin formation. In our study the patients were followed up for six months and all the patients were asymptomatic. It has been stated that minimum six months follow up is adequate for evaluation [14].

## Conclusion

In our present case series, a successful outcome was achieved with MTA coronal pulpotomy over the period of six months follow up. However, a longer follow up is necessary to evaluate MTA pulpotomy in carious exposures.

## Bibliography

1. American Academy of Pediatric Dentistry. "Guideline on Pulp Therapy for Primary and Young Permanent Teeth". Clinical Affairs Committee, Pulp Therapy Subcommittee (2004).

2. Linsuwanont., *et al*. "Treatment Outcomes of Mineral Trioxide Aggregate Pulpotomy in Vital Permanent Teeth with Carious Pulp Exposure: The Retrospective Study". *Journal of Endodontics* 43.2 (2017): 225-230.

3. Alqaderi H., *et al*. "MTA pulpotomy as an alternative to root canal treatment in children's permanent teeth in a dental public health setting". *Journal of Dentistry* 42.11 (2014): 1390-1395.

4. Chueh L and Chiang C. "Histology of Irreversible Pulpitis Premolars Treated with Mineral Trioxide Aggregate Pulpotomy". *Operative Dentistry* 35.3 (2010): 370-374.

5. Torabinejad M and Parirokh M. "Mineral Trioxide Aggregate: A Comprehensive Literature Review-Part II: Leakage and Biocompatibility Investigations". *Journal of Endodontics* 36.2 (2010): 190-202.

6. Aeinehchi., *et al*. "Mineral trioxide aggregate (MTA) and calcium hydroxide as pulp-capping agents in human teeth: a preliminary report". *International Endodontic Journal* 36.3 (2003): 225-235.

7. Bogen G and Chandler NP. "Vital pulp therapy". In Ingle JI, Bakand LK, Baumgartner JC, editors: Ingle's endodontics, ed 6, Hamilton, Ontario, Decker (2008).

8. Webber R., *et al*. "Sealing quality of a temporary filling material". *Oral Surgery, Oral Medicine, Oral Pathology* 46.1 (1978): 123-130.

9. Alqaderi H., *et al*. "Coronal pulpotomy for cariously exposed permanent posterior teeth with closed apices: A systematic review and meta-analysis". *Journal of Dentistry* 44 (2016): 1-7.

10. Simon S., *et al*. "Should pulp chamber pulpotomy be seen as a permanent treatment? Some preliminary thoughts". *International Endodontic Journal* 46.1 (2013): 79-87.

11. Aguilar P and Linsuwanont P. "Vital pulp therapy in vital permanent teeth with cariously exposed pulp: A systematic review". *Journal of Endodontics* 37.5 (2011): 581-587.

12. Galani M., *et al*. "Comparative evaluation of postoperative pain and success rate after pulpotomy and root canal treatment in cariously exposed mature permanent molars: A randomized controlled trial". *Journal of Endodontics* 43.12 (2017): 1953-1962.

13. Kunert GG., *et al*. "Permanent teeth pulpotomy survival analysis: retrospective follow-up". *Journal of Dentistry* 43.9 (2015): 1125-1131.

14. European Society of Endodontology. "Quality guidelines for endodontic treatment: consensus report of the European Society of Endodontology". *International Endodontic Journal* 39 (2006): 921-930.

**Volume 2 Issue 7 July 2018**