



Guided Bone Regeneration; A Predictable Augmentation Procedure in Implantology-An Overview

Seba Abraham¹, Dhanya BN^{2*}, Arunima PR³ and Reeja Mol MK⁴

¹HOD and Professor, Department of Periodontics, PMS College of Dental Science and Research, KUHS, India

²PG Student, Department of Periodontics, PMS College of Dental Science and Research, KUHS, India

³Professor, Department of Periodontics, PMS College of Dental Science and Research, KUHS, India

⁴Reader, Department of Periodontics, PMS College of Dental Science and Research, KUHS, India

***Corresponding Author:** Dhanya BN, PG Student, Department of Periodontics, PMS College of Dental Science and Research, KUHS, India.

Received: April 14, 2018; **Published:** May 22, 2018

Abstract

Guided bone regeneration procedure allows successful implant placement by regenerating lost bone at desired site. The versatile procedure not only stabilize the blood clot and bone graft in defect but also prevents the migration of epithelial and connective tissue cells into the region thus allows migration and proliferation of osteogenic cells to form new bone. Although, GBR procedure is technique sensitive, predictable outcomes could be obtained by understanding and utilization of proper surgical technique and postoperative patient compliance. Studies have indicated more complications while achieving vertical ridge augmentation than horizontal ridge augmentation. Complications can be either surgical or postoperative. The aim of this article is to provide an insight into the procedure and complications associated with GBR and guidelines for preventing and managing these clinical situations.

Keywords: Guided Bone Regeneration; Implant; Augmentation Procedures; Bone Grafts; Barrier Membranes; Complications

Abbreviations

DFDBA: Demineralised Freeze Dried Bone Allograft; FDBA: Freeze Dried Bone Allograft; GBR: Guided Bone Regeneration; GTR: Guided Tissue Regeneration; PRP: Platelet Rich Plasma

Introduction

Dental Implants are now an integral part of periodontal and restorative dentistry. They present a reliable way to restore function and esthetics in fully or partially edentulous patients. The process of osteointegration is the basis for dental implant success i.e. the direct anchorage of implant to bone without intervening fibrous connective tissue. Periodontal bone loss, gingival recession, tooth loss, and long-term use of removable appliances etc. results in alveolar defects that prevent the placement of implants in an optimal prosthetic position. It also leads to soft-tissue deficiencies that are unacceptable.

Patients often present for implant planning after tooth loss and alveolar ridge resorption. Anatomical structures such as nasal cavity, maxillary sinus, inferior alveolar nerve etc. may limit the available bone volume for implant placement [1]. In these situations, the clinician is obligated to perform augmentation procedures to reconstruct lost bone and place implants in a prosthetically driven position. So considerable research has been conducted to promote bone growth and regeneration and many predictable therapies are

recently introduced in implant dentistry for bone growth, including distraction osteogenesis, on lay bone grafting, and guided bone regeneration (GBR). Studies during the last decades have led to the new treatment approach referred to as guided tissue regeneration (GTR) [2].

Principle

GTR is based on the principle that specific cells contribute to the formation of specific tissues. Exclusion of the faster-growing epithelium and connective tissue from a periodontal defect for a minimum of 6 to 8 weeks allows the slower-growing tissues to occupy the space adjacent to the tooth. Osteoblasts, cementoblasts, and periodontal ligament cells are able to regenerate a new periodontium (new connective tissue fibers inserted into newly formed cementum and bone) on the diseased root surface. The concept behind this method is that periodontal ligament and perivascular cells have the potential for regeneration of periodontium. Guided bone regeneration is based on the biologic principles of guided tissue regeneration. In GBR technique undesirable non-osteogenic cells are prevented from entering the wound by means of a barrier membrane, thus allowing new bone formation [2].

Adequate bone volume at the site of implant placement is necessary for dental implant success [1]. Lack of bone volume may be due to congenital defects or periodontal diseases. Post-traumatic, postsurgical defects etc. may also result in loss of bone. Guided

bone regeneration (GBR) is the best documented for the treatment of localized bone deficiencies and has allowed the use of endosseous implants in areas of the jaw with insufficient bone volume. With GBR procedures the predictability and success rate at sites with bone defects can be as similar as without defects [3].

Historical perspective

Barrier membranes was first evaluated in 1950s and 1960s by Bassett, *et al.* [4], and Boyne, *et al.* [5], for osseous facial reconstruction. Nyman, *et al.* [6] Demonstrated that membranes act as a physical barrier to ingrowth of non-osteogenic cells. Lazzara, *et al.* [7], first applied GBR techniques with immediate implants. Dahlin, *et al.* [8], used GBR techniques for bone augmentation on the exposed threads of implants placed in inadequate ridges. Becker, *et al.* [9], successfully used ePTFE membrane with immediate implants placed in extraction sockets.

Materials

Historical perspective

The process of osteogenesis, osteoinduction, and osteoconduction are the mechanisms for bone regeneration. Osteogenesis is the process of formation of new bone. Osteoinduction is the process of transformation of mesenchymal stem cells into osteoblasts which deposit bone. The process of osteoconduction provides a scaffold, or matrix, for the deposition of new bone. Bone graft materials are of four different types namely autograft, allograft, xenograft and alloplast. They have any one or more of these mechanisms of action, depending on their origin and composition. Autogenous bone harvested from the patient is the gold standard, forms new bone by osteogenesis, osteoinduction, and osteoconduction. Allografts harvested from other individuals of same species are not osteogenic but having osteoconductive (FDBA) and possibly osteoinductive (DFDBA) properties. Xenografts (from other species)/alloplasts (synthetic materials) are only osteoconductive [10].

The use of these grafts should be based on the healing capacity, recipient site, and the time available for graft maturation. Xenografts and alloplasts can be used along with allografts for small defects in systemically healthy patients. Autografts could be used for larger defects [11]. For better clinical outcome barrier membrane should be used [12].

Barrier Membranes

Barrier membranes are required in GBR technique to separate slowly growing bone tissue from rapidly proliferating and regenerating epithelial tissues. Mainly two types of barrier membranes for bone regeneration (GTR) have been developed.

- i. Non-resorbable membranes, like polytetrafluoroethylene or titanium. They need a second surgery for removal.
- ii. Resorbable membranes can be natural or synthetic polymers. Natural collagen-based membranes are biocompatible but having an unpredictable degree of resorption.
- iii. Third generation of barrier membranes having an inherent delivery system of agents, such as, antibiotics, growth factors, adhesion factors etc. for accelerated wound healing.

- iv. Recently membranes that support bone formation and stabilize the implanted bone graft have been fabricated. Newly proposed biologically-active nanofibrous material, mimicking the native extracellular matrix might be a path to achieve the goal of “ideal” membrane.
- v. Barrier membranes should have properties such as biocompatibility, tissue integration, cell-occlusivity, clinical manageability and space-maintenance [13,14].

Cellular and molecular mechanisms of GBR

Bone regeneration after GBR follows a specific sequence of events. Within the first 24 hours the space is filled with the blood clot and releases growth factors and cytokines. The clot is replaced with granulation tissue. Nutrients and cells are transported through the newly formed blood vessels. These cells form osteoid.

Osteoid mineralization forms woven bone and this act as a template for the apposition of lamellar bone. This would result in formation of compact and reticular bone with mature bone marrow within 3 to 4 months after surgery [15].

Vertical Augmentation with GBR

Supracrestal or vertical bone augmentation presents one of the greatest challenges of bone regeneration in implant dentistry, due to the difficulty of the surgical procedure and its potential complications. Vertical augmentation aims to achieve bone regeneration in a direction without bony walls to support the stability of the bone graft. Bone regeneration and angiogenesis has to reach a distance from the existing bone, so that this is a biologically demanding procedure. The soft tissue has to be advanced to provide a closed healing environment. The application of GBR technique for supracrestal regeneration was introduced and described by Tinti and Parma-Benfenati in 1998 [16]. Complications such as membrane exposure and/or subsequent infection, with rates ranging between 12.5% and 17% have been reported [17].

Horizontal Augmentation with GBR

Guided bone regeneration has become a major treatment option to provide optimal bone support for implants. Knife-edge ridges, or Cawood and Howell Class IV edentulous jaw [18] with adequate height on the lingual/palatal side, and with insufficient width, present a unique problem for horizontal augmentation. Implant placement often impossible in these conditions. However, prognosis of GBR procedure is good for this condition as the residual ridge stabilizes the bone graft. Both non-resorbable and resorbable membranes can be used and bone grafts are placed under the barrier membrane to prevent collapse [19]. Autogenous bone blocks can often screwed onto the ridge for stability. Bone blocks (onlay bone graft) fixation may eliminate the use of a non-resorbable titanium reinforced membranes [20].

Procedure

The layered approach to GBR was developed by Misch in early 1990s,

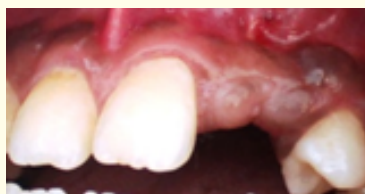

Figure 1a: Preoperative photograph.

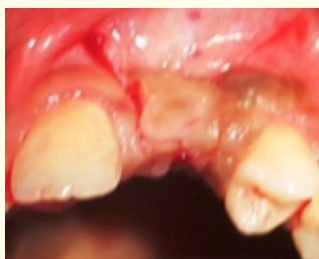

Figure 1b: Incision.

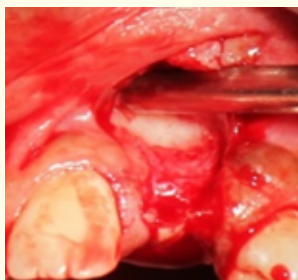

Figure 1c: After flap reflection

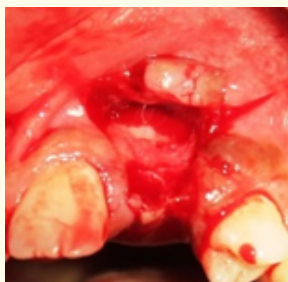

Figure 1d: After decortication.

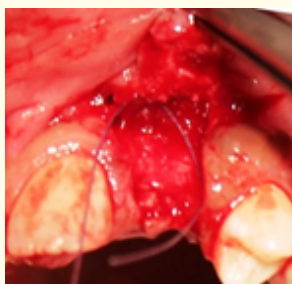

Figure 1e: Bone allograft placed.

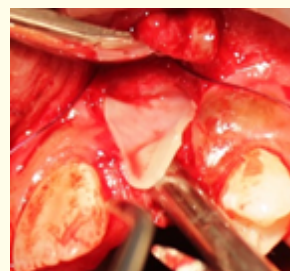


Figure 1f: Barrier membrane placed

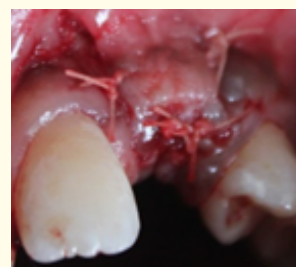

Figure 1g: Suturing

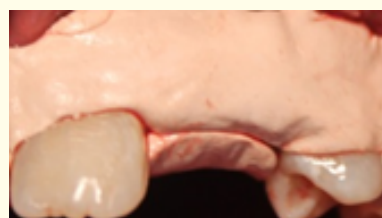

Figure 1h: Coepack placed.

1. The host bone
2. An autograft
3. A combination of DFDBA 30%, FDBA 70% and PRP
4. Barrier membrane and screw
5. Primary closure without tension.

Preparation of the recipient bed

To anesthetize the area, local anesthetic- 2%lidocaine with 1: 80,000 epinephrine should be used.

Incisions

Place horizontal incisions slightly lingual to mid crestal area and the interdental papilla should not be included. Keratinized tissue should be preserved on both sides. On the buccal surface, Vertical incisions to be made from the mesial and distal extent of the horizontal incision up to the mucogingival junction, buccally. A full thickness mucoperiosteal flap reflected.

Decortication

Cortical perforations should be made at the recipient site with a round bur at slow speed with copious saline irrigation, to open the marrow cavity as source of angiogenic and osteogenic cells. Due to bone inducing factor release this will result in bone formation.

Bone graft placement

Bone graft should be placed in the prepared recipient site after mixing with patients own blood or saline.

Placement of the membrane

GBR membrane should extend at least 3 mm beyond defect. The flap should be coronally advanced for wound closure without tension.

Suturing

Primary closure should be obtained using a resorbable suture material. Periodontal pack should be placed.

Post-operative instructions should be given. Patients should be given appropriate analgesics, antibiotics, and Chlorhexidine mouth rinses [21].

Complications Following GBR Procedure

Soft tissue complications are common during guided bone regeneration with a mean complication rate of 16.8%. Membrane exposure and acute infection are the most common complications. If not managed properly, this can result in infection of regeneration site and failure of GBR procedure [22].

Major complications include:

1. Secondary bleeding
2. fenestration/dehiscence
3. infection
4. leakage of graft particles
5. Collapse of the grafted site
6. membrane exposure

The most common complication associated with GBR procedure is premature exposure of the barrier membrane and necrosis of the overlying flap. Once exposed to the oral environment, the membrane becomes colonized with bacteria within 3 to 4 weeks [23]. Topical application of chlorhexidine to the exposed membrane has been advocated as a method of reducing the amount of bacteria, but it does not solve the problem and removal of the exposed membrane is often necessary [24].

Other complications associated with GBR procedures include soft tissue or bone graft infection, failure to regenerate adequate bone volume and mucogingival problems, including loss of keratinized tissue and decrease in the vestibule. Most of these complications are related to insufficient soft-tissue healing after tooth extraction, inadequate flap design, movement of the membrane and/or graft caused by transmucosal loading and improper provisional-

ization etc. Flap suturing under tension, poor surgical technique, contamination of the membrane or surgical site, compromise of the vascular supply and flap advancement for graft coverage that reduces the keratinized tissue and vestibular depth etc. may also lead to complications. More infections were found with the use of nonresorbable membranes [25-27].

Prevention of Complications

For the prevention of occurrence of complications, the biology of wound healing and the principles of guided bone regeneration should be respected [22,28].

Material-related factors

1. Graft and membrane should be biocompatible
2. Immunologically inert
3. Physiological stable
4. No risk of transmission of disease
5. Provide osteogenicity osteoinductivity and osteoconductivity
6. Absorbed after new bone formation

Surgical technique and patient-related factors

1. careful surgical and restorative procedures.
2. proper incision design and flap advancement
3. use of releasing incisions
4. bone decortication
5. stabilization of the graft and membrane
6. tension free primary closure of the flap
7. adequate provisionalization
8. avoidance of any transmucosal pressure
9. post-operative patient compliance
10. Compromising Blood Supply should be avoided

Blood supply

1. In order not to compromise the blood supply a vertical palatal incision should be avoided whenever possible.
2. The defect area is debrided of granulation tissue and cortical perforations are made to create a bleeding bed at the augmentation site to promote blood supply and egress of progenitor cells from the bone marrow.
3. Particulate graft material is placed, and a collagen membrane is trimmed and fitted 2 - 3 mm beyond the augmentation area.
4. Sutures are interspersed along the incision line so that the blood supply is not compromised.

Stabilization

1. If the membrane is stable with the above described suturing technique, then no attempt to affix a tack is needed. However, if the membrane is not stable then stabilization maybe achieved by using bone tacks.
2. Secondary bleeding is minimized upon stabilization of the graft site by tension free primary closure.

Undisturbed Healing

To protect the augmented site during healing and to provide esthetics and function, a provisional prosthesis can be used. At all times pressure on the area must be avoided and for that purpose fixed provisionalization is preferred by means of a resin bonded bridge, conventional resin bridge, or an Essix dental bridge.

Management [24,29]

Membrane exposure without flap necrosis

The surgical area should be irrigated with saline solution followed by irrigation with a diluted (1:1 with water) hydrogen peroxide solution to remove food debris and plaque. Patients should be instructed to use cotton tips impregnated with chlorhexidine solution to lightly swab the exposed membrane several times a day. If there are signs of infection (i.e. acute pain, swelling or fever), antibiotics should be prescribed. If the infection is not resolved or the membrane becomes fully exposed, removal of the membrane should be performed, the area irrigated, and loose graft particles removed. The flap should then be advanced and closed and if closure is not possible, a connective tissue graft may be used, placed over the exposed bone and sutured.

Dehiscence

The area should be irrigated with a saline solution followed by irrigation with a diluted (1:1 with water) hydrogen peroxide solution to remove food debris and plaque. If the flap readapts passively, it should be sutured to obtain primary closure. The wound borders should be de-epithelialized, removing internal epithelium from the flap to optimize the closure and to prevent trapping of epithelium under the flap. If tension free primary closure cannot be achieved, releasing incisions should be made before suturing. Suturing should be performed with 5 - 0 chromic gut sutures using a P-3 needle.

Infection

Early infection (0 - 4 weeks postoperatively)

The area should be irrigated several times with a saline solution followed by irrigation with a diluted (1:1 with water) hydrogen peroxide solution to remove food debris and plaque. The etiology should be determined and corrected. If the infection does not resolve, removal of the graft and membrane should be performed, the area debrided and irrigated, and the flap resutured.

Late infection (more than 4 weeks postoperatively)

The etiology (i.e. lack of patient compliance, mobility due to the pressure of the provisional prosthesis, or disturbance of the surgical site by food or trauma) should be determined and corrected. If the infection is localized, incision and drainage should be performed. Antibiotics should be prescribed for 7 - 10 days and if the infection does not resolve, surgery should be performed as for "Early infection".

Graft particle leakage

The area should be irrigated with a saline solution followed by irrigation with a diluted (1:1 with water) hydrogen peroxide solution to remove food debris and plaque. Remove excess material if the dehiscence is large, de-epithelialize the internal aspect of the soft tissue and resuture the flap. Prescribe chlorhexidine rinses 2 times a day for 2 - 3 weeks. Schedule weekly visits for the patient until flap closure is achieved.

Conclusion

GBR procedure allow regeneration of deficient alveolar ridges and implant placement in a prosthetically driven position with natural appearance and function. Though it is a predictable procedure for implant placement, complications may arise. Membrane exposure is the most common complication followed by infection of the grafted site. All of these complications are multifactorial in origin and they can lead to a reduced regenerative outcome. In order to prevent this careful surgical and restorative procedures need to be performed, so that we could reduce the prevalence of GBR complications and improve its clinical outcome. The predictable outcome depends on factors such as appropriate diagnosis and treatment planning, careful surgical procedures, postoperative instructions and follow-up, appropriate implant loading etc. All of these factors are important in achieving success of dental implants. Future developments in this field should be based on more effective techniques that predictably promote the body's natural ability to regenerate lost tissue.

Bibliography

1. Lekholm U., *et al.* "Marginal tissue reactions at osseointegrated titanium fixtures. (II) A cross-sectional retrospective study". *International Journal of Oral and Maxillofacial Surgery* 15.1 (1986): 53-61.
2. Gottlow J., *et al.* "New attachment formation as a result of controlled tissue regeneration". *Journal of Clinical Periodontology* 11.8 (1984): 494-503
3. Buser D., *et al.* "Guided Bone Regeneration in Implant Dentistry". *Chicago Quintessence* (1994).
4. Bassett CAL., *et al.* "Contributions of endosteum, cortex and soft tissues to osteogenesis". *Surgery, Gynecology and Obstetrics* 112 (1961): 145-152.
5. Boyne PJ and Mikels TE. "Restoration of alveolar ridges by intramandibular transposition osseous grafting". *Oral Surgery* 26.9 (1968): 569-576.
6. Nyman S., *et al.* "Bone regeneration adjacent to titanium dental implants using guided tissue regeneration: A report of two cases". *International Journal of Oral and Maxillofacial Implants* 5.1 (1990): 9-14.

7. Lazzara RJ. "Immediate implant placement into extraction sites: Surgical and restorative advantages". *International Journal of Periodontics and Restorative Dentistry* 9.5 (1989): 333-343.
8. Dahlin C., et al. "Generation of new bone around titanium implants using a membrane technique: an experimental study in rabbits". *International Journal of Oral and Maxillofacial Implants* 4.1 (1989): 19-25.
9. Becker W., et al. "The use of e-PTFE membranes for bone promotion around titanium implants placed into extraction sockets: a prospective multicenter study". *International Journal of Oral and Maxillofacial Implants* 9.1 (1994): 31-40.
10. Doug Sutherland., et al. "Grafts and Bone Graft Substitutes". Bone Regeneration and Repair: Biology and Clinical Applications.
11. Jie Liu and David G Kerns. "Mechanisms of Guided Bone Regeneration". *The Open Dentistry Journal* 8 (2014): 56-65.
12. Misch CE and Dietsch F. "Bone-grafting materials in implant dentistry". *Implant Dentistry* 2.3 (1993): 158-167.
13. Rakhmatia YD., et al. "Current barrier membranes: Titanium mesh and other membranes for guided bone regeneration in dental applications". *Journal of Prosthodontic Research* 57.1 (2013): 3-14.
14. Xiaohong Wang., et al. "Morphogenetically-Active Barrier Membrane for Guided Bone Regeneration, Based on Amorphous Polyphosphate". *Marine Drugs* 15.5 (2017): 142.
15. Elgali I., et al. "Guided bone regeneration: materials and biological mechanisms revisited". *European Journal of Oral Sciences* 125.5 (2017): 315-337.
16. Tinti Carlo and Stefano Parma-Benfenati. "Vertical ridge augmentation: Surgical protocol and retrospective evaluation of 48 consecutively inserted implants". *International Journal of Periodontics and Restorative Dentistry* 18.5 (1998): 435-443.
17. Simion Massimo., et al. "Vertical ridge augmentation using a membrane technique associated with osseointegrated implants". *International Journal of Periodontics and Restorative Dentistry* 14.6 (1994): 497-512.
18. Cawood JI and Howell RA. "A classification of the edentulous jaws". *International Journal of Oral and Maxillofacial Implants* 17.4 (1988): 232-236.
19. Lindhe J., et al. "Clinical periodontology and implant dentistry". Oxford, UK; Malden, MA: Blackwell, (2003).
20. Chiapasco M., et al. "Clinical outcome of autogenous bone blocks or guided bone regeneration with e-PTFE membranes for the reconstruction of narrow edentulous ridges". *Clinical Oral Implants Research* 10.4 (1999): 278-288.
21. Priya prabhakar and J Bhuvaneshwarri. "Guided Bone Regeneration - A Review". *Biomedical and Pharmacology Journal* 8 (2015): 365-368.
22. Lim G., et al. "Wound Healing Complications Following Guided Bone Regeneration for Ridge Augmentation: A Systematic Review and Meta-Analysis". *International Journal of Oral and Maxillofacial Implants* 33.1 (2018): 41-50.
23. Juhlin A., et al. "In vitro pre-clinical assessment of non-resorbable membranes for guided bone regeneration: bacterial and cellular response". *Clinical Oral Implants Research* 27 (2016).
24. Norbert Hassfurther. "Managing membrane complications". A technique description". *Letters on Implant Dentistry* 1 (2017): 59-61.
25. Trobos M., et al. "Bacterial colonization and fibroblast cyto-compatibility of dPTFE and ePTFE GBR membranes". *Clinical Oral Implants Research* 28.14 (2017): 55.
26. Hassfurther N and Hassfurther N. "Guided bone regeneration (GBR) using a Ti-reinforced non-resorbable PTFE membrane and simultaneous implant placement. A retrospective study". *Letters on Implant Dentistry* 1 (2017): 55-58.
27. Tolman DE. "Reconstructive procedures with endosseous implants in grafted bone: a review of the literature". *International Journal of Oral and Maxillofacial Implants* 10.3 (1995): 275-294.
28. Frank Peter Strietzel. "Risks and complications of membrane-guided bone regeneration. Retrospective Analysis". *Mund- Kiefer- und Gesichtschirurgie* 5.1(2001): 28-32.
29. S Annibali., et al. "Local Complications in Dental Implant Surgery: Prevention and Treatment". *Oral and Implantology* 1.1 (2008): 21-33.

Volume 2 Issue 6 June 2018

© All rights are reserved by Dhanya BN., et al.