



## Radiography Study of the Anatomic Position of the Mental Foramen in a Senegalese Population

**Mamadou Lamine Ndiaye<sup>1\*</sup>, Pape Abou Lecor<sup>2</sup>, Mamadou Diatta<sup>4</sup>, El Hadji Cyre Diop<sup>3</sup>, Mor Nguirane Diene<sup>3</sup>, Modou Makhfouse Diop<sup>1</sup> and Babacar Toure<sup>3</sup>**

<sup>1</sup>Department of Dento-Maxillofacial Radiology, Odontology, Faculty of Medicine (FMPO), University Cheikh Anta Diop of Dakar, Senegal

<sup>2</sup>Department of Oral Physiology, Faculty of Medicine, Pharmacy and Odontology (FMPO), University Cheikh Anta Diop of Dakar, Senegal

<sup>3</sup>Department of Conservative Odontology - Endodontics, Faculty of Medicine, Pharmacy and Odontology (FMPO), University Cheikh Anta Diop of Dakar, Senegal

<sup>4</sup>Departement of Oral Surgery, Faculty of Medicine, Pharmacy and Odontology (FMPO), University Cheikh Anta Diop of Dakar, Senegal

**\*Corresponding Author:** Mamadou Lamine Ndiaye, Department of Dento-Maxillofacial Radiology, Odontology, Faculty of Medicine (FMPO), University Cheikh Anta Diop of Dakar, Senegal.

**Received:** December 29, 2017; **Published:** January 29, 2018

### Abstract

The foramen mentonnier is a structure that is commonly encountered in various, maxillofacial surgery, oral, endodontic, implant surgery procedures. It is situated at an equal distance from the two edges of the mandible, on a vertical passing sometimes between the two premolars, sometimes by one or the other of these two teeth. However, variability on anatomy, individuals and ethnicity may be encountered. The aim of this study was to evaluate the anatomical topography of the mental foramen in a Senegalese population with digital panoramic radiography.

This is a cross-sectional study. She had taken a panoramic X-ray of Senegalese subjects. The topography of the mental foramen was assessed on X-ray, both horizontally and vertically.

The sample consisted of 121 panoramic X-rays. The mental foramen was visible in 77.3% (n = 187) on average. In the vertical direction, the apical position at the dental apex was the most frequent followed by the apical juxta position. The mental foramen was more closely aligned with the second premolar, 57.8% (n = 108), followed by second premolar-first molar and second premolar-first premolar intervals.

Indeed this study helps to know the topographic variability of the mental foramen in Senegalese subjects and to adopt standard benchmarks for anesthetic injection during dental care such as endodontics, surgery, implantology.

**Keywords:** Mandible; Radiography Panoramic; Mental Foramen; Anatomy

### Introduction

The foramen is located on the anterolateral aspect of the mandible, which marks the end of the mandibular canal [1]. The mental foramen is a structure that is commonly encountered in various plastic, maxillofacial, oral, endodontic, and implant surgery procedures [1]. The nerves and vessels that they transmit, provide the sensory innervation and vascularization of the soft tissues of the chin, the lower lip and the gum on the ipsilateral side of the mandible [2]. A good knowledge of its anatomical situation and its neurovascular bundle is important for local anesthesia during surgical procedures [2]. It is located equidistant from the two edges of the mandible, on a vertical passing sometimes between the two premolars, sometimes by one or the other of these two teeth [3]. A number of studies have shown a difference in the position of the foramen [4]. Panoramic X-ray generates a 2D (2D) image that is economical, easy to execute and interpret. The image quality of the panoramic X-ray can be increased by using the digital panoramic X-ray. Previous panoramic studies have reported that the anatomical position of the mental foramen may vary by ethnic group [4-6].

### Aim of the Study

The aim of this study was to evaluate the anatomical topography of the mental foramen in a Senegalese population with digital panoramic radiography.

### Materials and Methods

This was a descriptive study. She had been on a panoramic X-ray of patients referred to the IMODSEN modern imaging center in Dakar. Panoramic x-rays were prescribed by dental surgeons practicing in the city. The investigation was conducted from January 2017 to July 2017. X-rays were performed on a Soredex Cranex-DTM panoramic X-ray machine and read on a computer screen with the manufacturer's viewer. Patient consent was obtained to use their panoramic images for this study.

### Selection Criteria

On the panoramic radiographs, the first molars and the two mandibular premolars were to be present. X-rays in which the lower teeth (between the canines and the first molars) showed deep

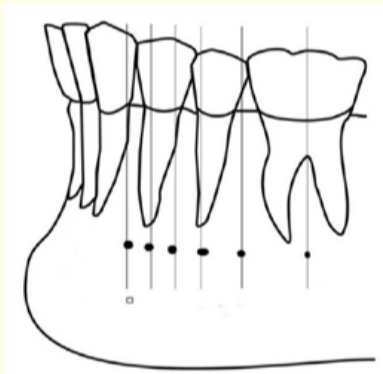
caries, root canal treatment, or various restorations were eliminated due to associated periapical radiolucency, as well as previous orthodontic treatments. X-rays in which the upper premolars were missing were also removed because of the possibility of an excessive eruption of the lower premolars which may hinder the position of the mental foramen in the vertical plane. X-rays were read by a dental surgeon specializing in dento-maxillofacial radiology.

**Collection of variables**

The topography of the mental foramen was assessed on X-ray, both horizontally and vertically. Visibility was identified as a radiolight image located in the chin area facing the apex of the mandibular premolars and first molar and following the path of the mandibular canal.

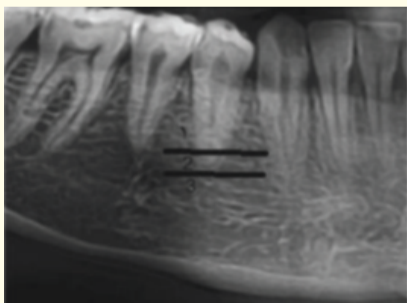
The position of the image of the mental foramen in the horizontal plane was evaluated according to the method of Al Jasser, *et al.* [7] as follows (Figure 1):

- Position 1: Located in front of the first premolar.
- Position 2: In line with the first premolar.
- Position 3: Between the first and second premolar.
- Position 4: In line with the second premolar.
- Position 5: Between the second premolar and the first molar.
- Position 6: In line with the first molar.



**Figure 1:** The position of mental foramen in the horizontal plane according to Al Jasser, *et al* [7].

The image position of the mental foramen in the vertical plane was recorded as follows according to the method of Fishel, *et al.* [8] (Figure 2):



**Figure 2:** The vertical position of mental foramen image.

- Type 1: Coronary at the apex.
- Type 2: Apical Juxta.
- Type 3: Apical at the apex.

**Statistical analysis**

The data was collected and processed on the SPSS 20.0 software. The statistical analysis of the data was descriptive. The results were expressed in percentage and in number. The chi-square test was used to look for an association between the variables. The threshold of significance was set at  $p < 0.05$ .

**Results and Discussion**

**Results**

Among all the digital panoramic radiographs examined, 121 were selected to explore the mental foramen. The mean age of the patients was  $32 \pm 23$  with a minimum age of 18 years and a maximum age of 73 years. The results showed a predominance of females with 58.7% ( $n = 71$ ) and men accounted for 41.3% ( $n = 50$ ) of the sample (Table 1). Over the entire sample, the mental foramen was visible in 77.3% ( $n = 187$ ) with a slight predominance on the left. However, it remained invisible in 22.7% ( $n = 55$ ) of the radiographs studied (Table 2), with no significant difference by sex ( $p > 0.05$ ). In the vertical direction type 3 (apical position at the apex) was the most met on the left 67.3% as on the right 76.4%. The coronal position at the dental apex was not observed in the sample studied. Position 4 (in line with the second premolar) was found in 57.8% of cases ( $n = 108$ ), followed by second premolar-first molar and second premolar-first premolar intervals (Table 3). The canine and distal positions at the first molar have not been observed.

	Right		Left		Total	
	n	%	n	%	n	%
Visible	89	73,6	98	81	187	77,3
Invisible	32	26,4	23	19	55	22,7
total	121	100	121	100	242	100

**Table 1:** Visibility of the mental foramen on panoramic radiographs.

	Right		Left		Total	
	n	%	n	%	n	%
Type 2	21	23,6	32	32,7	53	28,3
Type 3	68	76,4	66	67,3	134	71,7
Total	89	100	98	100	187	100

**Table 2:** Position of the mental foramen in the vertical direction.

	Right		Left		Total	
	n	%	n	%	n	%
Position 3	17	19,1	17	17,3	34	18,2
Position 4	51	57,3	57	58,2	108	57,8
Position 5	16	18	19	19,4	35	18,7
Position 6	5	5,6	5	5,1	10	5,3
Total	89	100	98	100	187	100

**Table 3:** Position of the mental foramen in the horizontal direction.

## Discussion

Accurate identification of mental foramen is important for diagnostic and clinical procedures. It has been reported that the mental foramen varied in position in the horizontal and vertical planes according to individuals. In this study, digital panoramic radiographs were used because they had some advantages over conventional panoramic and intraoral radiographs. They provided greater clarity of the mental foramen with less intra-observer difference in the calculations [9]. Peri apical radiographs may not reveal the position of the mental foramen if it is below the edge of the film [9]. Many studies have already delineated the location of these foramina in relation to bone and soft tissue markers. One of the bone markers previously used to locate the mental foramen is the lower teeth. There are no absolute anatomical landmarks for reference and the foramen cannot be visualized clinically or palpated. As a result, the reported anatomical position of the mental foramen has been variable [5,9-11]. However, most anatomy textbooks describe the location of the mental foramen below the top of the second premolar or between the tops of the first and second premolars. The possibility that the mental foramen occurs as far posterior to the tops of the first molar is of clinical importance since the foramen in this area may be incorrectly interpreted on radiography as peri apical pathology. In the literature, the mental foramen is closely associated with the lower second premolar and the space between the first and second premolar [12,13], but individual variations may exist. Although this is in agreement with the results of previous studies of some European populations, it completely ignores a mass of the most recent data and is therefore misleading. In this study, the horizontal position of the mental foramen was anywhere between the one preceding the first premolar to that of the mesiobuccal root of the first molar. This is in agreement with previous reports in the literature [1-14]. The most common position of the mental foramen was in line with the second premolar (57.4%). However, studies carried out in India on 582 panoramic views, in Iran on 100 subjects and in Morocco on 377 panoramic views, respectively located the foramen mentonnier in line with the 2nd PM in 61% of cases; 67% of cases and 62.7% of cases [5,9,10]. Nevertheless, this frequent position of the mental foramen can be found between the 1st and the 2nd PM in 63% of the cases according to a study carried out in Asia [6]. In the vertical direction, it was located in apical juxtae in 28.1% of cases and in 71.9% of cases, it was located apically in relation to the apex. The most popular method of identification of the mental foramen has been proposed by Fishel, *et al* [8]. They studied the vertical position and reported that in the first premolar zone of 936 patients, the foramen mentonnier was located coronary at the apex in 46.0% of cases. Sheikhi, *et al* [14] out of 180 subjects, the mental foramen was apical apex in 31.1%, followed by the apical juxta position 7.8% and the coronal position 2.2%.

## Conclusion

This study helps to know the topographic variability of the mental foramen in Senegalese subjects and to adopt standard benchmarks for anesthetic injection during dental care such as endodontics, surgery, implantology, etc. However, the variability of position of the mental foramen can justify anesthetic failures encounter at this level.

## Conflict of Interest

The authors declare no potential conflict of interests.

## Bibliography

- Gupta T. "Localization of important facial foramina encountered in maxillo-facial surgery". *Clinical Anatomy* 21.7 (2008): 633-640.
- Gungor K., *et al*. "A radiographic study of location of mental foramen in a selected Turkish population on panoramic radiograph". *Collegium Antropologicum* 30.4 (2006): 801-805.
- Bou Serhal C., *et al*. "Perioperative validation of localisation of the mental foramen". *DentoMaxilloFacial Radiology* 31.1 (2002): 39-43.
- Amorim MM., *et al*. "The mental foramen position in dentate and edentulous Brazilian's mandible". *International Journal of Morphology* 26.4 (2008): 981-987.
- Chkoura A and Wady W. "Position of the mental foramen in a Moroccan population: A radiographic study". *Imaging Science in Dentistry* 43.2 (2013): 71-75.
- Gada SK and Nagda SJ. "Assessment of Position and Bilateral Symmetry of Occurrence of Mental Foramen in Dentate Asian Population". *Journal of Clinical and Diagnostic Research* 8.2 (2014): 203-205.
- Al Jasser NM and Nwoku AL. "Radiographic study of mental foramen in a selected Saudi Population". *DentoMaxilloFacial Radiology* 27.6 (1998): 341-343.
- Fishel D., *et al*. "Roentgenologic study of the mental foramen". *Oral Surgery, Oral Medicine, Oral Pathology, Oral Radiology, and Endodontics* 41.5 (1976): 682-686.
- Parnami P., *et al*. "Assessment of the Horizontal and Vertical Position of Mental Foramen in Indian Population in Terms of Age and Sex in Dentate Subjects by Panoramic Radiographs: A Retrospective Study with Review of Literature". *Open Dentistry Journal* 9 (2015): 297-302.
- Afkhami F., *et al*. "Radiographic Localization of the Mental Foramen and Mandibular Canal". *Journal of Dentistry* 10.5 (2013): 436-442.
- Verma P., *et al*. "Correlation of Radiographic Mental Foramen Position and Occlusion in Three Different Indian Populations". *West Indian Medical Journal* 64.3 (2015): 269-274.
- Currie CC., *et al*. "Determination of the mental foramen position in dental radiographs in 18-30 year olds". *DentoMaxilloFacial Radiology* 45.1 (2016): 20150195.
- Lumnije K., *et al*. "Position of the mental foramen: an anatomical study". *Collegium Antropologicum* 161.9-10 (2011): 272-273.
- Sheikhi M., *et al*. "Cone-Beam Computed Tomography Evaluation of Mental Foramen Variations: A Preliminary Study". *Radiology Research and Practice* (2015).

Volume 2 Issue 2 February 2018

© All rights are reserved by Mamadou Lamine Ndiaye, *et al*.