

## Root Resorption: Challenge to the Endodontist

Onkar Singh<sup>1\*</sup>, Dakshita Joy Sinha<sup>2</sup>, Shashi Prabha Tyagi<sup>3</sup> and Nimish Tyagi<sup>1</sup>

<sup>1</sup>PG Student, Department of Conservative Dentistry and Endodontics, Kothiwal Dental College Research Centre and Hospital, India

<sup>2</sup>Associate Professor, Department of Conservative Dentistry and Endodontics, Kothiwal Dental College Research Centre and Hospital, India

<sup>3</sup>Professor and HOD, Department of Conservative Dentistry and Endodontics, Kothiwal Dental College Research Centre and Hospital, India

**\*Corresponding Author:** Onkar Singh, PG Student, Department of Conservative Dentistry and Endodontics, Kothiwal Dental College Research Centre and Hospital, India.

**Received:** May 26, 2017; **Published:** June 24, 2017

### Abstract

Resorption is a pathologic process that often eludes the clinician with its varied etiologic factors and diverse clinical presentations. The cells involved in tooth resorption are odontoclasts which are multinucleated cells. Resorption can be classified as internal and external resorption. Internal resorption has been described as a rare occurrence as compared to external resorption. This review article describes the pathogenesis of tooth resorption and various forms of internal and external resorption. Early diagnosis is important in the successful management of resorptive lesions.

**Keywords:** External Resorption; Internal Resorption; Mineral Trioxide Aggregate; Osteoclasts

### Introduction

Resorption is defined as a condition associated with either a physiologic or a pathologic process resulting in loss of dentin, cementum or bone [1].

Physiological resorption is mainly seen in deciduous dentition, resulting in variable tooth mobility before exfoliation of the primary teeth and allows eruption of their permanent teeth [2].

The process of resorption in permanent dentition is usually pathological and may occur due to traumatic injuries, orthodontic tooth movement, or chronic infections of the pulp or periodontal structures, neoplastic processes associated with systemic diseases and lesions idiopathic origin. If pathologic resorption is untreated it will result in the premature loss of the teeth [1,2].

Classifications play an important role for the clinician in the process of diagnosis and treatment planning. According to Andraesen tooth resorption into internal (inflammatory and replacement) and external (surface, inflammatory, replacement) [3].

Root resorption may be classified on the basis of its location in relation to the root surface: Internal or external. Internal re-

sorption may be classified as internal inflammatory resorption and internal replacement resorption. External resorption is further classified into external surface resorption, external inflammatory resorption, external cervical resorption and transient apical breakdown [4].

The consequences of root resorption may range from slight tooth mobility due to small amount of root loss to complete loss of tooth due to excessive amounts of resorption. On radiographic evaluation, resorption may appear as either an apical root blunting, lateral root resorption or in rare cases excessive root loss. External resorption leads to the loss of cementum, dentin and bone. It may take place in vital as well as in non-vital teeth and is identified during routine radiographic or clinical examination, as majority of the cases are asymptomatic [5]. The treatment for the external apical root resorption is to remove or destroy microorganism which leads to healing of the periradicular space [6].

Two phases are required for the etiology of different types of root resorption, i.e. mechanical or chemical injury to the protective tissues and stimulation by infection or pressure [7,8].

The proposed treatment regimen for root resorption is the use of calcium hydroxide as an intracanal medicament. The use of calcium hydroxide has been widely accepted but the concerns regarding

weakening of roots leading to increased susceptibility to fracture have been raised. Moreover, this demands patient compliance for repeated dressings [9-11].

Due to the drawbacks of calcium hydroxide different materials have been used for the management of root resorptions. They are, a) Mineral Trioxide Aggregate (MTA) b) Glass Ionomer cement, c) Super ethoxy benzoic acid (a reinforced zinc oxide cement; its liquid contains 32% eugenol and 68% ethoxy benzoic acid) d) Hydrophilic plastic polymer (2-hydroxyethyl methacrylate with barium salts) e) Zinc oxide eugenol and zinc acetate cement f) Amalgam alloy and g) Thermo plasticized gutta-percha administered either by injection or condensation techniques, etc [12].

Dental resorption is a challenge to dentistry due to its organic complexity. The concern and curiosity for this subject is not recent. In order to comprehend this process, it is necessary to study the formation and degradation of hard tissue as well as the cells involved in it. Each type of resorption presents clinical features as well as histological aspects. Therefore, the dentist should be aware of these characteristics in order to perform an early diagnosis and appropriate treatment, thus minimizing the sequelae related to this problem. Moreover, in primary dentition, differential diagnosis between physiological and pathological resorption is important so as to avoid over treatment.

This review is to make the dental fraternity aware about the characteristics, clinical features, radiographic findings, histological details of root resorption so that the dentist is able to perform an early diagnosis and render appropriate treatment to the patient while minimizing the unwanted sequelae related to this condition.

### Historical Background and Etiology

The oldest report about resorption was described by Michael Blum in 1530, probably the first book about the science and art of dental surgery [13]. Internal root resorption has been reported as early as 1830 [14]. The external resorption of roots has perplexed the orthodontic specialty since the early reports of Ottolengui in 1914. External apical root resorption was found to be associated with orthodontic treatment all the way back to the early 1900s. Albert Ketcham was the first to bring the message that apical root resorption is a common and occasionally severe iatrogenic consequence of orthodontic treatment. This root resorption differs from other kinds of resorption. This is a sterile,

local inflammatory process, which is complicated and has all characteristic inflammatory symptoms [15].

In 1983, Taylor and Peterson reported on atypical root resorption of the maxillary primary incisors and distinguished it from normal root resorption because of a distinct peripheral circumferential resorptive pattern and stated that digit sucking appears to contribute to the development of atypical resorption of the maxillary primary central incisors [16]. Massler and Perreault have reported that resorption of teeth in Indians are found five times more often than in the United States. Females present higher incidence of root resorption than males. Root resorption in presence of periodontal diseases are found 3 times more often than in involved teeth [17,18]. The etiology of root resorption is usually biphasic requiring injury and stimulation [7,8]. The initiation of the resorption process is carried out by multinucleated cells colonizing the denuded mineralized tissue. However, without further stimulation of the resorption cells, the process will end spontaneously. If the damaged root surface is large, bone cells will be able to attach to the root before the cementum producing cells resulting in ankylosis. Infection or pressure are the common stimulation factors of osteoclastic cells which results in continuation of active resorption process. Trauma and inflammation are considered to be the possible causative factors for internal resorption even though internal resorption is commonly termed to be idiopathic. Resorption process can develop by shifting of pH value to acidic for example in irreversible pulpitis, so that the dentin and enamel surfaces are dissolved by chelation. Cases of internal root resorption can progress into external and vice versa and may result in the fracture of the root [19].

### Pathogenesis and Requirements for the Presence of Resorption

Osteoclasts the multinucleated giant cells are responsible for the bone resorption. They are formed by the fusion of mononuclear precursor cells that arrive at the resorption site through the blood stream [20,21]. Their differentiation is under the control of factors produced by bone marrow stromal cells or are found on the mature osteoblast. Two such factors are RANK (receptor activator of nuclear factor kappa B) ligand (RANKL) and osteoprotegerin (OPG). The receptor of RANKL is RANK and is localized on the surface of the progenitor osteoclast. Therefore, physical contact between the osteoblast or stromal cells and the progenitor osteoclast is essential for a direct interaction of RANKL and RANK for osteoclast formation and activation [21]. OPG acts as a decoy receptor that can bind to RANKL and interferes with its ability to bind to RANK receptors, thus inhibiting osteoclast formation. Thus, both RANKL and OPG play an important role in osteoclastogenesis [22].

The resorption process occurs in two stages: Degradation of the inorganic mineral structure followed by disintegration of the organic matrix. Degradation of the inorganic crystal structure is brought about by enzymes like acid phosphatase and carbonic anhydrase II present in the osteoclasts.

In order for root resorption to occur, two things must happen:

1. The loss or alteration of the protective layer (pre-cementum or pre-dentin) and
2. Inflammation must occur to the unprotected root surface [23].

Classifications of Resorption A) Inflammatory Resorption [24]; B) Trauma Induced Resorption [19]; C) Hyperplastic Invasive Tooth Resorption [19]; D) Infection Induced Tooth Resorption [19]; E) Root Resorption (Figure 1)

### Diagnosis

Various diagnostic tools used for detection of internal resorption are:

- Visual examination based on changed colour in tooth crown
- Radiographic diagnosis
- Conventional and cone beam computed tomography
- Light microscopy
- Electron microscopy

### Vitality Testing

Internal root resorption usually occurs in teeth with vital pulps and gives a positive response to sensitivity testing. However, in teeth that exhibit internal root resorption, it is not uncommon to register a negative response to sensitivity testing, as the coronal pulp has often been removed or is necrotic and the active resorbing cells are more apical in the canal. Also, the pulp might have become necrotic after active resorption has taken place [23].

### Treatment

This resorptive defect is the result of the inflamed pulp and the blood supply to the tissue is through the apical foramina, the correct approach to treatment is endodontic treatment that effectively removes the blood supply to the resorbing cells. After adequate anesthesia has been administered, the canal apical to the internal defect is explored and a working length short of the radiographic apex is used. The apical canal is thoroughly instrumented to ensure that the blood supply to the tissue resorbing the root is cut off. By the completion of the root canal instrumentation it should be possible to obtain a blood free and dry canal with paper points. Calcium hydroxide is then spun into the canal to facilitate the removal of the tissue in the irregular defect at the next visit. At the second visit, the tooth and defect are filled using a soft gutta-percha technique. In rare cases where extremely large internal resorptive defects are found in the apical part of the canal, it is possible to surgically remove the defective root and place an endodontic implant in order to maintain stability of the tooth. With modern dental techniques, this treatment alternative should be weighed against the advantages of implant dentistry [23] (Table 1).

### External Root Resorption

External root resorption defines (ERR) as irreversible processes lyses in cement or cement-dentinal started to root surface of the teeth. This process appears in both teeth, with and without vitality, and the diagnosis is incidentally statutes on radiographs and clinical examination, although mostly are asymptomatic resorption [26]. It is initiated on the outer surface of the tooth by osteoclasts that re-

### Internal Root Resorption

Internal root resorption has been described as a resorptive defect of the internal aspect of the root following necrosis of odontoblasts as a result of chronic inflammation and bacterial invasion of the pulp tissue [25]. Two types of internal root resorption were described by Ne., *et al.* and Heithersay: Internal inflammatory resorption and internal replacement resorption [3,20].

Internal Inflammatory Root Resorption	Internal Replacement Root Resorption
<ul style="list-style-type: none"><li>• It involves a progressive loss of intraradicular dentin without adjunctive deposition of hard tissue adjacent to the resorptive sites.</li><li>• The coronal pulp is usually necrotic, whereas the apical pulp must remain vital.</li><li>• One hypothesis suggest that the necrotic coronal part of the infected pulp provides a stimulus for inflammation in the apical part of the pulp.</li><li>• Second hypothesis is based on the recent understanding that osteocytes participate in bone homeostasis by inhibiting osteoclastogenesis.</li><li>• The symptoms of acute or chronic apical periodontitis may be seen after the entire pulp has undergone necrosis and the pulp space has become infected.</li><li>• Radiographically, appearance of an oval-shaped enlargement is seen within the pulp chamber.</li><li>• Histologically presents as granulation tissue with multinucleated giant cells.</li></ul>	<ul style="list-style-type: none"><li>• It is characterized by an irregular radiographic enlargement of the pulp chamber, with discontinuity of the normal canal space, obliterated by a fuzzy appearing material of mild to moderate radio density.</li><li>• Appears to be caused by low grade inflammatory process of the pulpal tissue such as chronic irreversible pulpitis or partial necrosis.</li><li>• One hypothesis suggests that the metaplastic tissues are produced by postnatal dental pulp stem cells present in the apical, vital part of the root canal as a reparative response to the resorptive insult.</li><li>• Second hypothesis proposes that both the granulation tissues and metaplastic hard tissues are derived from the vascular compartments or originated from the periodontium.</li><li>• This form of resorption is typically asymptomatic, and the affected teeth might respond normally to thermal or electric pulp testing unless the resorptive process results in crown or root perforation.</li><li>• Radiographically, the enlarged canal space is obliterated by a fuzzy appearance material of mild to moderate radiodensity.</li><li>• Histologically, resorption of the intraradicular dentin is accompanied by subsequent deposition of a metaplastic hard tissue that resembles bone or cementum instead of dentin.</li></ul>

**Table 1:** Differences between internal inflammatory and internal replacement resorptions.

sorb the cementum and dentin and in some cases the pulp. A variety of local factors have been suggested as initiating external resorption, including impacted teeth, excessive mechanical force applied during orthodontic treatment, tumors and cysts, luxated or reimplanted teeth, periradicular inflammatory lesions, periodontal disease and tooth bleaching. Systematic disturbances such as hypoparathyroidism, hyperparathyroidism, calcinosis, Turner’s syndrome, Gaucher’ s disease and Paget’s disease have also been suggested as causative factors in connection with external root resorption [27].

External resorption is further classified into external surface resorption, external inflammatory resorption, external cervical resorption and transient apical resorption (Table 2).

**Diagnosis of Internal Root Resorption and External Root Resorption (Figures 2 and 3)**

Cone beam computed tomography (CBCT) is an innovative tech-

nology that offers the clinician clinically relevant information that cannot be gathered from conventional radiography. Classically, Gartner., *et al.* [39] described the radiographic features of internal and external resorption. Off-angle radiographs have proven to be useful in differentiating these entities. The use of parallel radiographic techniques is advocated for differentiating internal from external resorption defects. A second radiograph taken at a different angle often confirms the nature of the resorptive lesion. External RRs will move in the same direction as the x-ray tube shift if they are lingually/palatally positioned. Conversely, they will move in the opposite direction to the tube shift if they are buccally positioned. Internal RRs should remain in the same position relative to the canal in both radiographs. Radiologically, internal RRs present as a cloudy, mottled, radiopaque lesion with irregular margins as a result of the presence of metaplastic hard tissue deposits within the canal space. Differentiating internal RR from external RRs might be clinically challenging, especially if the metaplasia has occupied the entire resorptive cavity.

Feature	External surface resorption	External inflammatory resorption	External cervical resorption	Transient Apical Resorption
Etiology	Traumatic lesions of low intensity in tooth's supporting tissues, e.g. subluxation and concussion.	Traumatic lesions of great intensity localized in tooth's support tissues, e.g., lateral luxation, intrusion and avulsion	The etiology of ECR remains unclear. However, several predisposing factors have been reported e.g. trauma, orthodontic treatment, periodontal treatment, dento-alveolar surgery, intracoronar bleaching, playing wind instruments, familial pattern and possible genetic predisposition, and idiopathic causes [29].	Apical resorption may result from necrosis and infection of the pulp and is enhanced by substances released from inflammatory cells in the surrounding tissues, such as osteoclast activating factor, macrophage chemotactic factor, and prostaglandins [28].
Clinical Features	On clinical examination; no indicative sign of resorption [30].	The tooth does not respond to vitality tests. Tooth crown color can be altered to grey. Tooth can present pain to vertical or horizontal percussion [30].	Located in cervical region of tooth. Pink spot might be noted by the patient or dentist. The tooth usually responds positively to vitality tests unless the residual pulpal involvement [in very advanced cases]. Spontaneous and profuse bleeding on probing is seen. The tooth shows sharp, thinned out edges.	History of trauma or colour change in a tooth or teeth.
Mechanism of action	Macrophages possess large numbers of heterogeneous dense cytoplasmic granules that contain acid hydrolases, capable of digesting tissue debris and foreign matter. When there are only minor inflammatory changes, new PDL and cementum begin to form on the external root surface as early as 1 week after the injury [31,32]. This type of limited resorption occurs with any injury to the PDL or cementum and is referred to as surface or transient resorption [33,34].	In more severe cases of trauma, or in cases in which the resultant inflammatory response is more intense, the damage to the cementum progresses to involve resorption of the intermediate cementum layer that caps the ends of the dentinal tubules. The dentinal tubules are then open and communicate with inflammatory resorptive cells [macrophages and osteoclasts] within the PDL and alveolar bone. If allowed to progress, the resorptive process may destroy the root and adjacent alveolar bone [28].	Intracoronar bleaching leads to fall in pH to about 6.5 which causes enhanced osteoclastic activity thereby leading to external cervical resorption [1].  Dental trauma may lead to intrusion of the primary incisors and cause developmental defects in the cervical region on the unerupted permanent successors. Excessive orthodontic forces at the cervical region of the tooth might result in tissue necrosis adjacent to exposed root dentin. Surgical procedures may result in damage to the cemento-enamel junction. Unexpectedly, periodontal debridement that might inadvertently result in damage/removal of the cementum may contribute to external cervical resorption [1].	Probably affects all teeth undergoing periradicular apical periodontitis; some studies have demonstrated that it is related to the presence of bacteria in the canal. In long-standing cases, there may be large areas of periapical bone resorption, but without much apically resorbed root dentin. This is in contrast to the quickly developing inflammatory resorption seen in traumatic injuries in which the dentinal tubules are patent and open to an infected pulp.

Radio-graphic features	Normal lamina dura is observed [30].	A radiolucency is seen at the periapical area associated with root resorption. Concerning to its localization, it can be classified as apical, lateral, or cervical [30].	Detected as a chance because tooth is usually asymptomatic. It varies from asymmetrically located radiolucency with irregular margin since cervical/proximal region of tooth to uniformly round radiolucency centered over the root. Early lesions are usually radiolucent in appearance. Advanced lesions might have mottled appearance because of fibroosseous nature of the lesion. Root canal should be visible and intact [indicating lesion is external] [1].	Usually not visible on radiographs because of the small size. A widening of periodontal ligament space and blunting of apices may be seen [4].
Histo-logic Features	Resorption cavities are seen reaching cementum and dentin, as well as the presence of multinucleated giant cells so-called osteoclasts.	Saucer-shape resorptive areas are observed, involving both cementum and dentin; also, inflammation of adjacent periodontal ligament and bone resorption occurs. It may quickly occur in young teeth because dentinal tubules are larger and allow that irritants move freely through root's external surface [35].	Is similar to external inflammatory resorption; the resorptive cavity in ECR lesions consists of granulomatous tissue. Osteoclasts might be observed on the resorbing front within the lacunae. The predentin and innermost layer of dentin prevent the ECR lesion from involving the pulp, which remains healthy until the ECR has become very advanced.	No noticeable histological features. Some resorptive changes may be noticed which are reversible.
Treatment	No treatment is necessary as the repair is spontaneous [30].	Calcium hydroxide $[Ca(OH)_2]$ is often considered the intra-canal dressing of choice. Because of high pH and antibacterial properties, its use has been suggested to promote healing. Recommendations vary considerably as to the length of treatment time with $Ca(OH)_2$ before obturation [28]. Studies [36,37] recommend a 1 or 2 week. Furthermore, it is suggested that longer treatment with $[Ca(OH)_2]$ is beneficial when there has been a delay in pulp removal or when inflammatory resorption is detected.	The aim of the treatment is the inactivation of all active resorbing tissue, and the reconstitution of the resorptive defect either by the placement of a suitable filling material or by the use of biological systems such as membranes, so that the tooth may be healthily and aesthetically retained. The nonsurgical treatment involved the topical application of a 90% aqueous solution of trichloroacetic acid to the resorptive tissue, curettage, endodontic treatment where necessary, and restoration with glass-ionomer cement. Adjunctive orthodontic extrusion has been also employed in some advanced lesions. Surgical treatment of varying degrees of ICR has generally involved periodontal flap reflection, curettage, restoration of the defect with amalgam, composite resin, glass-ionomer cement and repositioning the flap to its original position [38].	Proper debridement and obturation will arrest this type of inflammatory resorption and lead to both cemental and osseous repair [7].

**Table 2:** Comparison in various types of external root resorption.



Differential Diagnosis between Internal Root Resorption and External Root Resorption (Table 3) [19,28,40,41]

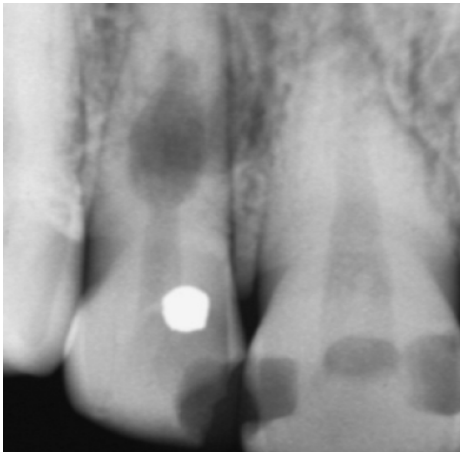

Internal Root Resorption	External Root Resorption
<ul style="list-style-type: none"><li>• Pinkish hue if resorptive process reaches cervical area.</li><li>• Internal replacement resorption is relatively rare and may appear clinically as a pink area in the crown.</li><li>• Pulp test usually normal.</li></ul> <p>Radiographically:</p> <ul style="list-style-type: none"><li>• The margins are smooth and clearly defined. The walls of root canal system may appear to be balloon out.</li><li>• The pulp chamber and the canal cannot be followed through out the lesion.</li><li>• Their distribution of the pulp canal is symmetrical but can be eccentric.</li><li>• The radiolucency is of uniform density.</li><li>• Lesion is within the confine of root canal on angled radiographs.</li></ul> 	<ul style="list-style-type: none"><li>• Resorption of coronal dentin and enamel often creates a clinically obvious pinkish color in the tooth crown as highly vascular resorptive tissue becomes visible through thin residual enamel</li><li>• When tooth structure is replaced with bone that fuses with dentin, it is termed replacement resorption or ankylosis.</li><li>• Pulp test usually normal.</li></ul> <p>Radiographically:</p> <ul style="list-style-type: none"><li>• The border will be irregular and ill defined.</li><li>• If the lesion is superimposed on the root canal system, it should be possible to follow the canal walls unaltered through the area of defect.</li><li>• Their distribution is not symmetrical and can occur on any root surface.</li><li>• There may be variations in the radiodensity of the body of lesion.</li><li>• Lesion shift on changing angulations.</li></ul> 

Table3: Differential Diagnosis between Internal Root Resorption & External Root Resorption.

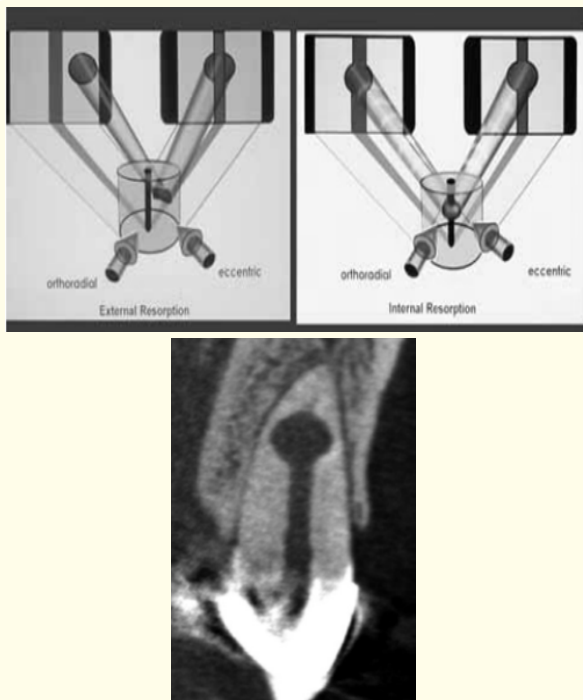
Management of Root Resorption

Effective treatment for root resorption is highly dependent on identification of type of resorption and its stimulating factor. The prognosis is good unless the lesions are perforating, which may need extraction due to poor prognosis.

Non-Surgical Management

Nonsurgical root canal therapy is the treatment of choice to arrest the destructive process. Thorough debridement and obtu-

ration of the irregular resorptive cavity is a challenging task. Mineral trioxide aggregate (MTA) has been widely used for the treatment of root perforations. It has a good sealing ability, induces osteogenesis and cementogenesis, and is highly biocompatible. Bio dentine, a contemporary tri- calcium silicate-based dentin replacement material like MTA, has been evaluated for various physical and biologic properties. It offers advantages over MTA like a faster setting time and higher push-out bond strength at 24 hours [42].



**Figure 2 and 3:** Radiographic diagnosis of internal and external resorptions.

### Surgical Management

The surgical approach includes for the management of root resorption includes various steps.

### Access Preparation

Access preparation has 2 parts: Soft tissue access and Hard tissue access.

### Soft Tissue Access

The basic soft tissue access window for all kinds of root defects is similar, with slight variations depending upon the anatomic structures (frenal and muscle attachments, width of attached gingiva, bone eminence and papillary height and width), size and position of the defect itself, state of coronal tooth structure, nature and extent of coronal restoration and aesthetics.

Vertical and horizontal incisions are used to achieve the full and limited mucoperiosteal flap. Blade No. #15C can be used for giving incisions.

### Horizontal Incisions

- i) Intrasulcular incision involving the dental papillae, if the defect is close to the marginal tissues, mostly indicated in

lower anterior and posterior region.

- ii) Sub marginal flap (Oschenbein Lubke Flap): Incision placed 2 mm from the depth of gingival sulcus, and indicated in esthetically sensitive regions like upper anterior.

The horizontal incision is normally extended to one sound tooth on both sides of the involved tooth.

### Vertical Incisions

2 Full mucoperiosteal flaps can be designed depending upon the number of vertical releasing incisions. Triangular with one vertical releasing incision, rectangular with two releasing incisions.

Currently, vertical releasing incisions along the blood vessel alignment are indicated over the angled releasing incisions, as it severs less blood vessels, prevents ischemia, and provides adequate access to surgical site, and allows nearly scar free healing.

### Tissue Elevation and Reflection

In both the intrasulcular incision and subgingival flap, whole of the mucoperiosteal complex should be elevated and reflected so as to minimize hemorrhage during the procedure. The main objective of the tissue reflection and retraction is to provide adequate access for the management of damaged radicular defects, provide clear view of the bony surgical site and prevent further soft tissue trauma.

If the defects are located on the cervical or mid root region as in the cases of external cervical root resorption, or perforations, then horizontal incision should be intrasulcular.

### Hard Tissue Access and Management

Following things should be considered during the hard tissue management. Firstly, if the root defect is not directly accessible after soft tissue reflection, removal of the healthy bony tissue is required to gain access. It is then followed by periradicular curettage if granulation tissues are present. Then, a dry working field is created by using various hemostatic agents.

### Hard Tissue Management in External Root Resorption

Hard tissue management of external root resorption depends upon the type of the external root resorption. External root resorption occurring on the apical 1/3<sup>rd</sup>, then conventional apical surgical method can be followed. But, as the length of the root is already reduced due to the resorption, resecting 3 mm is not required. Hence, resecting less than 3 mm or sometimes only planning the root end surface is sufficient and then preparing a cavity, retro filling the prepared cavity and repositioning the flap is done.



In cases of cervical inflammatory resorption, surgical treatment varies with the depth of the lesion. If the defect are smaller in size and does not involve the pulp, it can be treated by curetting the granulomatous tissue from the adjacent periodontium to sever the blood supply to the resorbing cells. Several different types of burs can be used for removing the resorptive tissue. The root defect can then be restored with flowable composite resins or glass ionomer cements. But if the resorptive defect is in close proximity to the pulp or already exposed but were only diagnosed after the flap reflection, then endodontic treatment should be carried out before external repair of the external cervical resorption. Performing the root canal treatment through the existing defect if possible can be attempted to prevent further destruction of the tooth structure. If it is difficult to attempt the endodontic treatment from the defect region, then the tooth can be first restored at the defect and endodontic treatment can be completed subsequently through conventional access cavity preparation [43].

#### Different Materials Available

- Mineral trioxide aggregate (MTA)
- Glass ionomer cement
- Super EBA (Ethoxy Benzoic Acid)
- Hydrophilic plastic polymer (2-hydroxyethyl methacrylate with barium salts)
- Zinc oxide eugenol and zinc acetate cement
- Amalgam alloy
- Thermoplastic zed gutta-percha administered either by injection or condensation techniques [23].
- More recently Bio dentin.

#### Guided Tissue Regeneration

Guided tissue regeneration techniques are based upon controlling the epithelial proliferation by allowing a barrier material between the gingival tissue and the exposed root surface and supporting alveolar bone. This prevents the colonization of exposed root surfaces by gingival cells and proliferation of periodontal ligament cells over the exposed root surfaces, thus preventing formation of deep pockets. Barriers can be grouped into 2 broad categories as resorbable and non-resorbable membranes. Resorbable membranes are more suitable for endodontic surgery as it does not need 2<sup>nd</sup> surgery for its removal e.g. Bio-Gide (Geistlich, Switzerland). However, these membranes also require a support so that it doesn't collapse into the defect itself. Hence, either a titanium-tented material or graft can be

used for the support. Also, artificial bone can be placed into the bony cavity to enhance rapid bone regeneration e.g. Bio-Oss

#### Closure of the Surgical Site

Before wound closure, careful examination of the surgical site should be done for presence of any foreign materials. If possible radiographic examination should be also taken prior to the wound closure. Irrigation with sterile saline or water can be done to remove the foreign debris. The flap is then repositioned and sutures placed. Suture materials often used are thinner monofilament with smaller needles of size 5-0 and 6-0.

Interrupted or sling sutures can be placed according to the need. In interrupted sutures, the corners are first sutured to provide maximum ease while suturing. After the suturing is complete, post-surgical pack is placed if required and sterile, chilled, moistened gauze can be placed over the flap, and pressure applied for 5 minutes. The patient is then instructed to hold the ice pack around the surgical site of the face-on for next 20 minutes and off for the next 20 minutes - and continue to do for the next 24 hours.

#### Periodic Follow-Ups

With the use of monofilament sutures of size 5-0 and 6-0, first follow up can be done after 72 hours for suture removal. This is enough time for reattachment to take place and suture removal becomes easy and painless. After 72 hours, the mucosal tissue tends to grow over the suture material making the suture removal procedure painful and inconvenient. After suture removal, periodic follow up can be done at a period of 3 months, 6 months, 1 year and so on for the evaluation of the tooth [43].

#### Future Perspective and Conclusion

Identification of root resorption in clinical practice requires detailed past medical history, information of tooth involved, previous endodontic treatment, and associated diseases. Lesions that are perforating in nature are more difficult to manage than non-perforating lesions and may even necessitate extraction due to poor prognosis. Early diagnosis is the key to a better prognosis. Considering time to be a crucial factor, this paper helps clinician with diagnosing and treatment planning of pathological root resorption. With the advent of newer technologies like CBCT, Light microscopy and Electron microscopy; the early detection of resorptive lesion has been made easier; newer biomaterials like MTA, Bio dentin, Calcium Enriched Mixture etc. have made the management of the resorptive defects simpler. The endodontic treatment is irrelevant if the resorption is not eliminated, at the restorative aspects are not managed properly. Proper manage-

ment requires knowledge and skills in endodontics, surgery and restorative dentistry. Resorption in advanced stages may pose great challenges for the clinicians. Thereby highlighting the importance of correct type of resorption, early diagnosis, adequate management with most appropriate material may lead successful outcome of the resorptive defect.

## Bibliography

1. Patel S., et al. "External Cervical Resorption: A Review". *Journal of Endodontics* 35.5 (2009): 616-625.
2. Armas JM., et al. "External apical root resorption: two case reports". *International Endodontic Journal* 41.11 (2008): 997-1004.
3. Heithersay GS. "Management of tooth resorption". *Australian Dental Journal* 52 (2007): S105-S21.
4. Fernandes M., et al. "Tooth resorption part 1-pathogenesis and case series of internal resorption. *Journal of Conservative Dentistry* 16.1 (2013): 4-8.
5. Adaki RV., et al. "External Apical Root Resorption- An Unusual Case report". *IOSR Journal of Dental and Medical Sciences* 13.1 (2014): 60-62.
6. Gilda AT., et al. "External apical root resorption:two case reports". *Endodontology* 21 (2009): 75-79.
7. Tronstad L. "Root resorption-etiology, terminology and clinical manifestations". *Endodontics and dental traumatology* 4.6 (1988): 241-252.
8. Trope M. "Root resorption of dental and traumatic origin: classification based on etiology". *Practical Periodontics and Aesthetic Dentistry* 10.4 (1998): 515-522.
9. Dudeja C., et al. "An in vitro comparison of effect on fracture strength, pH and calcium ion diffusion from various biomimetic materials when used for repair of simulated root resorption defects". *Journal of Conservative Dentistry* 18.4 (2015): 279-283.
10. Andreasen JO., et al. "Long term calcium hydroxide as a root canal dressing may increase risk of root fracture". *Dental Traumatology* 18.3 (2002): 134-137.
11. Sahebi S., et al. "The effects of short-term calcium hydroxide application on the strength of dentine". *Dental Traumatology* 26.1 (2010): 43-46.
12. Salgar RA., et al. "Surgical endodontic management of external root resorption". *International Journal of Dental Clinics* 3.2 (2011): 93-94.
13. Silva LB., et al. "Immunology of root resorption: A literature review". *Indian Journal of Dental Research* 19.4 (2008): 340-343.
14. Ozer SY. "Diagnosis and Treatment modalities of internal and external cervical root resorptions:Review of the literature with case reports". *International Dental Research* 1 (2011): 32-37.
15. Prakash A., et al. "Burning of roots in orthodontics-reviewing every aspect". *Universal Journal of Medicine and Dentistry* 2 (2013): 1-9.
16. Mortelliti GM and NeedlemanL. "Risk factors associated with atypical root resorption of maxillary primary central incisor". *Pediatric Dentistry* 13.5 (1991): 273-277.
17. Massler., et al. "Root resorption in the permanent teeth of young adults". *Journal of Dentistry for Children* 21 (1954): 158.
18. Sikri VK and Sikri P. "Root resorption- An Endodontic Enigma". *Endodontology* 5 (1993): 11-16.
19. Maria R., et al. "Internal resorption:A review & case report". *Endodontology* 22 (2010): 98-106.
20. Ne RF., et al. "Tooth resorption". *Quintessence International* 30.1 (1999): 9-25.
21. Harokopakis Hajishengallis E. "Physiologic root resorption in primary teeth: Molecular and histological events". *Journal of Oral Science* 49.1 (2007):1-12.
22. Patel S., et al. "Internal root resorption: A review". *Journal of Endodontics* 36.7 (2010): 1107-1121.
23. Trope M. "Root Resorption due to dental trauma". *Endodontic Topics* 1 (2002): 79-100.
24. Castellucci A. "Root Resorption". *Endontics Tridente* 2 (2004): 42.
25. Emre A and Becen D. "Management of a Perforating Internal Re-

- sorptive Defect with Mineral Trioxide Aggregate: A Case Report". *Journal of Endodontics* 35.10 (2009): 1441.
26. Bergmans L., et al. "Cervical external root resorption in vital teeth". *Journal of Clinical Periodontology* 29 (2002): 580-585.
27. Kamburoglu K., et al. "Observer Ability to Detect Ex Vivo Simulated Internal or External Cervical Root Resorption". *Journal of Endodontics* 37.2 (2011): 168-175.
28. Maurice NG. "Dental root resorption". *Oral Surgery, Oral Medicine, Oral Pathology, Oral Radiology, and Endodontology* 88.6 (1999): 647-653.
29. Patel S and Saberi N. "External Cervical Resorption Associated with the Use of Bisphosphonates: A Case Series". *Journal of Endodontics* 41.5 (2015): 742-748.
30. Santos BOA, et al. "Root resorption after dental traumas: classification and clinical, radiographic and histologic aspects". 8 (2011): 439-445.
31. Thomas BA. "Inflammation". Kalamazoo (MI): The Upjohn Co (1977): 33-37.
32. Andreasen JO. "Review of root resorption systems and models. Etiology of root resorption and the homeostatic mechanisms of the periodontal ligament". In: Davidovitch Z, editor. *The biological mechanisms of tooth eruption and root resorption*. Birmingham (AL): EBSCO Media (1988): 9-21.
33. Andreasen JO. "Relationship between surface and inflammatory resorption and changes in the pulp after replantation of permanent incisors in monkeys". *Journal of Endodontics* 7.7 (1981): 294-301
34. Andreasen JO. "Relationship between cell damage in the periodontal ligament after replantation and subsequent development of root resorption. A time-related study in monkeys". *Acta Odontologica Scandinavica* 39.1 (1981): 15-25.
35. Cvek M. "Treatment of non-vital permanent incisors with calcium hydroxide. II. Effect on external root resorption in luxated teeth compared with the effect of root filling with gutta percha". *Revista de Odontologia da UNESP* 24 (1973): 343-354.
36. Trope M., et al. "Short vs. long-term calcium hydroxide treatment of established inflammatory root resorption in replanted dog teeth". *Endodontics & Dental Traumatology* 11.3 (1995): 124-128
37. Trope M., et al. "Effect of different endodontic treatment protocols on periodontal repair and root resorption of replanted dog teeth". *Journal of Endodontics* 18.10 (1992): 492-496.
38. Gulsahi A. "Clinical and Radiologic Appearances of Invasive Cervical Resorption". *Oral Health and Dental Management* 13 (2014): 934-939.
39. Gartner AH., et al. "Differential diagnosis of internal and external root resorption". *Journal of Endodontics* 2.11 (1976): 329-334.
40. Leik K Bakland. "Root Resorption". *Dental Clinics of North America* 36.2 (1992): 491.
41. David keinan and Illan Heling. "Rapidly progressive internal root resorption: a case report". *Dental Traumatology* 24.5 (2008): 546.
42. Borkar S and Ataide IN. "Management of a Massive Resorptive Lesion with Multiple Perforations in a Molar: Case Report". *Journal of Endodontics* 41.5 (2015): 753-758.
43. Pradhan S., et al. "Microsurgical Repair of Root Defects – An Overview". *Journal of Nepal Dental Association (JNDA)* 13 (2013): 95-104.

**Volume 1 Issue 1 June 2017**

**© All rights are reserved by Onkar Singh., et al.**