



## Chaotic Arrhythmias in Teenage Boy with Post Covid 19-Multisystem Inflammatory Syndrome (MIS-C) - Case Report

Dimah Aljarmakani<sup>1\*</sup>, Bashar Hammoudeh<sup>2</sup>, Samir Srour<sup>1</sup> and Baha Juma<sup>2</sup>

<sup>1</sup>Pediatric Cardiology Unit, Children's University Hospital – Damascus, Syria

<sup>2</sup>PICU INTENSIVIST- HMC- Qatar

\*Corresponding Author: Dimah Aljarmakani, Pediatric Cardiology Unit, Children's University Hospital – Damascus, Syria.

Received: November 27, 2024

Published: January 27, 2025

© All rights are reserved by Dimah Aljarmakani., et al.

### Abstract

MIS-C is a rare complication of SARS-CoV-2 infection in children. While Acute myocardial dysfunction is the most common cardiac finding in patients with MIS-C, arrhythmia is usually not common. There have been only a few reports of arrhythmia associated with MIS-C in pediatric patients. We present a case of a 12-years-old boy with severe myocardial dysfunction, accompanied by chaotic Tachy and brady-arrhythmias. He met the diagnosis criteria for MIS-C protocol. The patient kept hemodynamically stable and responded well to medical treatment, with almost complete recovery within ten days.

**Keywords:** SARS-CoV-2; MIS-C; Tachy-Brady Arrhythmias; Myocardial Dysfunction

### Introduction

MIS-C (Multisystem inflammatory syndrome in children) represents a postinfectious, immune-mediated complication rather than an acute infection, it reportedly occurs 2–6 weeks after COVID-19 symptom onset or contact with infected individuals. Cardiac involvement in MIS-C occurs in up to 80% of patients, include ventricular dysfunction, coronary artery dilation or aneurysms, arrhythmia and conduction abnormalities, and more rarely pericarditis and valvulitis [1].

Arrhythmia is among the critical cardiovascular complications reported in 18%–44% of adult patients. The incidence of arrhythmia associated with SARS-CoV-2 in children is much lower, with only a few case series or case reports to date. Arrhythmia can increase an individual's risk of death by deteriorating their clinical condition. Tachyarrhythmia in pediatric patients was reported at a rate of 0%–17. Conduction abnormalities associated with SARS-CoV-2 (e.g., first-degree atrioventricular [AV] block, second-degree AV block, complete AV block, sinus bradycardia, and bundle branch block) are more common complications than tachyarrhythmia in children [2].

We review the case of an adolescent boy with MIS-C and severe cardiac dysfunction, presenting with various types of arrhythmias:

Sinus bradycardia, sinus pauses with junctional escape rhythm, junctional ectopic tachycardia, multiple runs of SVT, premature atrial and ventricular contractions.

### Case Presentation

The patient is 12-year-old previously healthy boy. He was in his usual state of health until 5 days before admission when he developed fever, fatigue, vomiting, diarrhea, abdominal pain and pallor. The day before admission he developed palpitation. He had fever with upper respiratory infection a month ago. In the emergency department, he was noted to be afebrile, awake but irritable, tachycardiac with a heart rate 180 (beats per minute), and normotensive (120/70 mm Hg), with a respiratory rate of 22 per minute, and normally saturated. He was hemodynamically stable, with no cool extremities and normal capillary refill time of 2 seconds.

On monitor, the ECG showed SVT with some irregularity consistent with junctional ectopic tachycardia.

SVT did not respond to vagal maneuvers, and since we did not have adenosine or verapamil at the ED, we started amiodarone infusion. It converted to sinus rhythm; however, due to the development of sinus bradycardia HR: 50/min with sinus pauses, we discontinued amiodarone and continued monitoring. Then the patient was transferred to the pediatric cardiology ward.

- **On physical examination:** Apical impulse was palpable on 5<sup>th</sup> intercostal rib, 2/6 soft systolic murmur heard at the apex, mild hepatomegaly 3 cm below the right costal margin, positive hepatojugular reflux, lung auscultation was clear. He kept hemodynamically stable, normotensive, with fever episodes reaching 38.5 degree Celsius multiple times a day.
- **Echocardiogram:** Showed dilated left ventricle with severe systolic dysfunction, ejection fraction was 20%, severe mitral valve regurgitation, severe tricuspid valve regurgitation, and severe congested IVC with minimal inspiratory collapse (IVC collapsibility index less than 10%).
- **Blood investigation:** Total white blood count 5300cumm (neutrophil: 79%, lymphocyte: 15%), Hemoglobin: 13.4 gram/dl, platelets: 185000, Na: 134 mmol/l, K: 4.2 mmol/l, Ca: 1.2 mmol/l, Cl: 104 mmol/l, urea: 28 mg/dl, creatinine: 0.8 mg/dl, GPT: 63 u/l, GOT: 46 u/l, D-Dimer: 0.41 ug/ml, Fibrinogen: 324, PT: 59%, PTT: 32 s, CRP: 10 mg/L.
- **Covid 19Ab IgM:** 0.3 COI (negative), Covid 19Ab IgG: 5.8 COI (positive), HAV IgM: (negative),
- **Troponin I:** 0.018 ng/ml (normal), CK-MB: 28 u/l (0-25).

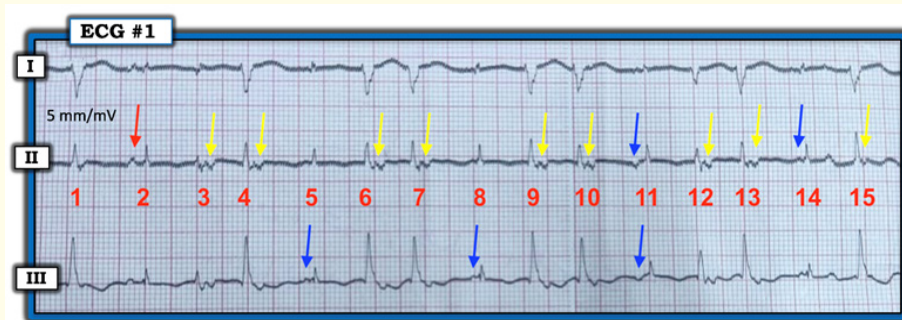
The patient was diagnosed with MIS-C with severe cardiac involvement. We started management with milrinone as an inotrope (continuous IV infusion 0.75 mkg/kg/min), IV diuresis with furosemide (2 mg/kg/day), IVIG (2 g/kg) administered on 2 doses in 2 days, followed by pulse steroid therapy (methylprednisolone 30 mg/kg for 3 days) due to the persistence of fever and signs of heart failure to IVIG, and anticoagulation with rivaroxaban.

**Continuous monitoring of ECG showed**

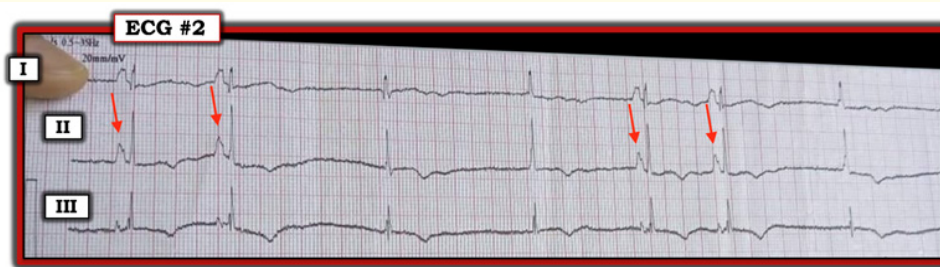Sinus bradycardia, sinus pauses with junctional escape rhythm, multiple runs of SVT (180-190 beat/min), premature atrial contractions and premature ventricular contractions. Rhythm was swinging between 39 beats/min, and 190 beats/min (during SVT runs).

Selected tracing from this case with analysis by Ken Grauer, MD are available at THIS LINK: [tinyurl.com/KG-Blog-MIS-C](https://tinyurl.com/KG-Blog-MIS-C).

Echocardiogram after IVIG and methylprednisolone infusion (five days after admission) showed: Dilated left ventricle with mod-



**Figure 1:** (ECG 1): Premature ventricular contractions (PVCs) with retrograde conduction (yellow arrows), with Premature Atrial contractions (blue arrows).



**Figure 2:** (ECG 2): Sinus rhythm (red arrows) with sinus pauses and junctional escape rhythm.

erate improvement in systolic function EF= 42%, and significant improvement in valvular regurgitation: mild mitral valve regurgitation, mild tricuspid regurgitation, and mild IVC congestion.

**On clinical examination**

He was hemodynamically stable despite arrhythmia, no tachypnea, no hepatomegaly, hepatojugular reflux became negative, no pallor, no fatigue and no fever.

**ON ECG monitoring**

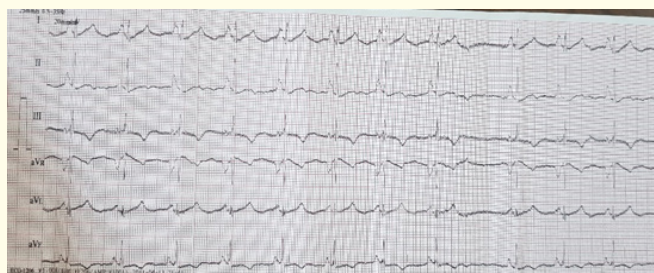
There was no more attacks of SVT, with continuous sinus bradycardia, sinus pauses for more than 15 s and junctional escape rhythm that might refer to sinus sick syndrome(SSS), with few premature ventricular contractions.

Due to the continuity of bradycardia (Heart rate sometimes approached 35/min) with sinus pauses, a temporary pacemaker was planted. Despite the bradycardia, the patient was awake and well perfused. Thankfully, heart rate improved gradually over the next 72 hours with no sinus pauses, and the pacemaker was removed safely after 5 days.

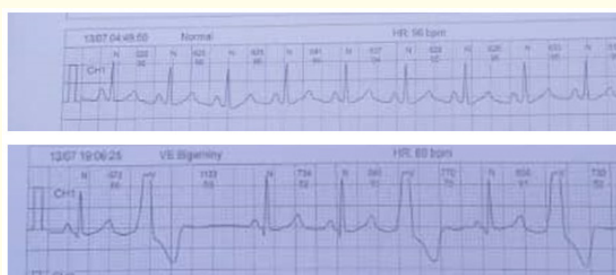- **At discharge:** After two weeks: The patient was stable with normal cardiovascular examination.
- **On echocardiogram:** EF: 54%, trivial mitral regurgitation.

He was discharged on oral medications: ARNI (angiotensin receptor, neprilysin inhibitor) and furosemide.

ECG Holter for 24 hours was done after ten days of discharge, it showed normal sinus rhythm with few PVCs. (Figure 4)



**Figure 3:** ECG at discharge, normal sinus rhythm.



**Figure 4:** ECG Holter, normal sinus rhythm with few PVCs (bigeminy).

**Discussion**

Multisystem inflammatory syndrome in children (MIS-C) is an immune-mediated complication of severe acute respiratory syndrome coronavirus 2 (SARS-CoV-2) infection [3]. There is usually a latency period of 2-6 weeks between initial covid-19 infection and onset of MIS-C [4]. The majority of cases of MIS-C have positive immunoglobulin G serology (75% to 90%) and negative polymerase chain reaction (PCR) assays for the virus (53% to 80%) [1].

When there is a significant clinical concern for MIS-C (fever, for more than 3 days according to WHO; The AAP dose not define length of fever needed for diagnosis, recent or suspected COVID-19 infection or exposure, and symptoms in at least two organ systems), clinicians should obtain tier 1 laboratory study which contains (CBC, CRP, ESR, urinalysis). Concerning abnormalities include: lymphopenia less than 1000/mcl, neutrophilia, platelet count less than 150000/mcl, CRP more than 3 mg/dl [4].

Systolic left ventricular dysfunction (LVSD) was described in the majority of children with a MIS-C diagnosis, and in the later series, ventricular dysfunction was registered in 35–100% cases in children with MIS-C [5].

Cardiac electric abnormalities and arrhythmias have been reported in MIS-C. Pediatric studies report the most frequent arrhythmic involvement during MIS-C, which include a specific repolarization abnormalities, QTc prolongation, first- and second atrio-ventricular block, premature ventricular contractions and premature atrial contractions, supraventricular tachyarrhythmias (especially atrial fibrillation), and non-sustained ventricular tachyarrhythmias. On the contrary, acute pediatric COVID-19 infections tend to have less life-threatening arrhythmias [6].

There are several suggested mechanisms of arrhythmias in viral myocarditis, including an electrical imbalance in myocytes caused by membrane lysis, ischemia caused by endothelial dysfunction, reduced expression of gap junction proteins in the myocardium, alteration in calcium levels and channelopathies, and post-inflammatory myocardial scarring [7].

In a global survey of 1197 electrophysiology professionals regarding hospitalized COVID-19 patients, a variety of arrhythmic manifestations were observed, ranging from benign to potentially life-threatening. The tachyarrhythmia most reported was atrial fibrillation, whereas severe sinus bradycardia and complete heart block were the most common bradyarrhythmias [8].

Research article published in JAHA at 2022 studied tachyarrhythmia during hospitalization in 3600 patients less than 21 years old with covid 19 or MIS-C: Tachyarrhythmias were reported in (1.8%) registry patients with severe acute COVID-19 and (1.7%) patients with MIS-C. Among patients with tachyarrhythmias, SVT was diagnosed in (44%), accelerated junctional rhythm in (14%), and ventricular tachycardia (VT) in (60%). More than 1 type of tachyarrhythmia was observed in (19%). Two patients (3%) had high-grade atrioventricular block during hospital admission, in addition to tachyarrhythmias.

Patients with versus without tachyarrhythmias were older, sicker at the time of hospital admission and more often had other manifestations of cardiac involvement than those without (81% versus 40%). Those patients also had more often ventricular dysfunction (ejection fraction <55%), with 30% having severe ven-

tricular dysfunction (ejection fraction <35). Myocardial involvement was recorded in 67% of patients with MIS-C and was likely a cause for tachyarrhythmias. Patients with tachyarrhythmias had worse clinical outcomes [9].

Our patient is a 12-years-old boy whose condition corresponded with the diagnosis of MIS-C. He had a history of mild fever and involvement in two organ systems: The cardiac system, which showed severe LV systolic dysfunction and arrhythmia, and the gastrointestinal system, characterized by abdominal pain, diarrhea and vomiting. Laboratory tests showed evidence of inflammation, indicated by positive CRP, neutrophilia and lymphopenia with a count less than 1000/mcl. However, with a positive COVID 19 IgG and severe cardiac involvement in a previously healthy child except for a respiratory infection with fever one month before admitting our hospital; and no other possible diagnosis, we found that MIS-C was the most likely etiology. We started a treatment with milrinone as an inotrope for the very poor LV function, diuretics for heart failure, and anticoagulation with rivaroxaban. The patient did not need any of vasopressors since he kept hemodynamically stable with normal BP, and also did not need invasive or noninvasive ventilation.

We started amiodarone upon admission for SVT, but because of the severe bradycardia that developed, we discontinued the medication. No other antiarrhythmic medications were used because of the significant disturbance in rhythm between tachyarrhythmias and bradyarrhythmia.

Immunomodulatory therapy with IVIG 2gram/kg was given, but the patient didn't improve after this initial treatment. Therefore, we initiated methylprednisolone 30 mg/kg IV for three days, which resulted in a very good response. LV function started to improve, and with this improvement, the arrhythmia started to stabilize, with significantly fewer episodes of SVT. However, bradycardia was severe, reaching 35 beats per minute, accompanied with sinus pauses and junctional escape rhythm, a trial of atropine was given for this bradycardia and resulted in an attack of SVT, prompting the placement of temporary pacemaker. The patient remained stable despite the severe bradycardia. Over the next five days, the heart rhythm started to back to a normal rate, along with the normalization of heart function.

In addition to existing hypotheses, more study is still needed to fully understand the primary mechanism of post-Covid 19-Multi-



system Inflammatory Syndrome. Anti-aging genes have become crucial in the fight against the worldwide chronic illness epidemic. The immune system depends on the anti-aging gene Sirtuin 1 (Sirt 1). People with COVID-19 should get tested early for Sirt 1, an anti-aging protein that must be present in plasma at amounts of ng/ml. Low levels of Sirt 1 plasma protein combined with Sirt 1 suppression will impair immunity and make the COVID-19 infection uncontrollable [10].

## Conclusion

Cardiac involvement in MIS-C is an important medical challenge. Although myocardial dysfunction is the most common feature, medical literature reported different types of arrhythmias associated with either acute covid-19 infection or MIS-C. We believe that our case is the first to show a chaotic brady- tachyarrhythmia with severe heart failure in a previously healthy child, who responded well to medical treatment with inotropes and immunomodulators, with no need for antiarrhythmic medications and with no adverse consequences.

## Acknowledgements

I would like to express my deepest gratitude to Dr. Ken Grauer, MD, from Gainesville, Florida, USA, for his invaluable help in reviewing all the patients ECGs with his exceptional professionalism and for his advice and unfunded support while working on this case report.

## Bibliography

1. Tarek Alsaied., *et al.* "Review of Cardiac Involvement in Multisystem Inflammatory Syndrome in Children". *Circulation* 143.1 (2020).
2. Song MK and Kwon B. "Arrhythmia and COVID-19 in children". *Clinical and Experimental Pediatrics* 66.5 (2023): 190-200.
3. Yonca Bulut. "Multisystem inflammatory syndrome in children (MIS-C) and long Covid". *Global Pediatrics* (2023).
4. Rocker J and Weiss C. "COVID-19, MIS-C, and long COVID in pediatric patients: an update". *Pediatric Emergency Medicine Practice* 21.7 (2024): 1-28.
5. Vasichkina E., *et al.* "COVID-19 Heart Lesions in Children: Clinical, Diagnostic and Immunological Changes". *International Journal of Molecular Sciences* 24.2 (2023): 1147.
6. Fumanelli J., *et al.* "Cardiac Arrhythmias in Pediatric Age: Are They Triggered by SARS-CoV-2 Infection?" *COVID 3* (2023): 192-197.
7. Varney JA., *et al.* "COVID-19 and arrhythmia: An overview". *Journal of Cardiology* 79.4 (2022): 468-475.
8. Gopinathannair R., *et al.* "COVID-19 and cardiac arrhythmias: a global perspective on arrhythmia characteristics and management strategies". *Journal of Interventional Cardiac Electrophysiology* 59.2 (2020): 329-336.
9. Audrey Dionne., *et al.* "Tachyarrhythmias During Hospitalization for COVID-19 or Multisystem Inflammatory Syndrome in Children and Adolescents". *Journal of the American Heart Association* 11.20 (2022).
10. Ian James Martins. "COVID-19 Infection and Anti-Aging Gene Inactivation". *Acta Scientific Nutritional Health* 4.5 (2020): 01-02.