



A Rare Encounter: Diagnosing Peritoneal Tuberculosis in an Unexpected Presentation

Maria do Carmo Girão^{1,2*}, Daniela M Raposo³, Luís Galindo¹, Nelson Silva¹, Ricardo Girão¹ and Carlos Vaz¹

¹General Surgery, Hospital CUF Tejo, Lisbon, Portugal

²General Surgery, Unidade Local de Saúde do Baixo Alentejo, Beja, Portugal

³General and Family Medicine, Unidade Local de Saúde do Algarve, Olhão, Portugal

***Corresponding Author:** Maria do Carmo Girão, General Surgery, Hospital CUF Tejo, Lisbon, Portugal.

DOI: 10.31080/ASCR.2024.05.0597

Received: October 15, 2024

Published: November 03, 2024

© All rights are reserved by **Maria do Carmo Girão, et al.**

Abstract

Peritoneal tuberculosis (PT) is a rare yet serious form of extrapulmonary tuberculosis, often characterized by vague abdominal symptoms, making diagnosis difficult and challenging.

We report the case of a 21-year-old melanodermic male. During the work-up for secondary hypertension, a peripancreatic lesion was found on computed tomography (CT). Following a series of diagnostic procedures, including upper endoscopy and echo-endoscopy, an exploratory laparoscopy for further evaluation was performed, and necrotizing lymphadenitis was identified. Post-operatively, the patient developed persistent abdominal pain, fever, and night sweats, prompting repeat imaging and surgical intervention. This second laparoscopy revealed multiple peritoneal implants and ascites.

Histopathological examination showed intense granulomatous inflammation, raising suspicion for peritoneal tuberculosis. Given inconclusive microbiological results, empirical anti-tuberculous therapy was initiated. The patient exhibited significant symptomatic improvement within days of treatment.

This case underscores the diagnostic complexities associated with PT and the critical role of surgical intervention in both diagnosis and treatment. Our findings emphasize the need for a high index of suspicion for tuberculosis in patients presenting with unexplained abdominal symptoms, particularly in areas with endemic rates of the disease. Prompt diagnosis and initiation of treatment are essential for improving patient outcomes.

Keywords: Tuberculosis; Peritoneal Tuberculosis; General Surgery; Laparoscopy; Carcinomatosis

Introduction

Although all the advances and improvements in therapeutics and treatments, tuberculosis affects around 10 million people worldwide, causing annually one million deaths. The lung is the main organ affected by the disease, but in about 15% of people, there is an extrapulmonary involvement [1,2].

Concerning extra-peritoneal involvement, peritoneal tuberculosis (PT) accounts for 11% of all tuberculosis cases [3].

It is generally challenging to diagnose and treat, because of the low yield of microbiological tests (microbiological positivity in ascitic fluid is difficult to obtain), the unspecific symptoms and it can resemble other diseases, like peritoneal carcinomatosis [1-3].

Signs and symptoms of PT are unspecific and may include fever, abdominal distension and pain, weight loss and ascites [2,4,5].

There is lack of evidence in the treatment of PT, and treatment options are based on guidelines for the treatment of pulmonary and extra-pulmonary tuberculosis [4].

Case Report

We present the case of a 21-year-old melanodermic male patient, natural from Luanda, Angola, actually living in the United Kingdom, with medical history of asthma and high blood pressure.

In the context of the study of possible secondary hypertension, an abdomino-pelvic Computed Tomography (AP-CT) scan was car-

ried out which identified “a well-circumscribed lesion, interposed between the left lobe, the gastric body and the isthmus of the pancreas, apparently with cleavage planes with these structures, measuring around 3.7x2.5x2.5 cm” (Figure 1).

In light of these findings, the evaluation was complemented with an upper endoscopy, which was clean, and also an echo-en-

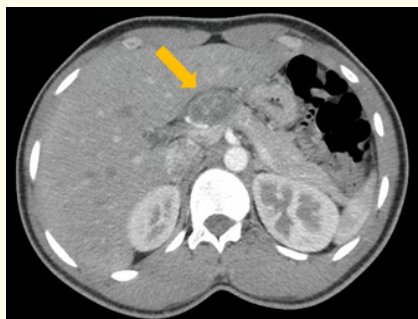

Figure 1: CT scan showing abnormal abdominal lesion.

doscopy which in turn describes “Peripancreatic nodule, probably corresponding to an adenopathic conglomerate” with a negative cytological study for neoplastic cells and a histological study identifying necrotizing lymphadenitis with a possible infectious/parasitic cause.

Given this uncertainty, the patient was referred for exploratory laparoscopy, which allowed observation and excision of the mass, as well as collection of material for microbiology (Figure 2), the result of which was an intense acute inflammatory infiltrate and foreign body type granulomatous reaction with numerous multinucleated giant cells, no microorganisms identified. In terms of serologies, the result was inconclusive for an anisakis infection (IgE Neg; IgG 3.34 mg/L).

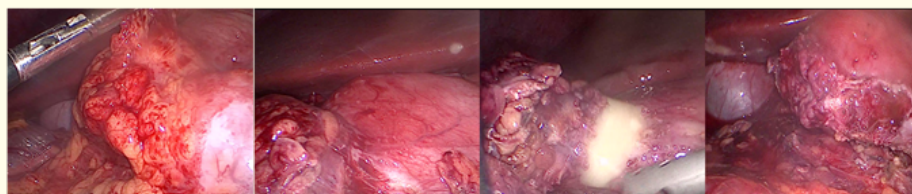


Figure 2: Laparoscopic findings.

Based on this information, the patient was discharged on post-operative day 3, treated with albendazole, on the assumption of a parasitic infection.

After 3 weeks he returned to the clinic with a 1-week history of diffuse abdominal pain, later localized to the right hypochondrium

and flank, associated with vomiting, diarrhea, anorexia with weight loss of 3% and night sweats. There was no fever, cough, dyspnea, altered mental status or headache. On objective examination, the patient had pain on superficial and deep palpation of the right hypochondrium and flank, which worsened on inspiration, without pain on decompression.

The patient was admitted to hospital for etiological clarification. During hospitalization, the symptoms persisted, and fever developed, mainly in the afternoon, with a maximum of 39°C, with a partial response to antipyretics. In this context, he underwent abdominal ultrasound and AP-CT, which showed perivesicular fluid and inflammatory thickening of the vesicle wall without lithiasis,

and for this reason he was again referred for exploratory laparoscopy (Figure 3).

During surgery, multiple peritoneal implants were found scattered throughout the peritoneal cavity (Figure 4), as well as ascites. Several biopsies and microbiological samples were taken.

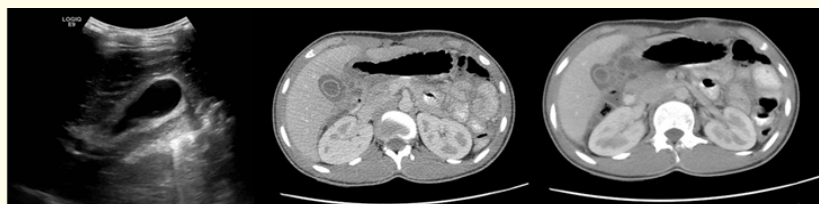

Figure 3: US and CT scan showing thickening of the gallbladder and fluid.

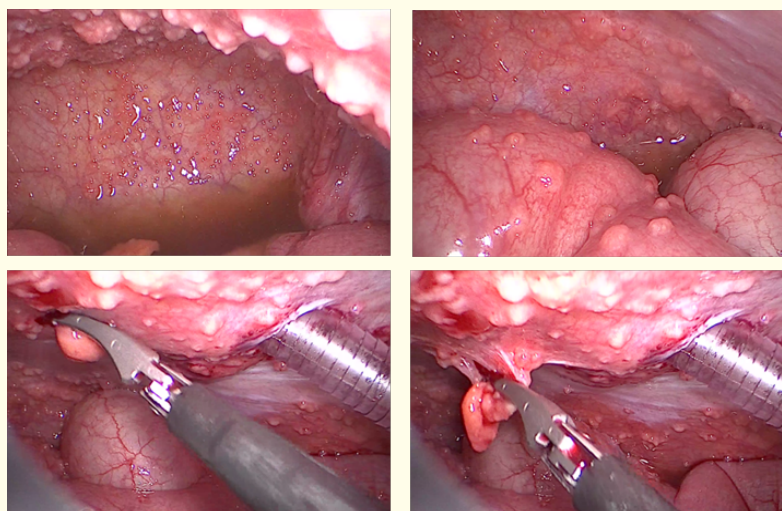


Figure 4: Multiple peritoneal implants were found scattered throughout the peritoneal cavity.

Anatomopathological examination revealed an intense granulomatous inflammatory infiltrate and was negative for acid-fast bacillus (AFB) and parasites. Molecular testing was also made, and the TB PCR was 0,38 ng/dL.

Due to the high clinical suspicion of peritoneal tuberculosis, and while waiting for cultural results, which can take long, empirical tuberculostatic therapy with isoniazid, rifampicin, pyrimethamine, ethambutol and pyridoxine was started. Patient had an adenosine deaminase (ADA) of 34mg/dl in the ascitic fluid. There was symptomatic improvement of fever, night sweats and abdominal pain after 5 days of treatment, and the patient continued to have improve-

ments with maintenance of the treatment. Meanwhile, the cultural exam of the ascitic fluid was negative, but the one of the peritoneal biopsies was positive for *Mycobacterium tuberculosis* complex. No parasites were found on either sample.

He was kept under strict surveillance for the first 3 weeks, which is the necessary period to perform a therapeutic trial, and after that he was released from the hospital. The course of the treatment lasted one year, with regular medical appointments to ensure therapeutical adhesion and well-being of the patient. After this time the patient was considered cured.

Discussion

Tuberculosis is a disease that can involve multiple organs, and in terms of extrapulmonary disease, peritoneal involvement is the 6th most common. There are discrepancies in its incidence in the literature, but the World Health Organization estimates it at 15% [6,7].

PT is difficult to diagnose, not only because of the lack of specificity of the symptoms, but also because of its insidious nature, which often leads patients to seek medical attention late. Nevertheless, its timely diagnosis and treatment are essential to reduce the morbidity associated with this pathology [2,6].

In peritoneal involvement, it is very difficult to isolate bacilli for microbiological diagnosis (gold standard) [8], and Ziehl-Neelsen staining is positive in up to 6% of patients [2,6]. On the other hand, the use of molecular diagnostics, namely TB PCR, is highly specific, but has a very low threshold in terms of sensitivity [6]. In the present case, the patient obtained a TB PCR result of 0.38, which is still considered a doubtful value.

There is another marker whose positivity can be highly suggestive of PT, positive ADA in the ascitic fluid, and according to Koff and Azar (2024) the specificity reaches 100% for ADA > 30 mg/dL, with a sensitivity of around 95% [6,8-10].

Regardless of all these markers, a definitive diagnosis may require the use of exploratory laparoscopy, which allows peritoneal biopsies to be taken [6,9]. In this particular case, the surgery performed was essential in determining the good outcome of this case, not only because of the observation of the macroscopic aspect of the peritoneum, which is very suggestive in this context, but also because it allows biopsies to be taken, which will rule out mimicking pathologies, such as peritoneal carcinomatosis. In addition, pathological examination is compatible with the presence of caseous granulomas in 70 to 95% of cases [6]. Our patient ADA result (34 mg/dL) associated with the visualization of the macroscopic aspect of the peritoneal cavity were highly suggestive of peritoneal tuberculosis, and ultimately guided the decision to begin the empirical treatment.

Despite all efforts to establish a diagnosis, this may not be possible and, in the context of high clinical suspicion, therapeutic testing with empirical antimycobacterial drugs may be indicated. In this case, it is considered that the diagnosis of PT is most likely if there is a response to the treatment given, with improvement of symptoms, improvement of ascites and thickening of the peritoneum [6,7].

Conclusion

This case highlights the complexities involved in diagnosing peritoneal tuberculosis (PT), particularly given its non-specific symptoms and the challenges in microbiological confirmation. The 21-year-old male patient presented with a series of gastrointestinal symptoms and underwent a thorough diagnostic work-up, ultimately leading to exploratory laparoscopy, which was critical in establishing a diagnosis. The findings of a granulomatous inflammatory reaction, combined with a high clinical suspicion of PT, warranted the initiation of empirical anti-tuberculous therapy.

Despite inconclusive serological and microbiological investigations, the patient's significant clinical improvement following treatment supports the diagnosis of PT. This case emphasizes the importance of considering PT in differential diagnoses for abdominal symptoms, particularly in regions with known endemic rates of tuberculosis. It also underscores the potential need for diagnostic and therapeutic laparoscopy in similar clinical scenarios, enabling both direct observation of pathological changes and the collection of biopsies for histological examination. Ultimately, prompt recognition and treatment of PT can prevent complications, highlighting the need for heightened awareness among clinicians in both endemic and non-endemic settings.

Bibliography

1. D Krishna Jha., *et al.* "Review: Evidence-based approach to diagnosis and management of abdominal tuberculosis". *Indian Journal of Gastroenterology* 1 (2023): 3.
2. DK Jha., *et al.* "Clinical and Radiological Parameters to Discriminate Tuberculous Peritonitis and Peritoneal Carcinomatosis". *Diagnostics* (2023).
3. CM Gras-Gómez., *et al.* "Peritoneal tuberculosis mimicking colonic carcinomatosis". ARAN Ediciones S.L. (2023).
4. CW Ling., *et al.* "Systematic Review on Treatment and Outcomes of Tuberculous Peritonitis in Patients on Peritoneal Dialysis". *Kidney International Report* 9 (2024): 277-286.
5. C Clancy., *et al.* "Diagnosing peritoneal tuberculosis". *BMJ Case Reports* (2013).
6. A Koff and MM Azar. "Diagnosing peritoneal tuberculosis". *BMJ* (2020).

7. AB Al-Zanbagi and M K Shariff. "Gastrointestinal tuberculosis: A systematic review of epidemiology, presentation, diagnosis and treatment". *Saudi Journal of Gastroenterology* (2021).
8. DK Jha., *et al.* "Evidence-based approach to diagnosis and management of abdominal tuberculosis". *Indian Journal of Gastroenterology* 42.1 (2023): 17-31.
9. AS Dahale., *et al.* "Reappraisal of the Role of Ascitic Fluid Adenosine Deaminase for the Diagnosis of Peritoneal Tuberculosis in Cirrhosis". *Korean Journal of Gastroenterology* 78.3 (2021): 168-176.
10. L Tao., *et al.* "Diagnostic value of adenosine deaminase in ascites for tuberculosis ascites: A meta-analysis". *Diagnostic Microbiology and Infectious Disease* 79.1 (2014): 102-107.