



Bochdalek's Left Diaphragmatic Hernia

Abdou Niasse^{1*}, Mouhamadou Lamine Gueye², Papa Mamadou Faye³,
Abdourahmane Ndong⁴, Abdoulaye Ndiaye⁵ and Ibrahima Konate⁴

¹General Surgeon in General Surgery Unit of Cheikh Ahmadoul Khadim Hospital in
Touba, Sénégal

²General Surgeon in Ouakam Military Hospital, Senegal

³General Surgeon, General Surgery Departement of Dalal Jamm Hospital, Dakar,
Sénégal

⁴General Surgeon, General Surgery Departement of Regional Hospital of Saint-Louis,
Sénégal

⁵General Surgeon in General Surgery Unit of Cheikh Ahmadoul Khadim Hospital in
Touba, Sénégal

***Corresponding Author:** Abdou Niasse, General Surgeon in General Surgery Unit of
Cheikh Ahmadoul Khadim Hospital in Touba, Sénégal.

DOI: 10.31080/ASCR.2024.05.0509

Received: December 12, 2023

Published: January 03, 2024

© All rights are reserved by **Matheus
Rocha de Seixas Nogueira and Liliana
Sampaio Costa Mendes.**

Abstract

A rare pathology in adults, Bochdalek's hernia is a protrusion of abdominal viscera into the thorax through the posterolateral hiatus of the diaphragm. Often asymptomatic and discovered by chance, the risk of incarceration of loops remains an indication for reconstructive surgery. We report 2 cases of Bochdalek's hernia having motivated a diaphragmatic plication.

Observation 1: This was a 76-year-old patient, followed for gastric cancer, in whom the extension assessment allowed the discovery of a left Bochdalek diaphragmatic hernia fortuitously containing the tumoral stomach, spleen, colon and omentum. He underwent a gastrectomy associated with a diaphragmatic plication. The suites were simple.

Observation 2: This was a 64-year-old patient with hypertension under treatment, followed for a long time for recurrent left pneumonia. The radiological workup revealed a Bochdalek's hernia containing the stomach, colon and omentum. She benefited from a diaphragmatic plication. The consequences were marked by basal pleurisy which had progressed well with corticosteroids and respiratory physiotherapy.

Conclusion: The cure of a diaphragmatic hernia should always be considered in adults even if its discovery is accidental during surgical exploration because of the risk of incarceration and strangulation of the abdominal viscera.

Keywords: Bochdalek's Hernia; Diaphragmatic Hernia; Diaphragmatic Plication; Phrenorrhaphy

Introduction

Bochdalek's hernia was first described in 1848 as a congenital hernia resulting from delayed development of the posterolateral diaphragmatic formation [1]. Most diaphragmatic hernias are diagnosed in neonates with clinical symptoms caused by pulmonary compression [2]. A Bochdalek hernia identified in adulthood is extremely rare with a prevalence of 0.17 [3-5]. Identification of Bochdalek hernia in asymptomatic adults is increasing due to advances in imaging modalities [4,5]. The risk of incarceration of the viscera suggests surgical repair of the diaphragmatic defect regardless of the symptoms [6,7]. The aim of our study is to report

2 cases of Bochdalek's diaphragmatic hernia diagnosed in adults who motivated phrenoplication. These 2 cases allowed us to carry out a review of the literature on this condition.

Observation 1

This was a 64-year-old hypertensive patient followed. She had several episodes of treated bacterial pneumonia. She presented with regurgitation associated with mild dyspnea and a dry cough aggravated by food. The physical examination was normal apart from a syndrome of condensation of the left pulmonary hemi-field. The chest X-ray found an ascent of the diaphragmatic dome with

aeric images under the left lung (Figure 1). The thoracic computed tomography (CT) had shown a left diaphragmatic hernia with digestive contents (Figure 2). A left subcostal laparotomy performed revealed a left Bochdalek hernia with a 7 cm neck whose sac contained the entire stomach, left colic angle, spleen and part of the omentum (Figure 3). A reduction of the hernial contents was performed followed by diaphragmatic plication using simple polyester 3 stitches without pleural drainage (Figure 4). The follow-up was marked by the occurrence on the 3rd postoperative day of left basal pleurisy without respiratory repercussions, which progressed well under simple corticosteroid therapy associated with respiratory physiotherapy. After an 8-month follow-up, the patient remained asymptomatic.

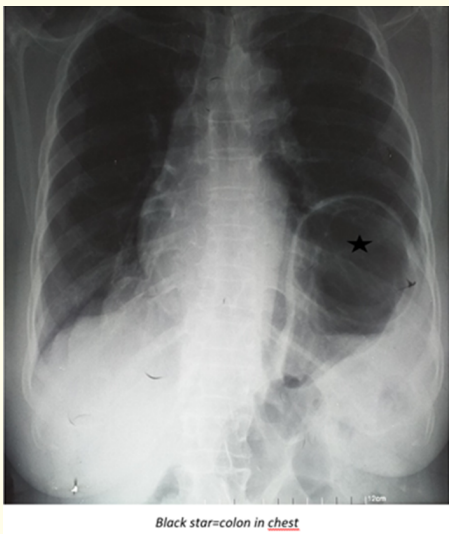


Figure 1: Frontal chest X-ray showing the ascent of the left diaphragmatic dome and the presence of digestive gas intrathoracically in our patient 1.

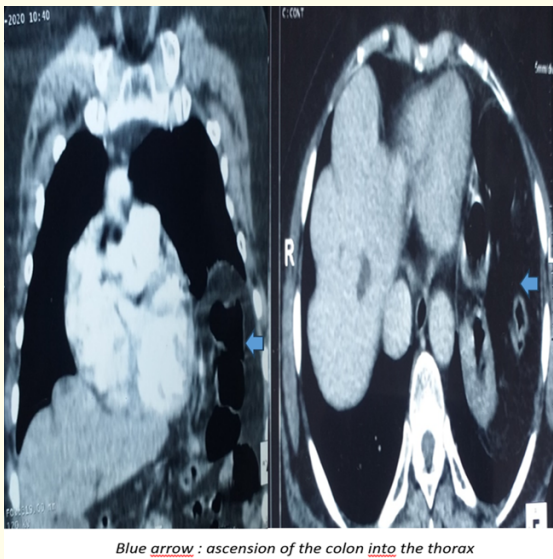


Figure 2: CT image of diaphragmatic hernia with digestive contents in our patient 1.

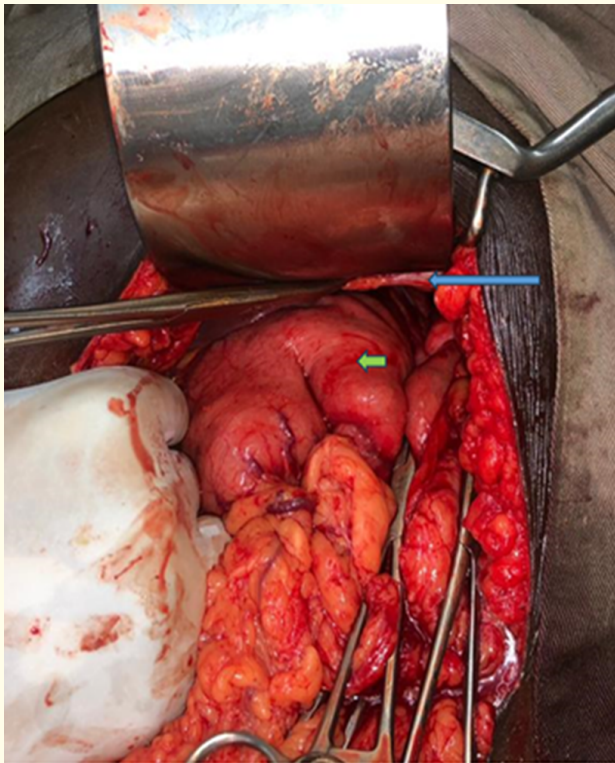


Figure 3: Intraoperative view of the diaphragmatic hernia with its contents in our patient 1 (diaphragm grasped by the forceps from above).

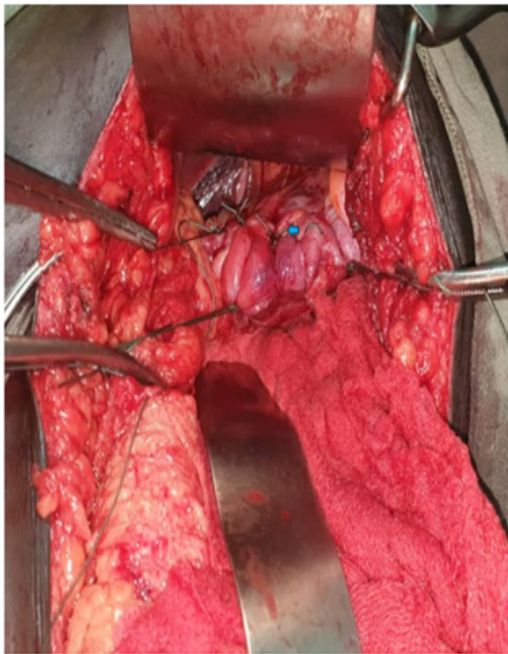


Figure 4: Intraoperative view diaphragmatic plication (blue arrow) in our patient 1.

Observation 2

This was a 76-year-old patient with no particular medical and surgical history. He presented with a syndrome of pyloroduodenal stenosis evolving for 6 weeks before his consultation. He had no ulcer syndrome or cardio-respiratory symptoms. The general condition was good (WHO 1). The remainder of the physical examination was unremarkable. The esophagogastroduodenal fibroscopy revealed an ulcerobudding and partially stenosing tumor formation located on the antropyloric region of the stomach. Histological examination of the tumor biopsy showed a well-differentiated and infiltrating intestinal type adenocarcinoma of the stomach. The thoraco-abdomino-pelvic computed tomography (CT) performed as part of the extension assessment had accidentally shown a Bochdalek hernia on the left side without metastases or locoregional extension of the tumor. Thus, the diagnosis of gastric cancer without lymph node invasion or metastases (T2N0M0 Stage IB) was made, accompanied by an asymptomatic left-sided Bochdalek hernia. After a multidisciplinary consultation meeting (RCP), a lower pole gastrectomy was decided immediately given the diaphragmatic hernia. Midline supraumbilical laparotomy found a left Bochdalek hernia with a 6 cm neck whose sac contained the entire stomach, left colic angle, spleen and part of the omentum (Figure 5). The reduction of the hernia made it possible to highlight an antropyloric tumor which was well localized. There was no lymph node or locoregional and remote extension. A lower pole gastrectomy was performed with gastrojejunal anastomosis according to Finsterer. The tumor was well localized with no extension to intrahernal organs. The hernia repair consisted of diaphragmatic plication using "X" stitches with Polyester 3 (Figure 6). The suites were simple. After a follow-up of 3 months, the patient remained asymptomatic. The anatomo-pathological examination of the surgical specimen made it possible to classify the tumor as T4aN0M0 (involvement of the serosa, presence of 17 uninjured lymph nodes, absence of metastases) or stage IIb. Adjuvant chemotherapy was indicated and performed.

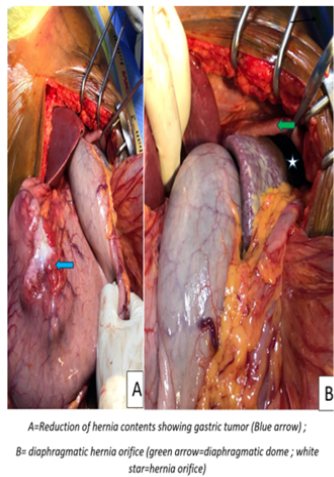


Figure 5: Intraoperative view diaphragmatic hernia with its contents in our patient 2.

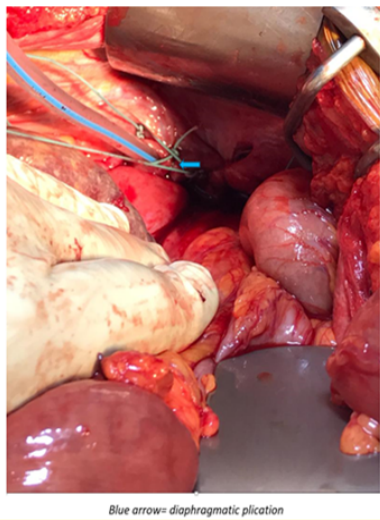


Figure 6: Intraoperative view diaphragmatic plication in our patient 2.

Discussion

Bochdalek hernia (HB) is a congenital diaphragmatic anomaly characterized by incomplete closure of the pleuro-peritoneal folds around the 8th week of gestation [8]. As noted in our patients, it is more common on the left side (80–85%). This is explained by the fact that complete closure of the diaphragm occurs first on the right side and the liver usually acts as a barrier against herniation on the right side [8]. In adults, its frequency is estimated at 0.17% to 12.7% for all diaphragmatic pathologies [3,5]. Unlike an often acute and severe clinical presentation of HB in newborns, this pathology is often asymptomatic in adults, as we noted in our second patient [3,5]. In its symptomatic form, the respiratory signs are often associated with digestive disorders as noted in our first patient. Its occurrence can be facilitated by the presence of an abdominal hyperpressure factor [3,5,9]. In our second patient, the tumor would promote gastric peristaltic undulations and abdominal hyper-pressure. These two factors would explain the rise of the whole stomach in the diaphragmatic defect. Imaging has made the diagnosis easier and would reduce the incidental intraoperative discovery of HB [10,11]. CT and magnetic resonance imaging (MRI) are the most useful examinations for the diagnosis of HB [12]. In our second patient, despite the absence of compressive respiratory symptoms related to HB, we opted for surgical repair of the diaphragmatic defect. While the compression of the lung hindering its expansion as well as the repeated regurgitation would probably explain the occurrence of repetitive pneumopathies in the first patient. We performed diaphragmatic plication in our 2 patients. This surgery is justified by the size of the neck (6 cm and 7 cm respectively), the large contents of the sac (all the left sub-phrenic organs), the seat on the left (the liver not interfering), the gastric tumor source of abdominal hyperpressure and respiratory symptomatology respectively. All these factors would expose, in an unpredictable way,

to the risk of hernial strangulation which could be life-threatening. Most authors have suggested that HB in adults in general requires surgical repair regardless of symptoms, given the risk of visceral incarceration [6,8,13]. This surgery can consist of a direct suture [6]. Nevertheless, some authors suggest interposition of a prosthesis [14,15]. Our patients were approached by laparotomy. This approach allowed a clear day on the defect as well as its repair. Left HB can be approached either by laparotomy or thoracotomy with the same results and the same ergonomics [14]. Others recommend laparoscopy, which would provide excellent exposure of the supra-mesocolic level when associated with the prone position with the legs apart [6]. The postoperative course was simple in our patients with rapid recovery of respiratory function. This further justifies the need for surgical repair of hernias. The absence of tumor extension to the intrahernial organs as well as the discovery of the diaphragmatic hernia, justified the first cure of the hernia in our second patient with a curative surgery of the gastric tumor.

Conclusion

Negligence and absence of a cure for a diaphragmatic hernia, even asymptomatic, would expose to the risk of incarceration and strangulation of abdominal viscera and to pneumopathy or even pulmonary fibrosis which is often disabling. A simple diaphragmatic raphy by laparotomy would be a good way to relieve respiratory symptoms.

Conflicts of Interest

None

Authors Contributions

All authors contributed to write this article.

Bibliography

1. Bochdalek VA. "Einige Betrachtungen über die Entstehung des angeborenen Zwerchfellbruches. Als Beitrag zur Anatomie der Hernien". *Vierteljahrsschrift prakt Heilunde* 5 (1848): 89-97.
2. Losanoff JE and Sauter ER. "Congenital posterolateral diaphragmatic hernia in an adult". *Hernia* 8 (2004): 83-85.
3. Brown SR., et al. "Bochdalek hernia in the adult: demographics, presentation, and surgical management". *Hernia* 15 (2011): 23-30.
4. Gale ME. "Bochdalek hernia: prevalence and CT characteristics". *Radiology* 156 (1985): 449-452.
5. Mullins ME., et al. "Prevalence of incidental Bochdalek's hernia in a large adult population". *American Journal of Roentgenology* 177 (2001): 363-366.
6. Kubota K., et al. "Bochdalek hernia in a young adult: report of a case". *Surgery Today* 31 (2001): 322-324.
7. Swain JM., et al. "Congenital diaphragmatic hernia in adults". *Seminars in Laparoscopic Surgery* 8 (2001): 246-255.
8. Goh BK., et al. "Right-sided Bochdalek's hernia in an adult". *American Journal of Surgery* 194 (2007): 390-391.
9. Kikuchi S., et al. "A case of right-sided Bochdalek hernia incidentally diagnosed in a gastric cancer patient". *BMC Surgery* 16.1 (2016): 29-34.
10. Puri P and Wester T. "Historical aspects of congenital diaphragmatic hernia". *Pediatric Surgery International* 12 (1997): 95-100.
11. Temizöz O., et al. "Prevalence and MDCT characteristics of asymptomatic Bochdalek hernia in adult population". *Diagnostic And Interventional Radiology* 16 (2010): 52-55.
12. Katz AS., et al. "The air meniscus as a radiographic finding: a review of the literature and presentation of nine unusual cases". *CRC Critical Reviews in Diagnostic Imaging* 11 (1978): 167-183.
13. Mullins ME and Saini S. "Imaging of incidental Bochdalek hernia". *Seminar on Ultrasound CT MR* 26 (2005): 28-36.
14. Rout S., et al. "Right-sided Bochdalek hernia obstructing in an adult: case report and review of the literature". *Hernia* 11 (2007): 359-362.
15. Soylu E., et al. "Recurrent indigestion in a young adult". *Case Reports on Gastroenterology* 17 (2010): 1497-1498.
16. Michel P., et al. "Cancer de l'estomac". *Thésaurus National De Cancérologie Digestive* (2017).