



Are We Over Investigating Non-Visible Haematuria, Time to Change Imaging Strategies?

Gilani Syed^{1*}, Melhem Motaz¹, Wani Mudassir², Burki Javid³, Zubair Bhat³, Omar Algurabi¹, Shahbaz Mehmood¹, Laith Abawi⁴, Vyrus Eleftheria⁵ and Michael Conroy⁵

¹Urology Registrar, Medway Maritime Hospital, Kent, UK

²ST4 Urology Trainee, Royal Glamorgan Hospital, Cardiff, UK

³Urology Consultant, University College London Hospital, UK

⁴SHO Surgery, Medway Maritime Hospital, Kent, UK

⁵SHO, Medway Maritime Hospital, Kent, UK

*Corresponding Author: Gilani Syed, Urology Registrar, Medway Maritime Hospital, Kent, UK.

DOI: 10.31080/ASCR.2024.05.0503

Received: November 07, 2023

Published: December 22, 2023

© All rights are reserved by Gilani Syed, et al.

Abstract

Objective: To assess upper tract pathologies and diagnostic accuracy of imaging in patients presenting with haematuria.

Material and Method: We retrospectively analysed data of 821 patients, presenting to the haematuria clinic between January 2019 and January 2020. We recorded type of haematuria, age, sex, family, and occupational history. Results of cystoscopy and diagnostic imaging were collected from records. Involvement of upper tracts and diagnostic accuracy of imaging were assessed.

Results: Out of 821, 438 (58.83%) were male and 338 (41.17%) were female. 536 (65%) had non-visible haematuria (NVH) and 286 (35%) had visible haematuria (VH). 117 (14%) were active smokers and 238 (27%) were ex-smokers. 9 patients had exposure to chemicals and 34 (4.2%) had a positive family history of urinary tract cancers. 813 (99%) had flexible cystoscopy and 795 (97%) had upper tract imaging. 85% had CT Urogram and 46.6% had both CT and ultrasound. 87 (10.7%) patients had bladder tumours. 38 (4.7%) of patients had upper tract pathologies. Urolithiasis was diagnosed in 18 (2.2%), and upper tract malignancies in 10 (1.2%) of cases. Renal cell carcinoma was diagnosed in 6 (0.73%), and upper tract urothelial cancer in 4 (0.48%) of cases. 93.75% of patients with upper tract malignancies presented with visible haematuria. CT urogram had 100% diagnostic accuracy. Ultrasound was diagnostic in 93% of cases (16/17).

Conclusion: The prevalence of upper renal tract malignancies is very low in patients presenting with NVH. This is the time to risk stratify patients with non-visible haematuria and tailor the diagnostic imaging. Ultrasound can replace CT urogram in patients with NVH, further comparative studies are required.

Keywords: Haematuria; CT Urogram; Upper Tract Urothelial Cancer; Ultrasound

Abbreviations

VH: Visible Haematuria; NVH: Non-Visible Haematuria; CTU: CT Urogram; UTUC: Upper Tract Urothelial Cancers; RCC: Renal Cell Cancer

Introduction

Haematuria is one of the most common urologic diagnoses and is a common reason for urology referral, estimated to account for over 20% of urology evaluations [1]. Traditionally, haematuria is classified into visible Haematuria (VH) and nonvisible Haematuria (NVH). NVH is further classified into symptomatic and asymptomatic. VH is associated with a 20.4% risk of urinary tract malignancy

as compared to only 5.2% with NVH [2]. Haematuria is quite common and 20% of men over the age of 60 have NVH. Most patients (70- 90%) with NVH have no urological pathology identified on evaluation [3,4].

Haematuria evaluation includes history, physical examination, urinalysis, and upper tract imaging. It's a reasonable practice to obtain CT Urogram (CTU) in patients with VH, as the risk of detecting upper tract malignancies is significant [5]. The risk of detecting upper tract malignancy is very low in patients with NVH. A recent study suggests, CTU can be safely replaced with a renal and bladder

ultrasound in patients with NVH, because upper tract malignancy is exceedingly rare in these patients [6].

Existing guidelines vary in their definition of NVH, recommending evaluation, and the optimal imaging method. American Urology Association (AUA) guidelines suggest a CTU for the evaluation of NVH [7], on the contrary, the UK- National institute for health and care excellence (NICE) guidelines don't specify which upper tract imaging modality to use in the evaluation of NVH [8]. Japanese guidelines recommended ultrasound imaging for patients with NVH [9].

Despite the lack of consensus on upper tract imaging in a patient with NVH, Cystoscopy remains the cornerstone of evaluation in haematuria patients [10]. Upper tract pathologies are initially evaluated with CTU and ultrasound urinary tract. Further invasive studies like retrograde and ureteroscopy are done in certain cases. The sensitivity and specificity of CTU for detecting upper tract lesions are 89% and 99.6% although it is associated with the risk of radiation exposure, anaphylaxis, and contrast-related nephropathy [5,11]. Comparing the cost, to detect one case of bladder, kidney, and upper tract cancer with cystoscopy and CTU is estimated at \$6.5 million as compared to \$54,000 using ultrasound and cystoscopy [12].

We retrospectively reviewed our dedicated haematuria clinic data to assess the presence of urinary tract pathologies and their association with VH and NVH. We also assessed the diagnostic accuracy of upper urinary tract imaging.

Patient and Methods

We retrospectively reviewed data of 821 patients presenting to a dedicated haematuria clinic, referred by general practitioners and other health professionals. Data was collected from the haematuria clinic electronic reporting database, for the patients who underwent haematuria evaluation from January 2019 to January 2020. Demographic data were retrieved from medical records and included age, sex, smoking status, exposure to carcinogens, family history of urological malignancies and type of haematuria. Physical examination findings, results of imaging and flexible cystoscope were also obtained from the electronic database.

Results

A total of 821 patients, who underwent evaluation for haematuria were included in this study. The mean age was 65.4 years (range: 17-98), the age distribution is given in figure 1. Males constituted 58.8% (n = 483) and females 41.2% (n = 338).

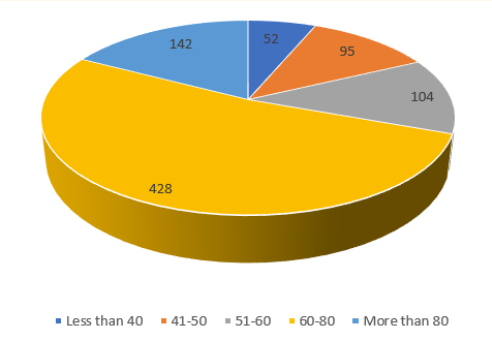


Figure 1: Age distribution of patients.

Of the study cohort, 14% (n = 117) were active smokers, 29% (n = 338) were prior smokers and 57% (n = 466) were non-smokers. 4.2% (n = 35) had a family history of urological malignancies and 1.1% (n = 9) were exposed to environmental carcinogens.

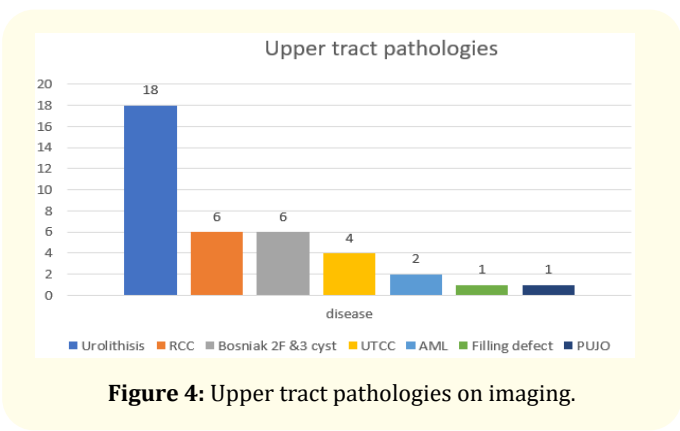
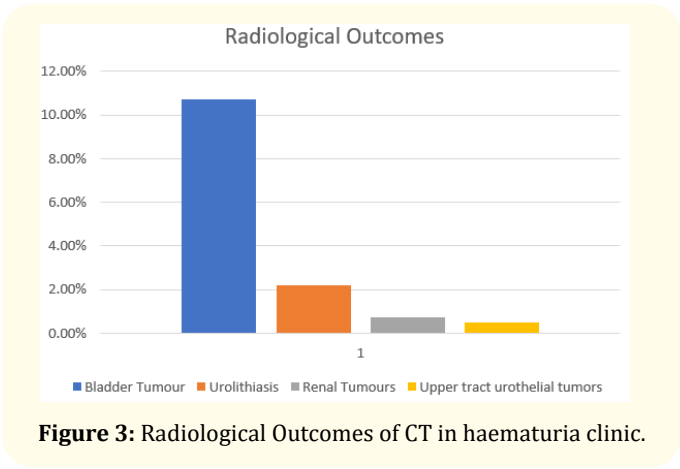
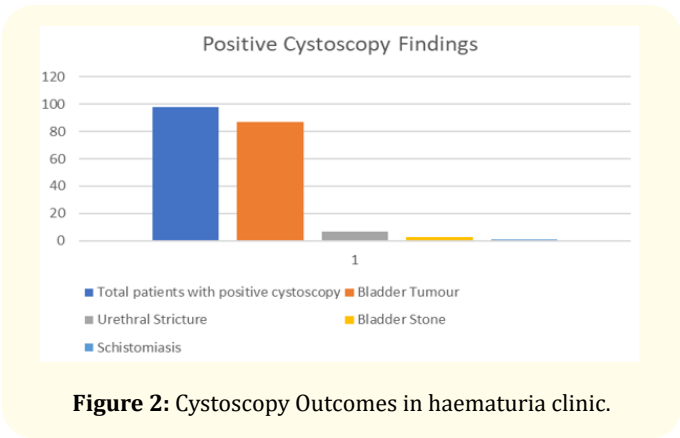
In the study population 65% (n = 535) of patients presented with VH, and 35% (n = 286) NVH. All patients (n = 821) underwent history taking and physical examination, 99% (n = 813) of the patient had flexible cystoscopy, and in less than 1% (n = 8) flexible cystoscopy was not performed due to urethral pathologies i.e., meatal stenosis, urethral strictures, or patient refusal.

Of the study population, 97% (n = 795) had upper tract imaging, of which 15% (n = 123) had only ultrasound scan, 84.65% (n = 673) had CTU and 46.6% (n = 371) had Ultrasound scan and CTU both.

Endoscopy and imaging results

In our cohort, 12% (98/815) of patients who underwent flexible cystoscopy had positive findings, and the most common finding was bladder tumour in 88.7% (87/98). Figure 2 shows the positive diagnostic findings of cystoscopy. 89.6% of patients who were diagnosed with bladder tumours presented with VH, compared to 10.4% for NVH.

Figure 3 shows the over all results of imaging. Bladder tumour was the most common pathology detected on imaging, followed by urolithiasis. 4.8% (38/795) of patients who underwent imaging were found to have upper tract pathologies. Figure 4 shows upper tract imaging findings in our cohort of patients. The most common finding was urolithiasis in 47% cases (18/38). CT scan had high diagnostic accuracy in detecting upper tract pathologies (38/38). 16 patients had malignant or pre-malignant lesions in the upper tracts and 15/16 presented with VH. One patient with suspected RCC presented with NVH, it was detected on ultrasound and confirmed on CTU.



In our cohort, 17 out of 38 patients with upper tract abnormalities detected on CTU also had ultrasound scans. In 16 patients, ultrasound findings were consistent with CT findings, giving diagnostic accuracy of 93% for the ultrasound. Seven patients had renal stones, six patients had renal parenchymal lesions and 4 patients had hydronephrosis. Out of 4 patients with hydronephrosis, 02 had ureteric stones, one had TCC and one was diagnosed with PUJ obstruction. One filling defect which was missed on ultrasound was detected on CTU and subsequent ureteroscopic biopsies of the filling defect showed benign histology.

Sixteen patients had malignant or premalignant upper tract lesions, of those 93.7% presented with visible haematuria and 50% of them were smokers or prior smokers and none of them was under the age of 50.

Discussion

Haematuria is one of the commonest urological symptoms. It has been reported that the risk of urinary tract malignancy in patients with NVH is about 20%, but typically ranges between 14-20% [13]. The risk of detecting urinary tract malignancy in patients with NVH is much lower as compared to VH and it is estimated to be 3.3% for bladder cancer, 0.58% for RCC and 0.17 for upper tract urothelial cancers (UTCC) [4,13]. A recent UK base prospective observational study has shown an even lower incidence of upper tract involvement in patients with NVH. This study showed patients with NVH had a 2.7%, 0.4 and 0% risk of bladder, renal and UTUC respectively [6].

Cystoscopy is the gold standard investigation for the evaluation of bladder in haematuria patients [10]. Although it is an invasive diagnostic procedure, none of the radiological tools or biomarkers is sufficiently reliable to replace cystoscopy [14]. It has the highest sensitivity and specificity for detecting bladder growth and the sensitivity improves further in experienced hands. Because of the lack of high-quality scientific evidence, there are no consistent guideline recommendations for the choice of upper tract imaging for the evaluation of haematuria, especially asymptomatic NVH. AUA guidelines recommend CTU in all adults with haematuria whether it is visible or NVH, on the other hand, UK-NICE guidelines and Canadian consensus document do not specify which imaging modality to use for upper tract imaging [7,15].

In our retrospective review of 821 patients referred to our dedicated haematuria clinic, patients with VH had a higher incidence of urological malignancies as compared to NVH (11.4% vs 1.2%). Bladder tumour was the most common malignancy found in 10.59% of cases (n = 87) and 90% of bladder tumour patients presented with VH, compared to 10% who had NVH. A total of 6 renal cell carcinoma, 4 upper tracts transitional cell cancer, and 6 Bosniak 2F-3 cysts were diagnosed.

The incidence of upper tract premalignant and malignant lesions in our cohort study was 1.94%, and 93.7% of these patients presented with VH compared to 6.3% who had NVH.

The appropriate workup for NVH remains debatable. DETECT study concluded that the CTU can be safely replaced with ultrasound for patients with NVH, as the incidence of upper tract tran-

sitional cell carcinoma is very low [6]. Our study results were consistent with the DETECT study.

CTU and ultrasound can pick large bladder growths when examined with a full bladder. Both CT and ultrasound can miss small bladder growth which is picked up on cystoscopy. The role of cytology is controversial and most of the guidelines do not recommend its use in initial investigations [16]. It has its role in persistent haematuria with previous negative evaluations.

CTU has the highest sensitivity and specificity in detecting upper tract lesions [17]. However, it is associated with significant radiation exposure ranging between 4 to 15 millisievert depending on technique and machine used. It can be associated with radiation-induced malignancies and fatalities [18]. It has a small but significant risk of anaphylaxis and contrast nephropathies, especially in patients with compromised renal function [19]. It is also costly and is associated with delays due to long waiting lists.

In our review 93.7% of patients with upper tracts lesions presented with VH and only 6.3% had NVH. It indicates a very low incidence of upper tract pathologies in patients with NVH.

Also, in our cohort, all patients who had upper tract malignancy were 50 years of age and above and 50% of them were smokers or prior smokers.

Recent studies and systemic reviews have suggested US-KUB as adequate imaging for the upper tract evaluation in patients with NVH [20]. US-KUB has good very sensitivity for renal parenchymal lesions but has low sensitivity for detecting UTUC. As the prevalence of UTUC is less than 1% which is well below the UK national institute of health and care (NICE) criteria of 3% for evaluation, renal USS could be a safe and cost-effective investigation for upper tract imaging in patients with NVH.

Conclusion

Our findings suggest that the incidence of Upper tract malignancy in patients with NVH is low. Only one patient who was referred to NVH had renal cell cancer on ultrasound, which was confirmed with CTU. None of the patients with NVH had upper tract transitional cell cancer. Based on these findings we recommend that patients with NVH be evaluated with history, physical examination, flexible cystoscopy, and ultrasound scan. If no abnormalities were detected on the ultrasound scan, CTU can be safely omitted. This prevents the overwhelming use of CTU which benefits patients by reducing radiation hazards, the anxiety of waiting for the CTU results and reducing the cost of health services.

Bibliography

1. Mariani AJ, et al. "The significance of adult hematuria: 1,000 hematuria evaluations including a risk-benefit and cost-effectiveness analysis". *Journal of Urology* 141 (1989): 350-355.
2. Khadra MH, et al. "A prospective analysis of 1,930 patients with hematuria to evaluate current diagnostic practice". *Journal of Urology* 163.2 (2000): 524-527.
3. Lippmann QK, et al. "Evaluation of microscopic hematuria and risk of urologic cancer in female patients". *American Journal of Obstetrics and Gynecology* 216.2 (2017): 146.e1-146.
4. Rai BP, et al. "Systematic Review of the Incidence of and Risk Factors for Urothelial Cancers and Renal Cell Carcinoma Among Patients with Haematuria". *European Urology* 82.2 (2022): 182-192.
5. Chlapoutakis K, et al. "Performance of computed tomographic urography in diagnosis of upper urinary tract urothelial carcinoma, in patients presenting with hematuria: systematic review and meta-analysis". *European Journal of Radiology* 73 (2010): 334-338.
6. Tan WS, et al. "Who Should Be Investigated for Haematuria? Results of a Contemporary Prospective Observational Study of 3556 Patients". *European Urology* 74.1 (2018): 10-14.
7. Barocas DA, et al. "Microhematuria: AUA/SUFU Guideline". *Journal of Urology* 204.4 (2020): 778-786.
8. Jefferies ER, et al. "Urological recommendations from the National Institute for Health and Care Excellence (NICE) Guideline, June 2015: Suspected cancer: recognition and referral". *BJU International* 117.6 (2016): 857-860.
9. Horie S, et al. "Japanese guidelines of the management of hematuria 2013". *Clinical and Experimental Nephrology* 18.5 (2014): 679-689.
10. Blick CG, et al. "Evaluation of diagnostic strategies for bladder cancer using computed tomography (CT) urography, flexible cystoscopy and voided urine cytology: results for 778 patients from a hospital haematuria clinic". *BJU International* 110.1 (2012): 84-94.
11. Todd Yecies, et al. "Risk of Radiation from Computerized Tomography Urography in the Evaluation of Asymptomatic Microscopic Hematuria". *Journal of Urology* 200.5 (2018): 967-972.

12. Parikh RB., *et al.* "Getting Real about Health Care Costs - A Broader Approach to Cost Stewardship in Medical Education". *The New England Journal of Medicine* 376.10 (2017): 913-915.
13. Jubber I., *et al.* "Non-visible haematuria for the Detection of Bladder, Upper Tract, and Kidney Cancer: An Updated Systematic Review and Meta-analysis". *European Urology* 77.5 (2020): 583-598.
14. Duquesne I., *et al.* "The contemporary role and impact of urine-based biomarkers in bladder cancer". *Translational Andrology and Urology* 6.6 (2017): 1031-1042.
15. Linder BJ., *et al.* "Guideline of guidelines: asymptomatic microscopic haematuria". *BJU International* 121.2 (2018): 176-183.
16. Mishriki SF., *et al.* "Routine urine cytology has no role in hematuria investigations". *Journal of Urology* 189.4 (2013): 1255-1258.
17. Rud E., *et al.* "Examining the upper urinary tract in patients with hematuria-time to revise the CT urography protocol?". *European Radiology* 30.3 (2020): 1664-1670.
18. Yecies T., *et al.* "Risk of Radiation from Computerized Tomography Urography in the Evaluation of Asymptomatic Microscopic Hematuria". *Journal of Urology* 200.5 (2018): 967-972.
19. Aycock RD., *et al.* "Acute Kidney Injury After Computed Tomography: A Meta-analysis". *Annals of Emergency Medicine* 71.1 (2018): 44-53.
20. Smith MR., *et al.* "Evaluation of Asymptomatic Microscopic Hematuria by Renal Ultrasound to Detect Upper Tract Malignancy: A 20-Year Experience in a Community Hospital". *Urology* 133 (2019): 34-39.