

Malignant Melanoma of AnoRectum

Seema Devi^{1*}, Abhishek Kumar² and P Minakshi³

¹Additional Professor, Department of Radiation Oncology, IGIMS, Patna, India

²PG 3rd Year, Department of Radiation Oncology, IGIMS, Patna, India

³PG 1st Year, Department of Radiation Oncology, IGIMS, Patna, India

***Corresponding Author:** Seema Devi, Additional Professor, Department of Radiation Oncology, IGIMS, Patna, India.

Received: March 24, 2023

Published: March 28, 2023

© All rights are reserved by **Seema Devi, et al.**

Abstract

Melanoma develops from pigment containing cells. Melanocytes commonly occurs in skin. Commonly it occurs on the legs in females and on the back in the males [1]. Melanoma of anorectum is a rare disease constitutes only 0.5% to 4% of the all malignancies of anorectal malignancies with very poor prognosis, 10 to 19 months after surgical operations. A 32-year female presented with chief complaint of continuous rectal bleeding for last 1 year. Colonoscopy shown sessile growth extending from 8 to 12 O'clock with irregular surface 2cm from anal verge, seen up to caecum. All melanoma originates from derivative of neural crest, During foetal development melanocytes migrated in different sites of the body like skin, retina, uveal tract and mucosal surface [4,5]. 90% of melanoma are cutaneous melanoma. Many studies recommended systematic chemotherapy and radiation. Chemotherapy agents like cisplatin, vinblastine, dacarbazine. Interferon alpha and interleukin 2 are shown efficacy against melanoma [13] Ano Rectal melanoma is a rare disease and having poor prognosis. Patient may ignore the symptoms as having haemorrhoids, fistula due to symptoms like bleeding per rectum, pain during defecation. Biopsy should be followed by Immunohistochemistry examination for confirmation of diagnosis. Surgical approach, radiotherapy, chemotherapy can be considered depending on extent of the disease.

Keywords: Anorectum; Melanoma; Melanocytes

Melanoma develops from pigment containing cells. Melanocytes commonly occurs in skin. Commonly it occurs on the legs in females and on the back in the males [1]. Melanoma of anorectum is a rare disease constitutes only 0.5% to 4% of the all malignancies of anorectal malignancies with very poor prognosis, 10 to 19 months after surgical operations [2]. AnoRectal malignant melanoma spread along submucosal plane so it is sometimes difficult to be considered an effective approach [3].

Case Report

A 32-year female presented with chief complaint of continuous rectal bleeding for last 1 year. She was consulting in her local area where colonoscopy, biopsy has been done. On PR examination

polypoidal growth felt above 2cm of anal verge which bleeds on touch, upper limit was not reachable. She was operated 1 year back for haemorrhoids.

Colonoscopy shown sessile growth extending from 8 to 12 O'clock with irregular surface from anal verge, of 2cm to caecum.

Contrast-Enhanced Computed Tomography (CECT) whole abdomen shown. An irregular heterogeneously enhancing lesion of size 9x7.7x7.2cm noted in ureterovesical region involving uterine cervix and vagina. The uterus is displaced superiorly and posteriorly. The lesion is infiltrating anterior rectal wall for a length of 5.6cm with intraluminal extension and anal canal. The fat plane

lost with posterior wall of urinary bladder. Urinary bladder is partially distended with Foley's *in situ*. The lateral aspect of the lesion is closely abutting bilateral internal iliac vessels and loss of fat plane with right obturator internus. The lesion is infiltrating right ischioecoegygeus muscle. Multiple enlarged heterogeneously enhancing lymph node in right external iliac (2 cm) and left internal iliac (2.6 cm). Multiple discrete subcentimetric Lymph nodes in left common iliac aortocaval and paraaortic regions. Enlarged right presacral lymph nodes of 5mm size.




Figure 1: Coronal section of CT scan showing tumor size.

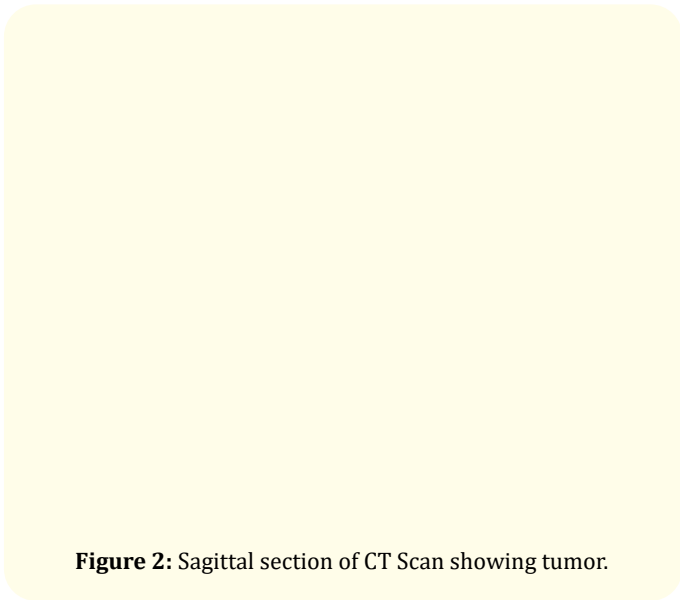


Figure 2: Sagittal section of CT Scan showing tumor.

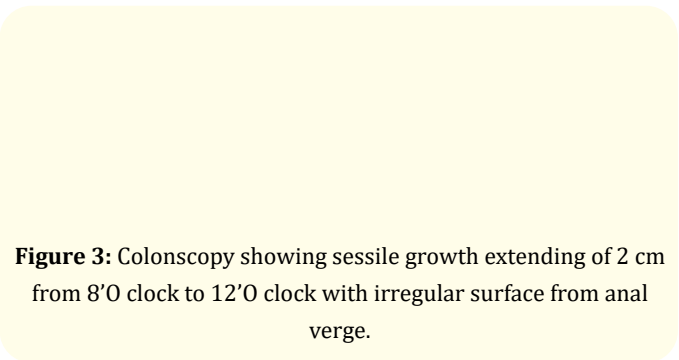


Figure 3: Colonscopy showing sessile growth extending of 2 cm from 8'O clock to 12'O clock with irregular surface from anal verge.

USG whole abdomen and X-Ray chest were normal, no evidence of metastasis is seen. Biopsy examination shown alveolar sarcoma and advised immuno histo chemistry.

Morphology

Section shows ulcerated mucosa with a tumor composed of sheet, nodules, and masses of atypical polygonal cells. Tumor cells are spindle to oval with irregular nuclear margins, coarse dark chromatin, a prominent amphophilic nucleolus and small to moderate amount of pale cytoplasm. Necrosis is present. Foci of mitotic figures are appreciated.

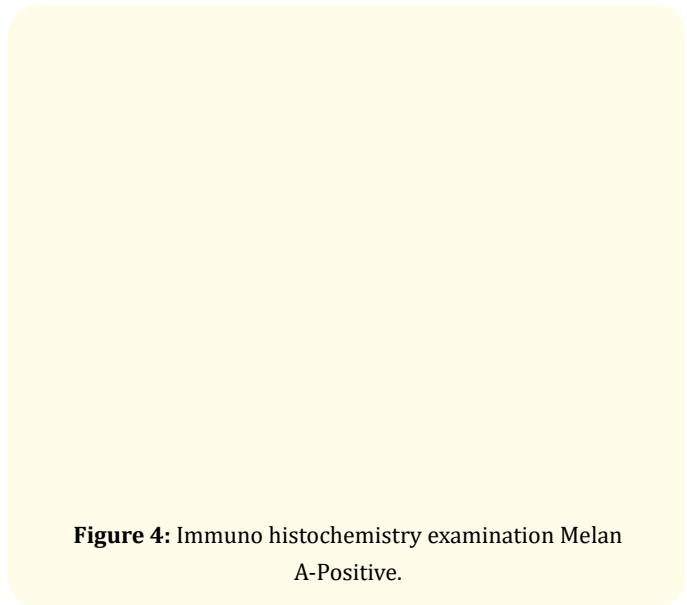


Figure 4: Immuno histochemistry examination Melan A-Positive.

Figure 5: Immuno histochemistry examination Ki 67-40%.

Figure 6: Immuno histochemistry examination
HMB45-Positive.

Figure 7: Immuno histochemistry examination S100 Diffused
positive.

Discussion

All melanoma originates from derivative of neural crest, during foetal development melanocytes migrated in different sites of the body like skin, retina, uveal tract and mucosal surface [4,5]. Most common melanoma are cutaneous melanoma 90%. In other 10% of melanoma ocular melanoma contributes about 5%, 2% melanoma of unknown origin, mucosal melanoma contributes only 1% [5]. In the rectum melanocytes are found at transition zone and squamous zone. About 65% of AnoRectal melanoma are located within anal canal and at anal verge usually they are far from the deviation line [3,5]. The disease usually starts from 4th decade. In female incidence increases in 5th and 6th decade of life [6]. Common presenting symptoms may be bleeding per rectum, feeling of mass or discomfort altered bowel habits, other symptoms may be tenesmus, pruritis, prolapsed hemorrhoids. In metastatic presentation weight loss, anaemia, fatigue may be additional symptoms [3,5], Lesion commonly present at anorectum followed by anal canal and anal verge [7]. Colonoscopy is required for evaluation and biopsy from lesion. Endoscopic anorectal ultrasound may be used for evaluation of size, depth and nodal status [3]. Contrast enhanced CT scan or MRI are useful for assessment of tumor and metastasis. Study show that CT scan was used to diagnose primary melanoma of rectum, the finding was bulky, extraluminal, fungating masses to distal rectum, expanding and narrowing the lumen without obstruction with perineal infiltration and enlarged lymph nodes [8]. Patient was initially diagnosed as alveolar type of sarcoma. After immuno histochemistry diagnosis confirmed as melanoma. Generally surgical examination is considered as a primary treatment. Standard operation for anorectal melanoma is offered abdomino perineal resection. It can ensure safer resected margin and contract of lymphatic spread. In smaller tumor wide local examination can be considered. Study reported that aggressive treatment of primary anorectal lesion with APR associated with improved outcome. 5 year disease free survival was better in patient s offered APR than treated with local procedures only. Another study shown majority of patients treated with APR prior to 1997 and patients underwent local examination, there was no difference in 5-year survival rate [9].

Study done in Swedish National Cancer registry with 251 patients shown same median survival with patients undergo APR and local examination. Overall, 5-year survival rate was 11.2%

[10,11]. Retrospective studies shown a statistically significant improvement in local regional control in patients s treated with APR than local excision alone (74% VS 34%) [6] without radiotherapy.

Recent studies shown that sphincter saving local examination with adjacent loco regional radiotherapy to primary tumor and regional lymph node achieved same locoregional control as compared to APR 70% vs >74% [12].

Conclusion

Many studies recommended systematic chemotherapy and radiation. Chemotherapy agents like cisplatin, vinblastine, dacarbazine. Interferon alpha and interleukin 2 are shown efficacy against melanoma [13]. Other combinations like “Dartmouth regimen” includes dacarbazine, Cisplatin, Carmustine and Tamoxifen study shown increase in response rate with this region although it was not statistically significant [14]. Ano Rectal melanoma is a rare disease and having poor prognosis. Patient may ignore the symptoms as having haemorrhoids, fistula due to symptoms like bleeding per rectum, pain during defecation. Biopsy should be followed by Immunohistochemistry examination for confirmation of diagnosis. Surgical approach as radiotherapy, chemotherapy can be considered depending on extent of the disease.

Bibliography

1. Slingluff CI Jr., *et al.* “Cutaneous melanoma”. In: DeVita VT Jr, Lawrence TS, Rosenberg SA, editors. *Cancer: principles and practice of oncology*. 9th ed. Philadelphia (PA): Lippincott Williams and Wilkins (2011): 1643-1691.
2. Brady MS., *et al.* “Anorectal melanoma. A 64-year experience at Memorial Sloan-Kettering Cancer Center”. *Diseases of the Colon and Rectum* 38 (1995): 146-151.
3. Stefanou A and Nalamati SP. “Anorectal Melanoma”. *Clinics in Colon and Rectal Surgery* 24 (2011): 171-176.
4. Singer M and Mutch MG. “Anal melanoma”. *Clinics in Colon and Rectal Surgery* 19 (2006): 78-87.
5. Row D and Weiser MR. “Anorectal melanoma”. *Clinics in Colon and Rectal Surgery* 22 (2009): 120-126.
6. Van Schaik PM., *et al.* “Melanoma of the rectum: A rare entity”. *World Journal of Gastroenterology* 14 (2008): 1633-1635.
7. Slingluff CL Jr., *et al.* “Anorectal melanoma: Clinical characteristics and results of surgical management in twenty-four patients”. *Surgery* 107 (1990): 1-9.
8. Kim KW., *et al.* “Primary malignant melanoma of the rectum: CT findings in eight patients”. *Radiology* 232 (2004): 181-186.
9. Yeh JJ., *et al.* “The role of abdominoperineal resection as surgical therapy for ano-rectal melanoma”. *Annals of Surgery* 244 (2006): 1012-1027.
10. Prichard RS., *et al.* “Positron emission tomography for staging and management of malignant melano-ma”. *British Journal of Surgery* 89 (2002): 389-396.
11. Nilsson PJ and Ragnarsson-Olding BK. “Importance of clear resection margins in anorectal malignant melanoma”. *British Journal of Surgery* 97 (2010): 98-103.
12. Ballo MI., *et al.* “Sphincter-sparing local excision and adjuvant radiation for anal-rectal melanoma”. *Clinical Oncology* 20 (2002): 4555-4558.
13. Wilson MA and Schuchter LM. “Chemotherapy for melanoma”. *Cancer Research and Treatment* 167 (2016): 209-229.
14. Chapman PB., *et al.* “Phase III multicenter randomized trial of the Dartmouth regimen versus dacarbazine in patients with metastatic melanoma”. *Journal of Clinical Oncology* 17 (1999): 2745-2751.