



Role of Fibroblast Activated PET-CT Scan to Evaluate Response to Eribulin in HER2 NEU Positive Metastatic Breast Cancer- A Case Report

Sweekruti Hegde, Ayesha Mahajan, Kruthikaa, Vinayak M, KG Kallur, Prasanth, BS Ajaikumar, Radheysham Naik and G Lohith*

Department of Radiation Oncology, Healthcare Global Hospital, Bangalore, India

***Corresponding Author:** G Lohith, Department of Radiation Oncology, Healthcare Global Hospital, Bangalore, India.

Received: August 19, 2020

Published: October 20, 2020

© All rights are reserved by **G Lohith, et al.**

Abstract

We hereby report a case of a 44 year old female with invasive ductal carcinoma of left breast with metastasis to subcarinal and supraclavicular lymph nodes, right lung and left adrenal gland. She was diagnosed with fibroblast activated PET-CT and biopsy. Her PET-CT was done prior to chemotherapy and post chemotherapy and is further discussed in the report. She was operated (BCS) and received eribulin after a TCH regimen which showed regression of tumor in the fibroblast activated PET-CT.

We further discuss how the fibroblasts in the cancer stroma is involved in the radionuclide based diagnosis of cancer. The presence of fibroblasts only in the tumor tissue that defines its accuracy in the cancer diagnosis. Eribulin is a microtubule inhibitor and reverses the epithelial mesenchymal transformation and hence is a effective drug in the treatment of different types of cancer. Eribulin has an effect on the cancer associated fibroblast that helps to use fibroblast activated PET CT as a method to measure the efficacy of Eribulin treatment in the breast cancer.

Keywords: Fibroblast; PET-CT Scan; Eribulin; HER2 NEU; Metastatic Breast Cancer

Introduction

Diagnosis from case report- invasive ductal carcinoma of left breast with metastasis to subcarinal lymph nodes, supraclavicular lymph nodes, right lung and left adrenal.

Case Report

44year old female complained of lump in the left breast for which she underwent a FNAC IN 2018 which was positive for malignancy. Her PETCT study showed 29 x 23 x 30 mm (SUV-8) metabolically active lesion in the upper outer quadrant of left breast that represented primary neoplasm. She underwent breast conserving surgery with sentinel lymph node biopsy. Operative HPE showed invasive duct carcinoma left breast (3.5 X 3 X 3 Cm) with uninvolved sentinel lymph nodes, stage- p T2NOMO, lymphovascular emboli present, ER-ve/PR-ve/Her2 Neu 3+/Ki6767%. Post BCS

she received 6 cycles of TCH regimen (docetaxel, carboplatin, Herceptin) followed by radiation therapy to breast and again 17 cycles of injection Herceptin which completed in april 2019.

She underwent a PETCT in December for her regular follow up which showed a nodule in medial basal segment of lower lobe of right lung (1.4 X 1.3 cm, SUV-4.6) along with subcarinal nodes (1.7 X 1.4 cm, SUV-8.8) and uptake in left adrenal glands (0.9 X 0.8 cm, SUV-3.2). Her core biopsy from lung showed metastatic carcinoma with ER-ve/PR-ve/Her2 Neu+ve and was started on TDM-1 regimen in January. Genetic testing showed intact nuclear expression of MLH1, MSH2, MSH6 and low probability of MSI-H, MUC4-ve and EGFR-weakly positive.

Fibroblast activated PET CT was done which showed (PRE INJ ERIBULIN STATUS) showed metabolically active enhancing cutane-

ous nodule in left periareolar region (SUV-4.1), metabolically active left supraclavicular nodes (SUV-7.4), increase in size of pulmonary nodule in lower lobe of right lung (largest measuring 1.9 cm, SUV-10.8) with regression of size of subcarinal nodes (1.7 cm X 1.1 cm, SUV-10.8) and left adrenal nodule, suggestive of local, nodal and distal recurrence.

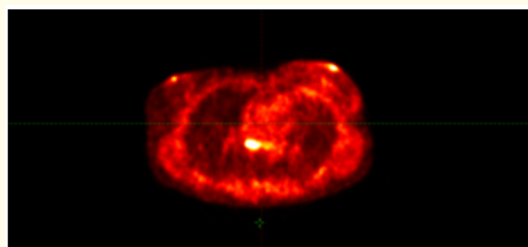


Figure 1: PET CT done before chemotherapy with eribulin.

She was started on Inj Eribulin 2 mg and Inj Trastuzumab 360 mg on 11.02.2020 for 8 days X 8 cycles which she completed on 18.07.2020.

Her PET CT evaluation done on 22.6.2020 showed regression in the size of cutaneous nodule in left periareolar region (SUV-3.8), left supraclavicular lymph nodes (SUV-nil), pulmonary nodule (SUV- nil), subcarinal lymph nodes (suv-nil).

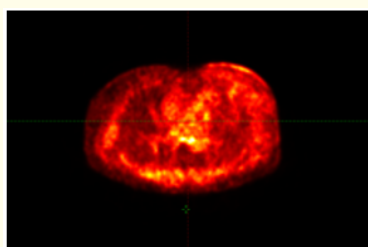


Figure 2: PET CT done after chemotherapy with eribulin.

Discussion

Diagnosis from case report- invasive ductal carcinoma of left breast with metastasis to subcarinal lymph nodes, supraclavicular lymph nodes, right lung and left adrenal.

Breast cancer is the second most common carcinoma in females amongst which most common pathological variant observed is invasive ductal carcinoma (NOS Type) which constitute about 76% of

the total breast carcinoma cases. Amongst them HER2 positive estimates were 19% for women aged < 49 years and 15% for women aged more than 50 years.

A study showed that 10 - 23% of women diagnosed with HER2 positive cancer had a recurrence rate of 10 to 23% within 5 years of diagnosis than women diagnosed with HER2 negative cancer. HER2 positive women also had 5 times more risk of metastatic recurrence than women diagnosed with HER2 negative cancer. Tumors larger than 2 cm, lymph node metastasis and HER2 positive were associated with early recurrence whereas HER2 negative, PR+, ER+ were associated with late recurrence.

ERIBULIN- halichondrin B (eribulin) was isolated from the sea sponge *Halichondria okadai* in 1986. Eribulin suppresses microtubule growth and decreases microtubule dynamicity overall. Eribulin also induces mitotic accumulation with aberrant mitotic spindle dynamics, demonstrating an ability to affect overall microtubule. Eribulin reverses EMT in cultured human triple-negative breast cancer cells. In a gene expression profiling study, eribulin downregulated 13 genes related to EMT in breast cancer cell lines. Overall response rate was 24%. Clinical benefit rate was 35.4%. At a median follow-up of 29.6 months (8.3 - 41.9) the median progression free survival was 3.3 months, and the median overall survival 11.6 months. For her2 positive patients the overall response rate (complete response [CR] + partial response [PR]) was 80.0%, and the clinical benefit rate (CR + PR + stable disease ≥ 24 weeks) was 84.0%.

Regulation of EMT pathway genes may serve as a biomarker for response to eribulin because breast cancer patients who over-expressed these genes were sensitive to eribulin, among patients responding to this drug, the microRNA signature showed downregulation of genes involved in the cell cycle, cell survival and apoptosis, as well as upregulation of genes involved in growth arrest, suppression of cancer cells and metastasis, and modulation of chemoresistance.

Fibroblast activated PET CT - cancer associated fibroblasts have a role in migration, metastasis, immunosuppression and resistance to chemotherapy, hence it is used for targeting imaging and therapy. Activated fibroblasts in tumor cells express fibroblast activation protein that is required for normal development during embryogenesis and tissue modelling. FAP is overexpressed in cancer cells and therefore acts as a target for radionuclide based diagnosis of

malignant tumors. PET/CT requires a radiotracer that has high affinity to structures expressed at higher level in tumor cells than normal tissues, hence FAP is used to target different tumor types that includes pancreas, breast, colon, ovarian, liver or lung cancer. Radiolabeled FAP uptake is selective only in tissues where it is expressed and is nil in normal tissues and therefore this has allowed for fast imaging with very high contrast in high stromal content of tumor.

Cancer associated fibroblasts express transforming growth factor beta, vascular endothelial growth factor and hepatocyte growth factor which affect the invasiveness of the cancer. TGF-B is the initiator of epithelial mesenchymal transformation (EMT) and also stimulates CAF proliferation, fibrosis of the stroma and FAP expression on the cell membrane. Eribulin has shown to restrict tgf-beta that eventually reduces CAF proliferation and expression of FAP on cell membrane. hence due to this reduction in fibroblast accumulation in the tumor, fibroblast activated PET CT done after eribulin treatment shows reduction in the uptake in the tumor site. Therefore fibroblast activated PET CT can be taken as a appropriate technique to measure the eribulin’s response in breast cancer [1-7].

Conclusion

This case assures that in patients with invasive ductal carcinoma and HER2 neu positive can be very well treated with eribulin. Eribulin has shown promising results in breast cancers with metastasis with minimal side effects. Its higher response rate and clinical benefit rate has increased the overall survival rate in such patients. Eribulin sensitivity and resistance biomarkers can also be detected via EMT pathway genes and micro RNA signatures.

However, use of this drug in other types of cancer is not widely appreciated and provides scope for further studies.

Fibroblast associated imaging using radiolabeled fibroblast activated protein has shown promising results in detection of malignancies at a faster rate due to its affinity to targeted structure expressed at a greater level in stroma of tumor than normal tissues. Hence there is no uptake in the normal tissues. It has shown promising results in accurate staging and also in accurate evaluation of post therapy response.

Bibliography

1. Gelareh Eslamian., *et al.* “Efficacy of eribulin in breast cancer: a short report on the emerging new data”. *Academic Unit of Oncology* (2017).

2. Erin Olson and D’Anna Mullins. “When Standard Therapy Fails in Breast Cancer: Current and Future Options for HER2-Positive Disease” (2013).
3. Rena Callahan MD and Sara Hurvitz MD. “HER2-Positive Breast Cancer: Current Management of Early, Advanced, and Recurrent Disease”. University of California at Los Angeles, USA (2015).
4. Robbins and Cotran. *Pathological Basis of Disease-8th edition.*
5. Thomas Linder., *et al.* “Targeting of activated fibroblasts for imaging and therapy” (2019).
6. Anastasia Loktev., *et al.* “A Tumor-Imaging Method Targeting Cancer-Associated Fibroblasts” (2018).
7. Toru Kurata., *et al.* “Low-dose eribulin mesylate exerts antitumor effects in gastric cancer by inhibiting fibrosis via the suppression of epithelial–mesenchymal transition and acts synergistically with 5-fluorouracil” (2018): 2729-2742.

Assets from publication with us

- Prompt Acknowledgement after receiving the article
- Thorough Double blinded peer review
- Rapid Publication
- Issue of Publication Certificate
- High visibility of your Published work

Website: www.actascientific.com/

Submit Article: www.actascientific.com/submission.php

Email us: editor@actascientific.com

Contact us: +91 9182824667