



## *Amanita phalloides* in Tumor Therapy: Stabilization of Pharyngeal Squamous Cell Carcinoma (Case Report)

Isolde Riede\*

Independent Cancer Research, Im Amann 7, Ueberlingen, Germany

\*Corresponding Author: Isolde Riede, Independent Cancer Research, Im Amann 7, Ueberlingen, Germany.

Received: January 16, 2019; Published: February 23, 2019

### Abstract

**Background:** Tumor treatments can fail, followed by relapse. In many cases secondary surgery, radiation and chemotherapy is applied. Despite these destructive treatments, tumors can regrow. Alternative treatments are essential.

**Aim:** To determine if *Amanita phalloides* inhibits the growth of squamous cell carcinoma (SCC).

**Method:** A patient with pharyngeal SCC is treated with *Amanita* after failure of conventional treatments with operations and radiations. Initially the standard dose is applied, several times this standard dose is reduced.

**Results:** The disease state of the patient with SCC can be stabilized for five years until now. Two years after beginning *Amanita*, *Borrelia* infection is diagnosed, and additional treatment with Terebinthina laricina occurs. *Amanita* dose can then be reduced after three years of treatment, indicating a reduction of tumor cells. A scintigram in 2014, and a MRI in 2018 show no evidence for a tumor.

**Conclusions:** *Amanita* can inhibit tumor growth of squamous cancer cells. *Borrelia* possibly supports their tumor growth.

**Keywords:** *Amanita phalloides*; Squamous Cell Carcinoma; *Borrelia*

### Introduction

SCC is the most common type of neoplasia which affects the mucosa of the upper aero-digestive tract. Recently a number of publications were released, indicating infectious agents being involved with the tumor: *Helicobacter pylori* as causative factor in gastric carcinogenesis, was found in the tumor of around 50 % of oesophagus SCC patients [1], however, a prevalence similar to that of the general population. Human Papilloma Virus was found in head and neck SCC [2], but not in oesophageal verrucous carcinoma [3]. It could be identified in SCC of the larynx [4]. The prevalence of Hepatitis C Virus is higher in head and neck cancer patients than in the population, indicating it as a risk factor for the disease [5]. Epstein Barr Virus is as well present in SCC tumors, whereas other herpes virus like CytoMegalie Virus, Human Herpes Virus -6, -7 or -8 are minimally or not present [6].

A genetic and molecular study identified the central potential targets for therapeutic intervention in tumor cells: switch genes. In tumor cells the switch genes are over-expressed [7,8]. This switches the growth of tumors to ON. All switch genes belong to the class

of HOX genes, and use RNAP for their action. If the switch genes are over expressed, RNAP is used to full extent, creating a bottleneck for tumor growth. The extract of *Amanita* contains amanitin, inhibiting RNAP. Inhibition of 50% of RNAP inhibits tumor growth of cells but has no effect on normal cells. Growth inhibited tumor cells can be recognized by the immune system and digested. Through this approach it is possible to stabilize the state of disease for years.

### Method

Dilutions of *Amanita phalloides* are used since 300 years, the classical indication is fear of death. After anamnesis the patient is treated with *Amanita phalloides* (zert. Riede) D2 [Herbamed AG, CH]. In a standard procedure the dose is 4 x 10 drops per day, resulting in an average uptake of 50 ml per month. The daily dose contains about 150 molecules of amanitin per cell. With 100 ml of this drug, about 50% of all RNAP molecules in all cells are inhibited [7]. Usually no side effects occur. The therapy is monitored. Usually a tumor marker is measured, and degradation of cells is monitored with lactate-dehydrogenase (LDH) levels in serum. Successful treatments of mammary carcinoma, thyroid cancer, colon cancer,

prostate cancers or B cell leukemia have been described [7]. Only in rare cases, the dose of *Amanita* can be reduced. In most cases the original standard dose is necessary. In all patients, in addition to *Amanita* as the only tumor specific drug, the oral uptake of essential fatty acids is indicated. Essential fatty acids enhance the fluidity of cellular membranes, and decrease the risk of autoimmunity.

**Patient and pre-treatments**

The patient was born in 1952. He carries a familial disposition for cancer: his father suffered a bladder tumor at the age of 50, his mother got lung cancer at the age of 77 and his grandfather died from lung cancer. In his youth he had a tonsil surgery. He suffered from gout. He cannot remember a tick bite, but his wife had several.

In July 2011, keratinizing SCC in the pharynx was diagnosed. At histopathological examination, the fragments of tumor biopsy revealed the aspect of a moderately differentiated SCC, with invasion in the adjacent fibro-muscular tissue and 19 tumor free lymph nodes. It was classified as T2 N0 M0 G1-2 R0. After operations, 33 X-radiations occurred.

In July 2013 relapse was diagnosed. The histopathological examination revealed a moderately differentiated keratinizing and necrotic SCC in the pharynx. Operation occurred with the help of a laser. Six tumor free lymph nodes were removed. The lesion was covered with skin from the arm. End of July 2013, the perished cover was replaced by a new cover from the leg. In July 2013 a scintigram of the skeleton revealed no suspicious metastases, only degenerative processes. Computer tomography and MRI of the head, and radiograph of the thorax were negative. From August 2013 on, Thyroxin 100 µg daily was applied, the X-radiation had destroyed part of the function of the thyroid gland. Ramipril was applied in 5 mg daily and Pantoprazole was given. Renal colic with fever occurred, and analgesic were given. Table 1 summarizes some laboratory parameters of this time.

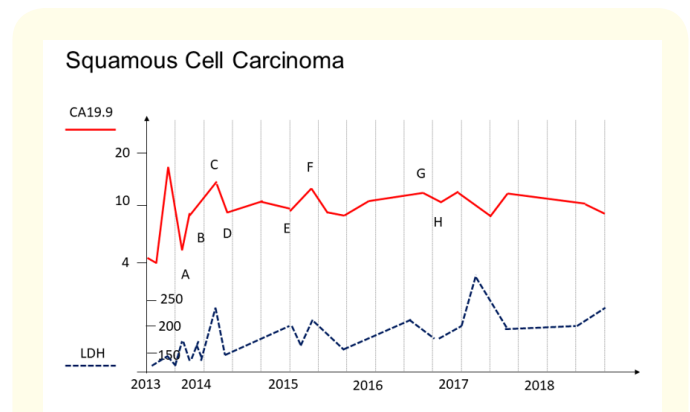
	CRP	TSH	fT3	fT4
<b>Standard</b>	<b>&lt; 10 mg/l</b>	<b>0.27 - 2.5 µU/ml</b>	<b>0.18 - 0.46 ng/dl</b>	<b>0.85 - 1.7 ng/dl</b>
2.8.13	215	25	0.11	0.43
3.8.13	123			
4.8.13	78			
5.8.13	62	25	0.12	0.51
7.8.13	64	23	0.51	0.56

**Table 1:** Laboratory parameters before the amanita therapy.

After the operations in 2013 the patient suffered an infection, with high CRP levels, that slowly decreased. Elevated TSH levels show a thyroid gland sub-function.

**Amanita therapy**

End of August 2013 *Amanita* therapy starts with the standard dose of 4 x 10 drops daily. Monitoring occurred with CA19.9 and LDH (Figure 1). The patient gets fever and ague from a summer influenza, CRP level are high. Within a month, CA19.9 dropped from 5.2 to 4.4 E/ml, showing the growth arrest of tumor cells. LDH increased from 138 to 143 U/ml, showing degradation of cells. These two signs show the success of *Amanita*: end of tumor growth and degradation of cells. The parameters in following five years are outlined in figure 1: CA19.9 and LDH are alternatively growing or diminishing. In October 2013, CA19.9 increases dramatically. This happens often in the beginning of the *Amanita* therapy, the patient sometimes forgets about his daily dose. Operation of the tracheostoma occurs in January 2014. In February 2014 the *Amanita* dose is reduced to 2 x 10 (20) drops per day (Figure 1A). A scintigram of the skeleton shows no metastases. The patient is sportive again. In March 2014, the dose is corrected to 40 drops daily because of increasing CA19.9 (B). Further increasing CA19.9 in May 2015 leads to a dose of 80 drops daily (C). Decrease of CA19.9 leads to a daily dose of 40 drops (D). In March 2015 a decrease leads to a daily dose of 30 drops (E), which was not successful, the tumor marker rises again. In May 2015 the dose was corrected to 40 drops daily (F).



**Figure 1:** Tumor marker and LDH during Amanita therapy. Outlined are CA19.9 [E/ml] (red line) and LDH [U/ml] (blue broken line).

A: Reduction of Amanita dose to 2 x 10 (20) drops per day; B: 40; C: 80; D: 40; E: 30; F: 40; G: 20; H: 10. Explanation in the main text.

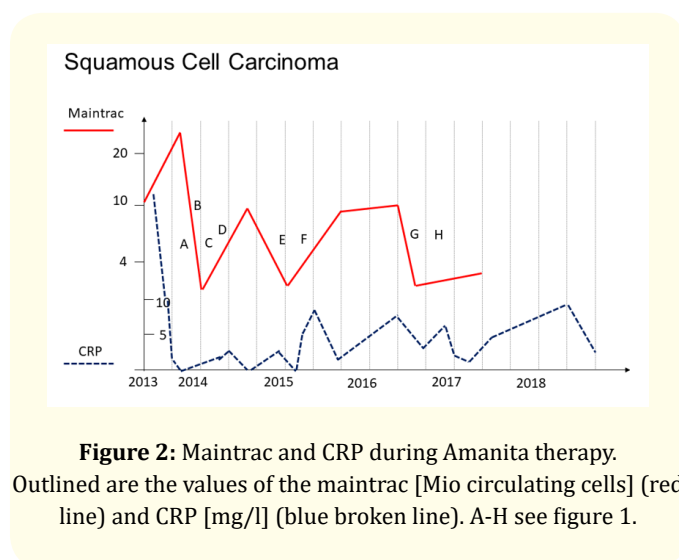
In October 2015 *Borrelia* infection is assumed due to increasing CRP (Figure 2) and symptoms of rheumatism and gout. Terebinthina laricina D1 in 2 x 10 drops per day is applied. Terebinthina is a potent drug to eliminate *Borrelia* [9]. In December 2015 *Borrelia* infection is confirmed by laboratory analysis. Uptake of all together 200 ml of Terebinthina occurs within one year.

In November 2016, due to stable tumor marker values, reduction of the *Amanita* dose is tested again (Figure 1G). This time, stabilization succeeds. In February 2017, the dose can be reduced to

10 drops *Amanita* daily, with stabilization until now. End of 2018 the patient stops *Amanita* therapy. MRI in 2018 shows no signs of a relapse, or metastases.

Because CA19.9 values are low, in addition a second tumor marker, the maintrac values are measured to monitor therapy progress (Figure 2) [10]. Overall, the less frequent maintrac values coincide well with the CA19.9 values in figure 1. Only one time, the values differ (A). After the surgery beginning of 2014, CA19.9 remains low, whereas the maintrac is high.

In the serum of the patient, often high CRP levels occur, indicating an inflammatory burden (Figure 2). The Terebinthina treatment cannot eliminate this phenomenon.



**Figure 2:** Maintrac and CRP during *Amanita* therapy.

Outlined are the values of the maintrac [Mio circulating cells] (red line) and CRP [mg/l] (blue broken line). A-H see figure 1.

### Discussion

*Borrelia* are in discussion to support tumor growth, or even induce it [11]. Here, a patient with SCC is treated with *Amanita* alone. In the beginning, tested dose reductions are not successful: tumor cells regrow. After additional treatment with Terebinthina, dose reduction is successful: tumor cells do not regrow. This could show, that as well in this case, *Borrelia* support the tumor growth. As the patient does not remember a tick bite, but his wife had several, it is possible, that these bacteria can be transmitted directly. Their relatives are *Treponema*, inducing Lues, a sexually transmitted disease, and *Leptospira*, that is transferable over the skin.

CA19.9 und maintrac both are used as tumor markers. Their values coincide well here, with one exception: after surgery the maintrac rises whereas CA19.9 remains low. Maintrac measures circulating epithelial cells in the blood, whereas CA19.9 measures

a cytokeratin, emerging from destroyed tumor cells, in serum. This means that tumor cells are not affected by this surgery, but epithelial cells are freed. This means as well, that after an operation, the maintrac is not a tumor marker of choice.

*Amanita* therapy always is applied at the lowest possible successful dose. For a long time, no resistance of tumor cells occur. Especially for patients with SCC in recurrence, this might be helpful: 5-years survival rate with conventional therapies lies at 20% only [12]. *Amanita* could possibly elongate their life.

### Conclusion

*Amanita phalloides* can break the activity of squamous cancer cells, a disease state of the patient can be avoided. No side effects occur.

### Bibliography

1. Kgomo M., et al. "Prevalence of Helicobacter pylori Infection in Patients with Squamous Cell Carcinoma of the Oesophagus. A Descriptive Case Series Study". *Journal of Gastrointestinal Cancer* 47.4 (2016): 396-398.
2. Khan A., et al. "Detection of human papillomavirus in cases of head and neck squamous cell carcinoma by RNA-seq and Vir-Test". *Molecular Oncology* (2018).
3. Cappelleso R., et al. "Human papillomavirus infection is not involved in esophageal verrucous carcinoma". *Human Pathology* (2018).
4. Hotz MA., et al. "Human papilloma virus-associated squamous cell carcinoma of the larynx in an 18-year-old woman". *Head Neck* (2018).
5. Rangel JB., et al. "Prevalence of hepatitis C virus infection and its impact on the prognosis of head and neck cancer patients". *Oral Oncology* 87 (2018): 138-143.
6. Broccolo F., et al. "Human papillomavirus (HPV) and Epstein-Barr virus (EBV) in keratinizing versus non-keratinizing squamous cell carcinoma of the oropharynx". *Infectious Agents and Cancer* 13 (2018): 32.
7. Riede I. "Switch the Tumor Off: From Genes to Amanita Therapy". *American Journal of Biomedical Research* 1.4 (2013): 93-107.
8. Rozovskaia T., et al. "Upregulation of Meis1 and HoxA9 in acute lymphocytic leukemias with the t(4 : 11) abnormality". *Oncogene* 20.7 (2001): 874-878.
9. Riede I. "Terebinthina laricina in Borreliosis: Comparison with Antibiotic Therapies". *Journal of Homeopathy and Ayurvedic Medicine* 1 (2012): 110.

10. Pachmann K., *et al.* "Quantification of the response of circulating epithelial cells to neoadjuvant treatment for breast cancer: a new tool for therapy monitoring". *Breast Cancer Research* 7.6 (2005): R975-R979.
11. Riede I. "Borrelia infection appears as Chronic Lymphocytic Leukemia: Therapy with *Amanita phalloides* and *Terebinthina loricata* (Case Report)". *British Journal of Medicine and Medical Research* 7.7 (2015): 630-637.
12. Zhou S., *et al.* "Recurrence Risk Based on Pathologic Stage After Neoadjuvant Chemoradiotherapy in Esophageal Squamous Cell Carcinoma: Implications for Risk-Based Postoperative Surveillance Strategies". *Annals of Surgical Oncology* 25.12 (2018): 3639-3646.

**Volume 3 Issue 3 March 2019**

**© All rights are reserved by Isolde Riede.**