

## Metastatic Prostate Adenocarcinoma to the Left Subclavian Lymph Node

Anish J Jain<sup>1</sup>, Desmond Ohiwele<sup>1</sup>, Timothy King<sup>1</sup>, Rhonda Burch-Smith<sup>2</sup>, Adam R Metwalli<sup>1</sup> and Pamela W Coleman<sup>1\*</sup>

<sup>1</sup>Division of Urology, Department of Surgery, Howard University Hospital, Washington, DC, USA

<sup>2</sup>Division of Surgical Pathology, Department of Anatomical and Clinical Pathology, Howard University Hospital, Washington, DC, USA

**\*Corresponding Author:** Pamela W Coleman, Associate Professor, Division of Urology, Department of Surgery, Howard University Hospital, Washington, DC, USA.

**Received:** January 31, 2019; **Published:** February 19, 2019

### Abstract

Metastatic Prostate Cancer (PCa) to the left supraclavicular lymph node has been previously described in the urology literature with a variation of clinical presentations. Although a rare and unusual site of metastasis, it has been reported in several case series as the first site of metastatic PCa, even in patients without documented Prostate Specific Antigen (PSA) elevation. The patient in this case report presented with metastasis to bone, bulky retroperitoneal lymphadenopathy, obstructive renal failure, mediastinal lymphadenopathy, markedly elevated PSA, and a left neck mass which turned out to be metastatic adenocarcinoma of the prostate. Immuno-stains performed on cell block sections of this neck mass showed that the tumor cells were positive for PSA and prostein and negative for CK7, CK20 and CDX2. He was treated with anti-androgen ablation therapy and percutaneous nephrostomy tubes with resolution of kidney failure.

**Keywords:** Prostate Cancer; Metastatic Prostate Cancer; Cervical Lymphadenopathy; Supraclavicular Lymphadenopathy

### Introduction

According to the American Cancer Society, there have been an estimated 174,650 new cases of PCa. It is the second leading cause of cancer death in American men, behind lung cancer, with about 1 man in 41 dying of PCa [1].

PCa generally presents with lower urinary tract symptoms, local invasion to the bone or spinal cord, metastasis to local lymph nodes, and/or with elevated PSA levels. However, PCa has rarely been reported to present initially as cervical or supraclavicular lymphadenopathy. Metastasis to supradiaphragmatic lymph nodes is relatively rare, as PCa usually spreads locally to adjacent pelvic lymph nodes and nearby organs (bladder, rectum, spine) [2]. The incidence rate of PCa metastasis to the supraclavicular lymph nodes is approximately 0.28%, with post-mortem studies showing its prevalence to be close to 1% [3].

### Purpose of the Study

The purpose of this case report is to share our experience as a consult service managing a patient with metastatic PCa to the left supraclavicular node.

### Case Report

A 61-year-old African American male with a history of elevated PSA, left neck mass, chronic obstructive pulmonary disease, and colon cancer, presented to Howard University Hospital's Emergency Room on December 31<sup>st</sup>, 2017 in acute renal failure with symptoms suggestive of fluid overload. He reported worsening shortness of breath for the past few days, productive cough, hemoptysis, abdominal pain, decreasing urination, and incomplete bladder emptying.

He had no relevant family history, was a one pack per day tobacco smoker, and endorsed use of cocaine and marijuana.

His vital signs were: temperature of 98.2F, systolic blood pressure (BP) of 155 mmHg, diastolic BP of 78 mmHg, heart rate of 97 beats per minute, respiratory rate of 18 breathes per minute and 100% oxygen saturation on room air.

Physical exam was significant for ill appearance despite no acute distress, a non-tender 5 cm x 5 cm left supraclavicular mass concerning for lymphadenopathy, bilateral crepitations on chest auscultation, and mild abdominal tenderness without peritoneal

signs. His genitourinary exam was remarkable for a large scrotal edema and an enlarged nodular prostate on DRE.

Initial lab findings showed a glomerular filtration rate (GFR) of 3NM, creatinine (Cr) of 21 mg/dL, blood urea nitrogen (BUN) of 106 mg/dL, BUN/Cr ratio < 10, potassium of 8.4 mEq/L, bicarbonate of 13 mEq/L, calcium of 8.3 mg/dL, white blood cell count of  $6 \times 10^9$ , hemoglobin of 5.4 g/dL, and platelet count of  $307 \times 10^9$ . His coagulation studies and hepatic panel were both within normal limits and his PSA was 154 ng/ml. Urine analysis showed gross hematuria with grade 3 proteinuria.

A foley catheter was immediately placed which returned 500 cc of bloody urine. He underwent emergency treatment of his hyperkalemia with a regimen that included albuterol, bicarbonate, insulin, and calcium gluconate. Nephrology was consulted, and dialysis was initiated via a right femoral central line.

He underwent a Chest X-Ray, a CT neck/soft tissue, and a CT chest/abdomen/pelvis without contrast, due to poor renal function. His chest X-Ray showed evidence of fluid overload with prominent vascular markings and hilar lymphadenopathy.

The CT neck/soft tissue scans showed a left supraclavicular mass with increased heterogeneity, well delineated borders causing displacement of the adjacent vasculature and anterior displacement of the muscles of the neck. This mass was bilobed and adjacent to the left lobe of the thyroid measuring 8.4 x 5.5 x 7.7 cm in greatest craniocaudal, AP, and transverse dimensions. There were multiple superior mediastinal heterogeneous masses with left paratracheal mass measuring 5.1 x 3.6 x 2.1 cm in longitudinal/AP/transverse dimensions.

The CT chest/abdomen/pelvis showed significant retroperitoneal and inguinal lymphadenopathy with bilateral hydronephrosis and an enlarged prostate. Also noted on this CT scan was a destructive lytic lesion noted in the medial portion of the right symphysis pubis.

**Figure 1:** CT Neck and soft tissues showing left supraclavicular mass measuring 8.4 x 5.5 x 7.7 cm (Top left).

Multiple 5 mm computed axial tomographic images of the soft tissues of the neck were obtained from the skull base to the thoracic inlet following the administration of intravenous contrast. CT chest showing paratracheal lymph node measuring 5.1 x 3.6 x 2.1 cm (top right). CT abdomen showing enlarged para-aortic lymph nodes (bottom left). CT scan showing osteolytic destruction of the right pubic ramus (bottom right).

From the Emergency room, the patient was admitted to the MICU and continued dialysis for acute renal failure and was transfused several units of packed red cells due to anemia. Due to concern for obstructive renal failure secondary to metastatic PCa, Urology was consulted.

A repeat PSA level done on hospital day four revealed an approximately five-fold increase, now at 783 ng/ml, and his urine output had declined to less than 100 cc per day, still with gross hematuria.

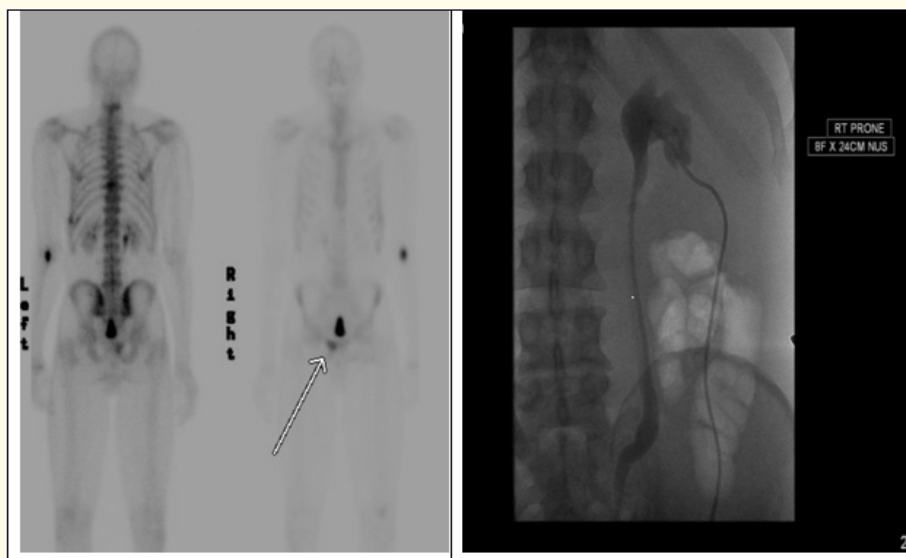
A Scrotal Ultrasound showed a secondary hydrocele and a total body bone scan showed a focal area of tracer accumulation in the right pubic bone. It was determined that the best course of action was to carry out a biopsy of the supraclavicular lymph node to rule out metastatic PCa. A Fine Needle Aspiration (FNA) was done on hospital day 8 under ultrasound guidance and the final pathology showed metastatic adenocarcinoma consistent with a prostate primary. Additional pathological findings and images from the biopsy can be seen and described below.

The patient was then started on a monthly 7.5 mg Lupron injection and 250 mg of Flutamide daily for hormonal castration.

His obstructive renal failure did not resolve despite multiple sessions of dialysis, so he eventually required placement of bilateral percutaneous nephrostomy tubes by IR. During the procedure, it was noted that there was complete obstruction of the right mid ureter by retroperitoneal lymphadenopathy, so this required additional placement of a right 8 x 24 cm nephro-ureteric stent.

His kidneys recovered following nephrostomy decompression as conveyed by a return of his creatinine level to his normal baseline value of about 1.2 mg/dL. He remained on hormonal therapy and spent a total of three months in the hospital. Unfortunately, he declined further interventions in the last weeks, so a repeat PSA could not be collected, and he ultimately discharged himself against medical advice.

**Figure 2:** Metastatic prostate adenocarcinoma to left supraclavicular lymph node; 3FNA passes were performed, contained approximately 0.8 ml of bloody fluid. PAP Stain (top right) and cell blocks (top left) were then prepared. Sections showed malignant cells arranged in small clusters with large 3-dimensional grouped sheets and singly displaying nuclear elongation/spindling, overlapping, and crowding. They have enlarged nuclei with irregular nuclear membranes, hyperchromatic chromatin and prominent nucleoli and focal necrosis. Immunostains performed on cell block sections show that the tumor cells are positive for PSA (bottom left) and prostein (bottom right); and are negative for CK7, CK20 and CDX2. In the background there are also macrophages and many red blood cells. No lymphoid tissue is identified.



**Figure 3:** (L) Total Bone scan showing tracer accumulation in the right pubic bone. Technique: Approximately 3 hours following the intravenous administration of 26 mCi of technetium 99m MDP, multiple views of the axial and appendicular skeleton was obtained. (R) Fluoroscopic view of left kidney showing hydronephrosis and left nephrostomy tube placement, contrast used :20 mL of Isovue-370.

**Figure 4:** Creatinine trend during hospitalization. Arrow indicates time of nephrostomy tube placement.

He represented on the April 4<sup>th</sup>, 2018 with bleeding per urethra and generalized weakness. His nephrostomy tubes were still intact putting out clear and adequate urine. Bleeding was presumed to come from his prostate and no surgical intervention was carried out. He again refused blood draws and so no follow up PSA was done. The bleeding stopped the next day and he was discharged home with clinic follow up.

## Discussion

Metastatic PCa can present in various forms such as lower urinary tract symptoms, osteoblastic bone lesions, malignant ascites, generalized lymphadenopathy, peritoneal metastasis, and even cutaneous metastasis [4,5]. Rarely, it can also present with supra-diaphragmatic spread and cervical lymphadenopathy as an initial sign.

While the incidence of cervical lymph node involvement in PCa is relatively low (0.4%), PCa is the most common genitourinary cause of cervical lymphadenopathy [6,7]. There are several reports describing series of PCa patients with cervical lymphadenopathy, some in the setting of a normal digital rectal exam (DRE). Lin, *et al.* found that, in a series of thirty-five patients with extra-pelvic lymphatic spread of PCa, the left supraclavicular nodes were the most common site of spread (69% of cases) with only 75% of the patients having an abnormal DRE despite the distant metastasis [8]. Cho, *et al.* found that, in a series of twenty-six patients with metastatic prostate carcinoma in supradiaphragmatic lymph nodes, only 58% had abnormal rectal examinations [9]. Butler, *et al.* reported normal DREs in over half of the patients in a series of 19 patients with PCa presenting initially with supraclavicular lymphadenopathy [10].

There are several theories to explain the mechanism of supradiaphragmatic metastasis in PCa. However, the most widely accepted theory favors lymphatic spread via the thoracic duct to the left subclavian vein, as the left supraclavicular fossa is the most common site of extra-skeletal non-regional lymphatic spread [9,11]. In regard to metastatic lymphatic spread of PCa, there typically is a step-wise progression. It initially involves regional lymph nodes (obturator and pelvic) to the retroperitoneum, then cysterna chyli, and finally the thoracic duct where the lymphatic system enters the systemic circulation by the left subclavian vein. Left cervical nodes are near the entry of thoracic duct into the left subclavian vein, which drains to the left jugular trunk. It is thought that cancer cells are then able to spread to these nodes via retrograde spread [12,13].

The prognosis of such rare metastasis is poorer because of widespread systemic involvement of diseases. The mean survival times have been reported as 19.8 and 26 months in two separate small series of case analysis [12,14]. In a case series report by Wang *et al* on three patients with PCa presenting with supraclavicular lymph node enlargement at the initial diagnosis, each patient received hormone therapy and their PSA level declined. The mean follow-up time was 16 months (range, 6 - 24 months) and none of these patients experienced progression during follow up.

In our case, the patient had both supraclavicular lymphadenopathy and bulky retroperitoneal lymphadenopathy (causing obstructive renal failure). His renal function recovered upon decompressive nephrostomy and received inpatient anti-androgen therapy for his oncologic management, consistent with the Ameri-

can Urological Association guidelines for metastatic PCa. Unfortunately, he eventually refused further PSA level screenings and was lost to follow up after discharge, making it difficult to determine his outcome.

## Conclusion

Metastatic PCa should be considered in the differential diagnosis of an elderly man presenting with an unexplained, asymptomatic neck mass, with or without obstructive symptoms or abnormal DRE. Further evaluation with special staining with PCa markers, like PSA and prostate-specific acid phosphatase (PAP), and even cervical lymph node biopsy are important in diagnosing or ruling out metastatic PCa [14,15]. Said evaluation with immunochemistry stain can provide the diagnosis and prevent complications and consequences of unnecessary rectal prostate biopsy and delayed treatment, respectively.

## Bibliography

1. American Cancer Society. "Key Statistics for Prostate Cancer | Prostate Cancer Facts". American Cancer Society (2019).
2. Lad M., *et al.* "A surprising diagnosis: metastatic prostate cancer-causing cervical lymphadenopathy". *BMJ Case Reports* (2014): bcr2013201630.
3. Hematpour K., *et al.* "Supraclavicular lymph node: incidence of unsuspected metastatic prostate cancer". *European Archives of Oto-Rhino-Laryngology* 263.9 (2006): 872-874.
4. Mak G., *et al.* "Cutaneous metastasis of prostate carcinoma treated with radiotherapy: a case presentation". *BMC Research Notes* 7 (2014): 505.
5. Dubhashi SP., *et al.* "Prostate cancer presenting as cervical lymphadenopathy". *American Journal of Case Reports* 13 (2012): 206-208.
6. Carleton J., *et al.* "Metastatic Prostate cancer presenting as an asymptomatic neck mass". *Prostate Cancer and Prostatic Diseases* 8.3 (2005): 293-295.
7. Ogunyemi O., *et al.* "Metastasis of genitourinary tumors to the head and neck region". *European Archives of Oto-Rhino-Laryngology* 267.2 (2010): 273-279.
8. Lin YY., *et al.* "Neck mass as the first presentation of metastatic prostatic adenocarcinoma". *Journal of the Chinese Medical Association* 74.12 (2011): 570-573.

9. Jones H and Anthony PP. "Metastatic prostatic carcinoma presenting as left-sided cervical lymphadenopathy: a series of 11 cases". *Histopathology* 21.2 (1992): 149-154.
10. Butler JJ, *et al.* "Enlargement of the supraclavicular lymph nodes as the initial sign of prostatic carcinoma". *Cancer* 27.5 (1971): 1055-1063.
11. Ozgür A, *et al.* "Cervical lymph node enlargement on the right side as the initial manifestation of metastatic prostate cancer". *Archivos Españoles de Urología* 56.7 (2003): 859-861.
12. Wang HJ, *et al.* "Presentation of prostate carcinoma with cervical lymphadenopathy: report of three cases". *Chang Gung Medical Journal* 27.11 (2004): 840-844.
13. Mueller TJ, *et al.* "Cutaneous metastases from genitourinary malignancies". *Urology* 63.6 (2004): 1021-1026.
14. Chan G and Domes T. "Supraclavicular lymphadenopathy as the initial presentation of metastatic prostate cancer: A case report and review of literature". *Canadian Urological Association Journal* 7.5-6 (2013): E433-E435.
15. Platania M, *et al.* "Prostate Adenocarcinoma Presenting with Supraclavicular Node Enlargement: Report of a Case". *Tumori Journal* 94.5 (2008): 769-771.

**Volume 3 Issue 3 March 2019**

© All rights are reserved by Pamela W Coleman, *et al.*