

## Comparison between the Placental Shapes in Low Birth Weight Newborns and Normal Birth Weight Newborns

**Fariha Sabeen\***

Senior Resident of Anatomy, Mahatma Gandhi Memorial Hospital, Jharkhand, India

**\*Corresponding Author:** Fariha Sabeen, Senior Resident of Anatomy, Mahatma Gandhi Memorial Hospital, Jharkhand, India.

**Received:** October 17, 2022

**Published:** November 30, 2022

© All rights are reserved by **Fariha Sabeen**.

### Abstract

**Objective:** Comparative study of placental shape in low birth weight newborns and normal birth weight newborns.

**Materials and Methods:** The Study was carried out at Rajendra Institute of Medical Sciences, Ranchi, India from June 2018 to July 2020. The placentas were collected from 134 cases of mothers of normal birth weight babies and 100 cases of mothers of low birth weight babies. Placental shape was studied and compared in both the groups.

**Results:** The placentas were collected from 134 mothers of normal birth weight babies and 100 mothers of low birth weight babies. There is marked variation in the shapes of placenta. Round placenta with periphery thinner than center were 51% in LBWB whereas, 36% in normal birth weight babies. Irregular, circular placentas were 15% in normal birth weight babies but none in LBWB. Oval placentas were 15% in normal birth weight babies, and 12% in LBWB. 2% normal birth weight placentas were triangular in shape. Round placenta with periphery thicker than the center were 22% in LBWB, whereas 7% in placentas of normal birth weight babies. 2% of LBWB placentas were kidney shaped, whereas 3% of normal placentas were kidney shaped. 13% of LBWB placentas were bilobed and trilobed, and 20% of normal birth weight placentas. In LBWB none were heart shaped, but only 1% placenta of normal birth weight was heart shaped. Placentas with accessory lobes were also only 1% in normal birth weight but none in LBWB.

**Conclusion:** Shape of placentas of normal birth weight babies and low birth weight babies were studied and compared.

**Keywords:** LBWB (Low Birth Weight Babies)

### Introduction

Placenta is known since ancient times. It may not be pretty to look at but it is the most beautiful organ. In the Old Testament it was thought to be the "External soul". This study reviews the incidence of various shapes of placenta in both low birth weight and normal birth weight newborns.

In India 15-30% of babies born at term are of low birth weight, undernutrition and toxemia of pregnancy are considered to be important maternal causes. In India, about 6-8% of the pregnancies belong to the high risk category. National Institute of Child Health and development defined High risk pregnancy as one that threatens the health and life of the mother and foetus [1].

The placenta is the vital organ for maintaining pregnancy and promoting normal foetal development. There are many well established causes of LBWB, such as maternal disorders like pre-eclampsia, foetal intrauterine infections, congenital malformations, chromosomal anomalies etc.

Placenta is a choriodecidual structure developing during pregnancy and lies implanted on the uterine wall near the fundus with about equal frequency to adjacent anterior and posterior wall. It is connected to foetus through umbilical cord. It is also most important endocrine organ but unlike other organs in the human body it has a functional lifespan of only about four to five months.

It maintains pregnancy and carries vital functions like respiration excretion and food absorption.

According to Grosser's [2] classification (1909) the human placenta falls in the category of haemochorial type because of direct contact of chorion with maternal blood. It is deciduate because the maternal tissue is shed at parturition. The fact that maternal and fetal tissues come in direct contact without rejection suggest immunological acceptance of foetal graft by mother [3].

According to text book by Holland and Brews 16th edition (1998), when shed from uterine attachments the placenta is, as its name implies, an oval or circular flat cake measuring 6 inches to 8 inches in diameter, 1 inch in thickness at the center and weighing 500 gm. The margin is thinner and firmer than the center, and passes abruptly into chorion laevae.

The gross characteristics specifically shape of placentas from a population of singleton live-born infants delivered before the 28<sup>th</sup> post-menstrual week; in comparison to full-term pregnancy is described in the present study.

### Anomalies of placental shape

#### Placenta bipartite or bilobed placenta

Occasionally Placenta may be separated into lobes. When division is incomplete the vessels of the fetal origin extend from one lobe to other before uniting to form an umbilical cord. This condition is known as Placenta bipartite or bilobata. It's reported incidence varies widely but Fox (1978) cited it is about 1 in 350 deliveries [3]. If two lobes are separated entirely and vessels remain distinct, the condition is known as placenta duplex. Occasionally there is placenta triplex.

#### Placenta succenturiate

In which one or more accessory lobes are developed in membranes at a distance from the periphery of the main placenta to which they usually have vascular connections of fetal origin. It is a smaller version of bilobed placenta and its incidence is 5% (Benirshke and Kauffman in 2000) [4].

#### Ring- shaped placenta

It is a rare anomaly seen in fewer than 1 in 6000 deliveries <sup>4</sup>. Placenta is annular in shape and sometimes a complete ring of placental tissue is present but because of atrophy of a portion of ring, horse shoe is more common.

### Placenta membranaceous

It is also known as Placenta diffusa. In this condition fetal membranes are covered by functioning villi, and the placenta develops as a thin membranous structure occupying entire periphery of the Chorion.

### Fenestrated placenta

It is very rare in which the central portion of discoidal is missing. Sometimes there is actual hole in the Placenta.

### Extrachorial placenta

This is a common variation and Benirshke and Kauffman (2000) [4] found it in 5.3% of over 3500 consecutive deliveries. It forms when the chorionic plate which is on the fetal side of placenta is smaller than the basal plate, which is located on the maternal side [4]. It is the fetal surface of such placenta presents a central depression, surrounded by thickened greyish white ring, it is called circumvallate placenta. When the ring coincides with the placenta margins, this condition is described as placenta marginata [4].

### Materials and Methods

Intact and fresh placentas were obtained from the labour room of Department of Gynaecology, RIMS, Ranchi.

Placenta from both full term and pre-term deliveries were taken, delivered either by normal vaginal delivery or caesarean section.

#### Materials used for data collection

- Tray
- Dissecting forceps
- Scalpel
- Knife
- Scissors.

#### Examination of placentas


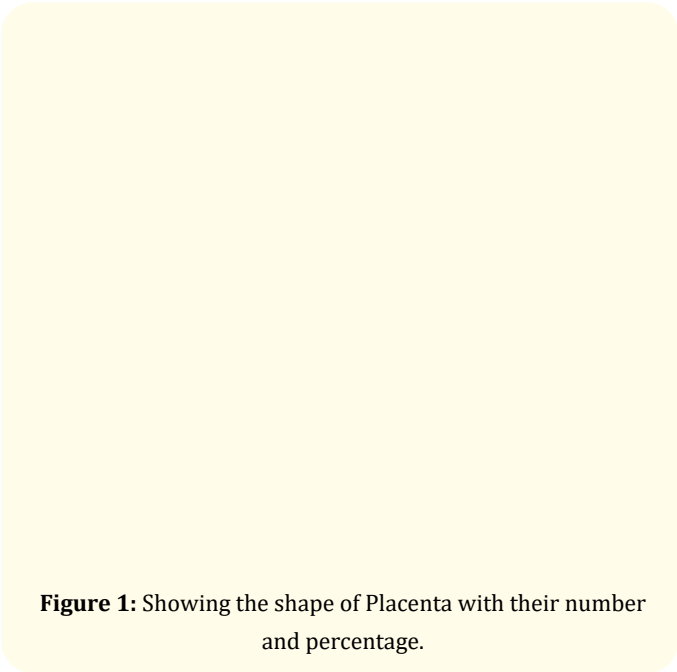
All fresh placentas were washed in running water to remove any clots. A detailed gross examination of the placenta was done with emphasis on shape.

### Observation and Discussion

The present study was undertaken on the placentas obtained from labour room of RIMS Ranchi, as well as from some private clinics of Ranchi.

The present work has been conducted on a total of 234 placentas obtained from pre - term or full term pregnancies, either delivered normally or by cesarean section. Out of these, 100 placentas were of low birth weight babies (LBWB) with birth weight in the range 1000-2400 gms, whereas 134 placentas were of normal birth weight babies, with birth weight ranging between 2500-4500 gms.

The observation has been recorded in Tabulated Form.



Dodds (1947) [5], Pattern (1953) and Dawn (1965) have described the shape of normal placenta to be disc like. Boyd, Hamilton and Mossman (1962), Pattern (1953), have reported placenta succenturiate and bilobed placenta in their series. The majority of the placenta have disc like appearance. In Rohtagi’s series (1968), 73.2% were disc like, 20% were irregular disc like and 6.8% were oval or kidney shaped or triangular. 3 placentas were succenturiate and 2 were bilobed.

According to Benirshke and Kauffman (2000) [4], incidence of succenturiate lobe was 5%.

Most of the placentas were disc shaped. The incidence of placenta succenturiate, bilobed placenta, kidney shaped and heart shaped placenta was higher in the present series than of Mukherjee (1967) and Rohtagi (1968). Placenta with accessory lobe was 0.5%, that was very small in comparison to finding of Benirshke and Kauffman [4]. No other abnormal placenta was found, like placenta extrachorialis, fenestrated placenta or ring shaped placenta.

Result

There is marked variation in the shapes of placenta. Round placenta with periphery thinner than center were 51% in LBWB

whereas, 36% in normal birth weight babies. Irregular, circular placentas were 15% in normal birth weight babies but none in LBWB. Oval placentas were 15% in normal birth weight babies, and 12% in LBWB. 2% normal birth weight placentas were triangular in shape. Round placentas with periphery thicker than the center were 22% in LBWB, whereas 7% in placentas of normal birth weight babies. 2% of LBWB were kidney shaped, whereas 3% of normal birth weight placentas were kidney shaped. 13% of LBWB were bilobed and trilobed, whereas 27% of normal birth weight placentas. In LBWB none were heart shaped, but only 1% placenta of normal birth weight was heart shaped. Placentas with accessory lobes were also only 1% in normal birth weight but none in LBWB.

### Clinical relevance of the study

#### Possible role of placental morphology in the detection of foetal growth restriction

Fetal growth restriction (FGR) is often the result of placental insufficiency and is characterized by insufficient trans placental transport of nutrients and oxygen. The main underlying entities of placental insufficiency, the pathophysiologic mechanism, can broadly be divided into impairments in blood flow and exchange capacity over the syncytiotrophoblastic membranes of the fetal placenta villi. Fetal growth restriction is not synonymous with small for gestational age and techniques to distinguish between both are needed. Placental insufficiency has significant associations with adverse pregnancy outcomes (perinatal mortality and morbidity). Even in apparently healthy survivors, altered fetal programming may lead to long-term neurodevelopmental and metabolic effects. Although the concept of fetal growth restriction is well appreciated in contemporary obstetrics, the appropriate detection of FGR remains an issue in clinical practice. Several approaches have aimed to improve detection, e.g., uniform definition of FGR, use of Doppler ultrasound profiles and use of growth trajectories by ultrasound fetal biometry. However, the role of placental morphometry (placental dimensions/shape and weight) deserves further exploration.

The antenatal health care given to pregnant women has great influence on the rates of perinatal death and morbidity. Amongst the different causes of perinatal mortality, low birth weight (LBW) is the single most significant factor and about 2/3 deaths among infants with less than 2500 g birth weight.

By international agreement, LBW infant is one whose birth weight is 2500g or less irrespective of the gestational age. They further categorized as LBW babies (LBWB) before 37 weeks (preterm) and LBWB after 37 weeks (small for gestational age [SGA] or intrauterine growth restricted [IUGR] (LBWB). Significant numbers of perinatal mortality fall in the latter group. The sample registration system estimate overall perinatal mortality rate was 37/1000 live birth and still birth for year 2007.

Causes of LBW can be divided into maternal, fetal, placental and unknown causes, but the basic pathophysiology is due to reduced availability of nutrients in mother or its reduced transfer by the placenta to the fetus. It may also be due to reduced utilization by the fetus.

As there are very few well planned studies from India describing the changes in placentae of LBWB, the present study was undertaken to assess the changes in the placenta of LBWB in comparison to normal birth weight babies.

The author declares that submitted manuscript is original research work and has not been published. It is not under simultaneous consideration for publication elsewhere.

Due permission was taken from the ethical society at Rajendra Institute of Medical Sciences, Ranchi, India.

### Bibliography

1. Placental morphology low birth weight infants.
2. GROSSER C. "Frühentwicklung Eihautbildung und Placentation". München Bergmann, Publisher PP. 88, 89, 170, 340-341, 381-2, 395, 400, 1927.
3. Fox H. "Pathology of Human Placenta". Monograph, Philadelphia, Saunders 7 (1978).
4. Benirschke and Kauffman. "Pathology of Human Placenta". 4<sup>th</sup> Edition, New York, Springer (2000).
5. Dodds. "The area of the chorionic villi the full term placenta". *Anatomical Record* 24 (1947): 207.