

Management of Cracked Mandibular First Molar with Biodentine: A Case Report

Neelam Mittal¹ and Kharat Shubham Mangilal^{2*}

¹Conservative Dentistry and Endodontics, Faculty of Dental Sciences, IMS, BHU, Varanasi, Uttar Pradesh, India

²Junior Resident, Faculty of Dental Sciences, IMS BHU, Varanasi, Uttar Pradesh, India

*Corresponding Author: Kharat Shubham Mangilal, Junior Resident, Faculty of Dental Sciences, IMS BHU, Varanasi, Uttar Pradesh, India.

DOI: [10.31080/ASDS.2023.07.1622](https://doi.org/10.31080/ASDS.2023.07.1622)

Received: March 30, 2023

Published: April 11, 2023

© All rights are reserved by Neelam Mittal and Kharat Shubham Mangilal.

Abstract

Dentists face significant challenges in diagnosing and treating tooth fractures. Specially in cases of cracks, the determination of extent of crack is of paramount importance for determining the treatment modalities. This case report aimed to demonstrate the feasibility and outcome of partial cracked tooth using biodentine pulpotomy. A 24-year-old male, who had pain, while taking cold meal in a permanent left first mandibular molar with a temporary restoration reported in our department for treatment. After removal of temporary restoration, the crack was noticed on the tooth at distal marginal ridge extending into pulp chamber. Due to involvement of pulp chamber pulpotomy was performed and Biodentine was placed as vital pulp therapy agent which relieved symptoms. To repair the crack line, light cure flowable composite is used which also provides strength and decreased microleakage. Which is followed by GIC and composite restorations.

Keywords: Biodentine Pulpotomy; Coronal Pulpotomy; Cracked Tooth; Incomplete Fractured Tooth; Partial Fractured Tooth

Introduction

Dental traumatology includes multidisciplinary fields. Decisions in an emergency should only be made for a brief period of time, and the outcomes should only be assessed later [1]. A diagnostic challenge is offered by cracked and fractured teeth. Better chances of saving the tooth result from early diagnosis and treatment. To characterize fractured teeth, Gibbs initially used the phrase "Cuspal fracture odontalgia" in 1954. Masticatory or accidental trauma is the most common reason for partial fracture. Unintentional biting on an extremely hard object might result in excessive load that abruptly causes the tooth to crack [2]. In both the instance of a simple crown fracture (enamel and outer dentin) and a complex crown fracture (deep dentin with pulp exposure), reattachment is feasible.

Biodentine has a high level of biocompatibility, so there is no irreversible inflammatory response when pulp tissue is in contact with Biodentine [3]. According to earlier research, Biodentine has strong antibacterial and antifungal properties. Due to the presence of calcium chloride in liquid component of Biodentine, it sets up

faster than MTA which is commonly used for pulpotomies. Compared to MTA, Biodentine has greater flexural strength, compressive strength, and elastic modulus [4].

The fundamental goal of vital pulp therapy is to maintain the vitality of tooth that is affected. Pulp capping or pulpotomy operations may be used in pulp therapy, depending on the degree of pulpal involvement [5]. By removing the coronal area of the infected or inflamed pulp while the radicular region is still healthy, pulpotomy therapy tries to maintain the vitality of an infected or inflamed tooth.

Materials and Methods

A 24-year-old male patient reported to the Department of Conservative Dentistry and Endodontics with a complaint of sensitivity to cold in permanent left mandibular first molar since one week. Patient had history of temporary filling. Upon removal of the temporary restoration, a fracture line was noticed running coronally from distal marginal ridge into pulp chamber (Figure 3). No peri-

apical changes were evident on radiographic inspection (Figure 2). A provisional diagnosis of partial crown fracture/ crack was made.

Figure 1: Pre-operative photograph.

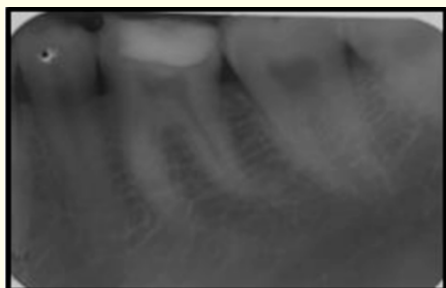


Figure 2: Pre-operative radiograph.




Figure 3: Fracture line seen at distal marginal ridge.

Figure 4: Biodentine placement and sealing of fracture line with flowable composite.

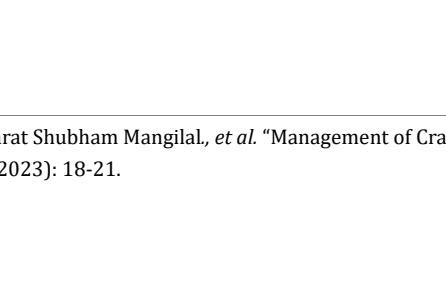


Figure 5: GIC restoration over biodentine.

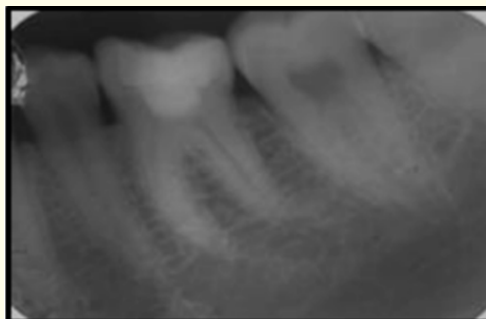


Figure 6: Coronal restoration after composite restoration.

Figure 7: Crown Preparation.

Figure 8: Placement of Metal Ceramic crown.

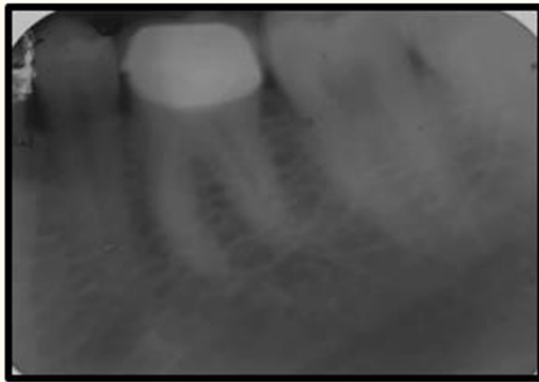


Figure 9: Post operative radiograph.

After informed consent was obtained, a standardized vital pulpotomy technique was performed.

Two percent lidocaine with 1:200,000 epinephrine was administered, and the tooth was isolated with a dental dam. Access opening was done, all the coronal pulp was removed. A cotton pellet dipped in NaOCl was used to control bleeding from canal orifices for 5 minutes. After achieving hemostasis, Biodentine was mixed as per manufacturer's instructions and applied using an amalgam carrier. After allowing the cement to set for 10 to 12 minutes, the Biodentine was covered with glass ionomer cement before proceeding for sealing of crack. 37% phosphoric acid (Ivoclar Vivadent Eco Etch) was used to etch the area at the fracture line for 15 seconds, followed by a thorough rinsing and drying to reveal the frosty appearance. Two coats of bonding agent (Econom Bond) were applied and cured followed by flowable composite application (Ivoclar Vivadent TE-Econom Bond) was done for sealing of fracture line. Then the final restoration was done by using composite. For securing the integrity of crown, metal ceramic crown restoration was given.

Results and Discussion

The majority of incomplete tooth fractures (81.1%) are in mesiodistal direction in mandibular molar teeth. [6] These cracks may only be limited in the crown or they may lead to the root. Cracks and fractures are difficult to diagnose. A sharp pain experienced on chewing hard objects is crucial diagnostic evidence. It is hypothesized that this short and sharp pain is generated by an alternating stretching and compressing of odontoblastic processes located in the crack [2]. In this case report, coronal pulpotomy with biodentine was used to treat tooth crack. In the mentioned situation, the coronal pulp tissue was removed, the bleeding stopped in 5-7 minutes, and a healthy pulp stump was produced. The entire process was carried out with complete sterilization. The capacity to control pulpal haemorrhage and visual examination of an underlying healthy pulp stump serve as the success criteria of coronal pulpoto-

my in such circumstances. For pulpotomy procedures, various materials have been used. Calcium hydroxide (CH), which has historically been the preferred material for VPT [7], is now rarely utilised since MTA produces a thicker, better-quality hard tissue barrier and a milder inflammatory response [8].

Prognosis of sealing the crack line is improved with the development of composites and resin adhesive. This technique requires only a thin layer of flowable composite resin. Their low modulus of elasticity favors contraction stress dissipation and marginal integrity preservation to restore the crack line [9-12]. Sealing of fracture line will increase bond strength and reduce microleakage which provides a bacterial-tight seal.

In this case report, Biodentine was preferred over MTA because of its quicker setting time and simpler handling. Quality of hard tissue barrier is similar to that formed by MTA. Also, Biodentine has a setting time of 10-12 minutes as compared to longer setting time of MTA. Biodentine have superior compressive and flexural strength than MTA [4].

Conclusion

Management of crown fracture or cracks is critical and is based on diagnosis, extent and location. Partial crown fractures or cracks involving pulp can be treated conservatively by doing pulpotomy followed by Biodentine as vital pulp therapy agent. In this case, the repair of fracture line was done by using light cure flowable composite. For securing crown from occlusal forces crown restoration was given. In vertical fracture cases, the treatment options range from reattachment, pulp treatment and sometimes even extraction. When selecting a treatment plan, factors such as complete method comprehension, risk vs. benefit ratio, evidence, cost, and patient consent should be taken into consideration. Regular follow-ups are important for the long-term success.

Bibliography

1. Andreasen Jens O., *et al.* "Textbook and color atlas of traumatic injuries to the teeth". John Wiley and Sons (2018).
2. Mittal Neelam., *et al.* "Management of cracked teeth-a case report". *Endodontology* 19.1 (2007): 39-44.
3. Tziafa, Christina., *et al.* "Dentinogenic responses after direct pulp capping of miniature swine teeth with Biodentine". *Journal of Endodontics* 40.12 (2014): 1967-1971.
4. Kaur Mandeep., *et al.* "MTA versus Biodentine: review of literature with a comparative analysis". *Journal of Clinical and Diagnostic Research: JCDR* 11.8 (2017): ZG01.

5. De Coster Peter, *et al.* "Laser-assisted pulpotomy in primary teeth: a systematic review". *International Journal of Paediatric Dentistry* 23.6 (2013): 389-399.
6. Chowdhury Dr Debolina and Dr Soumita Samanta. "D Molar Cuspal Fracture: Case Series". *International Journal of Cur Key words*.
7. Banava Sepideh., *et al.* "Histological evaluation of single and double-visit direct pulp capping with different materials on sound human premolars: a randomized controlled clinical trial". *Iranian Endodontic Journal* 10.2 (2015): 82.
8. Haikal Léa., *et al.* "Biodentine pulpotomies on permanent traumatized teeth with complicated crown fractures". *Journal of Endodontics* 46.9 (2020): 1204-1209.
9. Bayne Stephen C., *et al.* "A characterization of first-generation flowable composites". *The Journal of the American Dental Association* 129.5 (1998): 567-577.
10. Helvatjoglu-Antoniades M., *et al.* "Dynamic and static elastic moduli of packable and flowable composite resins and their development after initial photo curing". *Dental Materials* 22.5 (2006): 450-459.
11. Labella R., *et al.* "Polymerization shrinkage and elasticity of flowable composites and filled adhesives". *Dental Materials* 15.2 (1999): 128-137.
12. Leevailoj C., *et al.* "Microleakage of posterior packable resin composites with and without flowable liners". *Operative Dentistry* 26.3 (2001): 3.