



Single Centre Study On Application Of Pedicled And Local Flaps For Cheek Mucosal Defects

Nadimul Hoda¹, Vasantha Dhara², Rajani BC^{1*}, KS Sabitha³,
Jayesh Nathani² and Subhabrata Ghosh²

¹Assistant Professor, Oral Oncology, Kidwai Memorial Institute of Oncology,
Bangalore, India

²Fellow, Oral Oncology, Kidwai Memorial Institute of Oncology, Bangalore, India

³Professor and Head, Oral Oncology, Kidwai Memorial Institute of Oncology,
Bangalore, India

*Corresponding Author: Rajani BC, Fellow, Oral Oncology, Kidwai Memorial
Institute of Oncology, Bangalore, India.

Received: November 04, 2020

Published: April 09, 2021

© All rights are reserved by Rajani BC, et al.

Abstract

To evaluate the utility of locoregional flaps for the reconstruction of buccal mucosa defects in the Indian population. A retrospective study of 302 patients and their records was done, who underwent reconstruction of buccal mucosa with locoregional flaps from January 2016 - 2017. Buccal fat pad, nasolabial flap, masseter flap, forehead flap, PMMC flap were used for reconstruction and evaluated. Due to their reliable vascularity, ease of harvesting the flap, and minimal postoperative morbidities, locoregional flaps are ideal options to reconstruct buccal mucosa defects of all dimensions. These are valuable in resource constrained, high volume centres especially in patients with poor performance and low socio economic strata.

Keywords: Buccal Mucosa; Masseter Flap; Buccal Fat Pad; Nasolabial Flap; Pectoralis Major Myocutaneous Flap; Forehead Flap

Abbreviation

PMMC: Pectoralis Major Myocutaneous Flap

Introduction

Head and neck cancer is the sixth common cause of cancer with an estimated worldwide incidence of over 600,000 new cases annually [1]. Carcinoma of the buccal mucosa is the most common cancer of the oral cavity in India [2]. Surgical management of buccal mucosa is complex in view of its proximity to the masticatory space and the mandible [3].

Surgery for tumors of head and neck can cause significant soft tissue, bony and skin defects resulting in functional impairment such as speech and swallowing deficits. In the past, attempts were made to achieve functional restoration of resected head and neck areas with acceptable cosmesis using locoregional flaps. The last couple of decades have seen an increasing role of microvascular

free flaps for optimal soft and hard tissue reconstruction gaining superior functional and esthetic results [4,5]. However, in many resource deficit centres catering to the economically weak and centres where microvascular setup is not available, locoregional flaps continue to be used with satisfactory outcomes.

The buccal mucosa is a composite site that may consist of both soft and hard tissue depending on the tumour extensions. Reconstruction of this defect has been done using locoregional flaps at our institution and the choice of the flap is dependent on the location, size, extent of the tumour.

Materials and Methods

A retrospective records review was performed of all cases of carcinoma of primary buccal mucosa treated surgically in the department of oral oncology, kidwai memorial institute for oncology. Loco regional flaps such as buccal fat pad, nasolabial flap, masseter

flap, forehead flap, PMMC flap were used for reconstruction of buccal mucosa defects in all these cases. Cases with complete records, including demographic, clinical, and surgical data, were included. Complications of flaps were noted.

Results

The charts and records from the oral oncology Unit, identified 302 biopsy proven cases of squamous cell carcinoma of buccal mucosa from the database between January 2016 to January 2017.

There were 135 men and 167 women in our series. The mean age of patients was 54.5 years. The length of hospitalization ranged from 7 to 24 days. Amongst the males, 42.9% (n = 58) had a history of smoking, 48.2% (n = 66) had a history of alcohol consumption and 88.6% (n = 119) had a history of tobacco/areca nut consumption. Amongst the females, 92.6% (n = 154) of them had a history of arecanut/tobacco chewing. 158 patients in total had medical comorbidities such as hypertension, diabetes mellitus, thyroid disorder and cardiac conditions.

The tumor size stages were as follows: T1 in 29 patients (9.6%), T2 in 74 patients (24.5%), T3 in 102 patients (33.7%), and T4 in 97 patients (32.1%) (Figure 1).

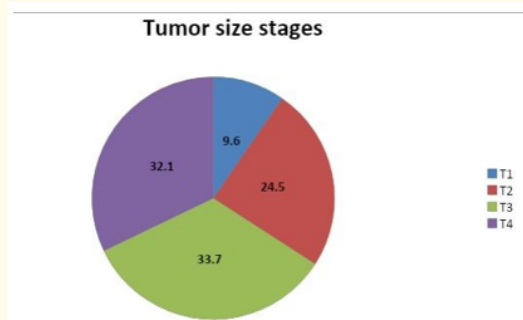


Figure 1: Distribution of tumour size.

Wide excision with adequate margin was done in all the cases with or without bony resection, with or without skin margins depending on the tumour involvement. Wide excision alone was done in 29.8 % of cases (n = 90). hemimandibulectomy/ segmental mandibulectomy with wide excision was done in 46.6% of cases (n = 141). Wide excision with hemimandibulectomy and upper alveolectomy was done in 12.5% of cases (n = 38). Wide excision with marginal mandibulectomy was done in 6.6% of cases (n = 20).

Wide excision with upper alveolectomy was done in 4.3% of cases (n = 13) (Figure 2).

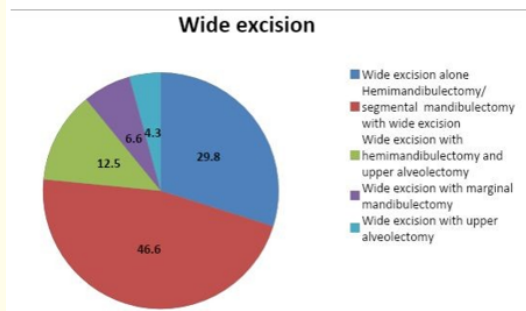


Figure 2: Distribution of surgery.

The most commonly used was the PMMC flap in 42.05% of cases (n = 127), followed by nasolabial flap 25.1% (n = 76), masseter flap 17.8% (n = 54), buccal fat pad 11.5% (n = 35) and forehead flap in 3.3% (n = 10) of cases (Figure 3). Total flap survival rate was 98.01% (296/302). Two PMMC flaps developed signs of congestion postoperatively, which was caused by a hematoma that necessitated surgical exploration. Spontaneous recovery of the flaps followed later: 2 PMMC flaps and 1 forehead flap completely failed. The two failed flaps were debrided and the forehead flap was used for secondary defect closure. The failed distal part of the forehead flap was debrided and after wound contraction, nasolabial flap was used for secondary reconstruction. 1 PMMC flap underwent partial necrosis and healed secondarily. Marginal necrosis of PMMC flap was found in 18 cases (15 females, 3 males). 10 patients in this group had diabetes mellitus. Wound dehiscence was noted in 2 cases of PMMC flap and 1 nasolabial flap. Orocutaneous fistula was noted in one nasolabial flap case and one PMMC flap case.

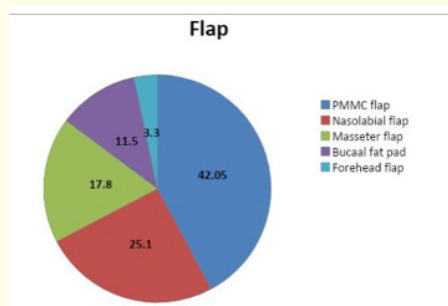


Figure 3: Distribution of flap.

Patients underwent primary closure after excision of fistula. Wound dehiscence at the donor site of pmmc was seen in 6 cases, which underwent secondary healing (all males). Twenty-six patients (28.0%) developed at least one postoperative complication, including wound infection (n = 5), wound dehiscence (n = 1), partial flap necrosis (n = 9), fistula (n = 10), and bleeding (n = 1). The follow-up period ranged from 5 to 36 months.

Discussion

Locoregional flaps have been time tested reconstruction options being practised even today in the decade of microvascular flaps due to various factors. Their vascularity, ease of harvesting, colour match and abundance of skin and soft tissue for reconstruction have been reliable.

Buccal mucosa is a common site for oral cancer, and the reconstruction options depend upon the site and size of defect [6]. The gingivobuccal sulcus cancers, also known as the Indian cancer, invariably involve a part of the buccal mucosa in most cases, requiring segmental or hemimandibulectomy with reconstruction using flaps providing bulk. For smaller lesions, primary closure is possible, however it depends on the depth of resection which also dictates reconstruction options. For superficial resections, skin grafts and even buccal fat pads are ideal. When the defect ranges from upper to lower sulcus, with or without alveolectomy; forehead flap, nasolabial flap, submental flap, platysma flap, or temporalis muscle flap are standard options [7]. Pectoralis major myocutaneous flap is the most sought after for hemimandible or segmental defects and inset done either as a single or bipaddle manner.

Buccal FAT PAD

The buccal fat pad flap is utilized for reconstructing small-to-medium-sized soft tissue defects and as a cover for bony defects in the palate and alveolus. The first use of buccal fat pad for oral malignancy defects was done by Rapidis., *et al*, Hao and Dean., *et al*. [8-10]. It is a vascular flap deriving blood supply from branches of maxillary artery, superficial temporal, transverse facial branches and consisting of a central body with four extensions: buccal, pterygoid, superficial, and deep temporal. buccal fat pad could be involved as a deeper margin in some resections and in such cases it cannot be used as a reconstruction option [11]. Gentle handling of flap is essential while inseting as stretching can impair its vascularity. The epithelialization of bfp takes around 4 - 6 weeks. In our cases, adequate healing was observed with maintenance of mouth opening (Figure 4).

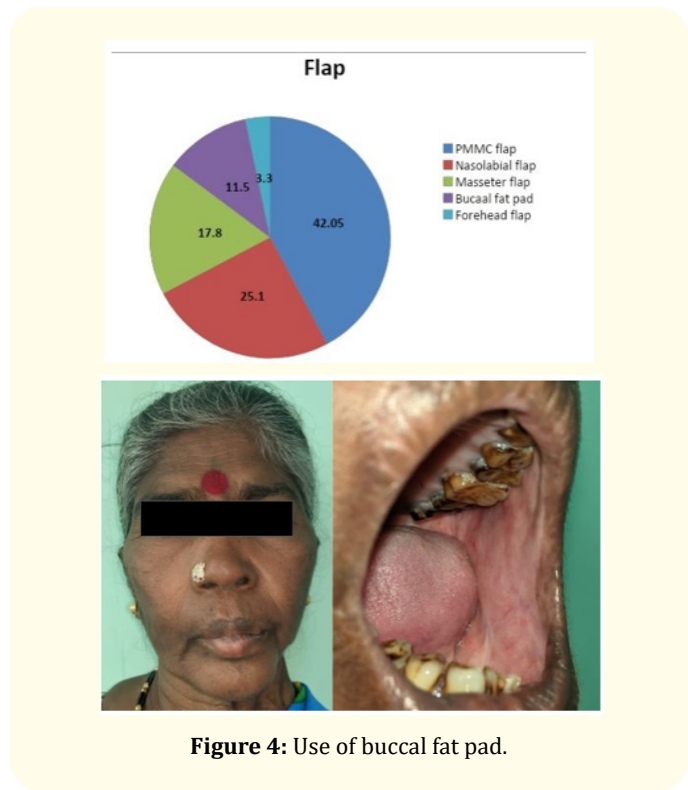


Figure 4: Use of buccal fat pad.

Nasolabial flap

Nasolabial flap is a very versatile flap regularly used for reconstruction of defects of cheek, nose, lips and oral cavity. Based on its orientation, it is supplied by the facial artery, transverse facial artery (inferior based), or superficial temporal artery and infra-orbital artery (superior based) [12]. Depending on the defect, the flap can be raised as thin as deep to the subdermal plexus, and as thick as superficial to the facial musculature with their nerve supply intact [13]. Nasolabial flap in our series, has been extensively used for buccal mucosa, commissure, upper lip or lower lip, lower alveolus and upper alveolus resection cases. In males, hair growth could be a limiting factor initially. Fine suturing of the incision can ensure a more esthetic result eventually (Figure 5).

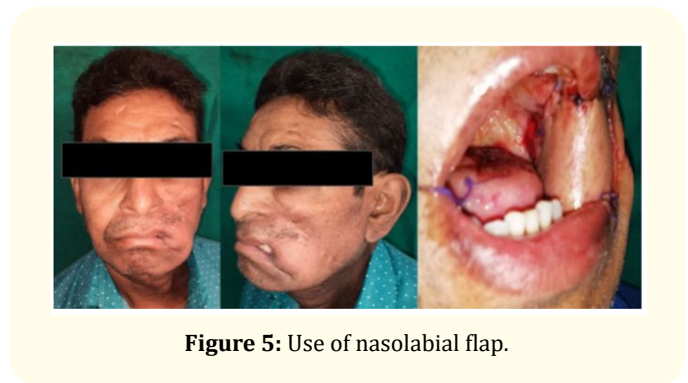


Figure 5: Use of nasolabial flap.

Masseteric muscle flap

The masseter muscle is one of the muscles of mastication and attached to the lateral side of the ramus of the mandible. It was first introduced as a reconstruction option by Conley and Gullane in 1978 for oropharyngeal defects [14]. While raising the cheek flap, the fascia over masseter is incised to include it thus preserving branches of the facial nerve. the inseting of the flap can be done by transposing it horizontally while maintaining the superior zygoma attachment [15]. Selection of masseter flap as reconstruction option is to be decided carefully as in cases of its involvement or proximity to tumour will require resection of it as per oncological principles. Thus thorough clinical and radiological evaluation is necessary before using this flap. In our cases, patients were strictly advised mouth opening exercises after 5 days. The disadvantage in some patients would be the deformity present anteriorly (Figure 6).

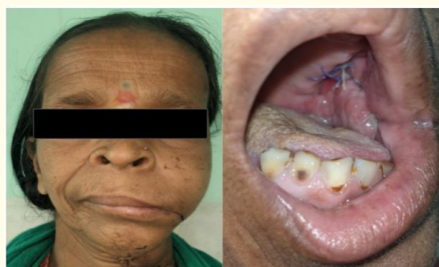

Figure 6: Use of masseteric flap.

Pectoralis major myocutaneous flap

PMMC flap has been the workhorse of head and neck reconstruction due to the advantages it provides such as excellent blood supply, bulk of skin and muscle with ease of harvesting [16]. The arterial supply is by the thoracoacromial artery, lateral thoracic artery and superior thoracic artery [17]. Based on the harvesting and inset, the flap can be described as unipaddle, bipaddle, partial bipaddle, and osteocutaneous flap. The popularity of the PMMC flap as the go-to option is understood by its use in the reconstruction of oral cavity defects following resection of lateral gingivobuccal complex lesion, composite defects following segmental or hemimandibulectomy, full thickness cheek defects, and total glossectomy defects. Anchoring sutures during flap raising to hold the muscle base to the skin is essential to prevent shearing of the flap. suturing and inseting of the flap is to be done diligently without much torsion as it can lead to damage to the pedicle. The majority of our

cases required PMMC flap for reconstruction with good functional and esthetic outcomes (Figure 7). Marginal necrosis is a relatively common complication in females due to the fat bulk between the muscle base and the skin.

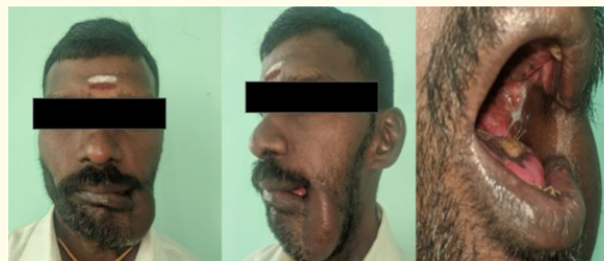


Figure 7: Use of pmmc flap.

Forehead flap

The forehead flap is not being frequently used since the past few decades. However due to its proximity and vascularity it is a dependable option for reconstruction of nasal and cheek defects [18]. The forehead flap is an axial pattern fascio-cutaneous flap supplied by superficial temporal vessels [19]. It is raised as a median, paramedian flap in a vertical fashion or full length or partial length flap in a horizontal fashion [20]. The donor site is covered with a split skin graft. In any reconstruction setting, The forehead flap is done as a two-stage procedure. For our cases, forehead flap was used in defects involving the buccal mucosa with and without lip and commissure involvement. The length of the flap is adequate to fold and make an intra oral and extra oral lining. After a healing period of 3 weeks, the proximal portion of the flap is cut and disposed of (Figure 8). The disadvantage is the residual forehead donor site scar due to full thickness skin graft.

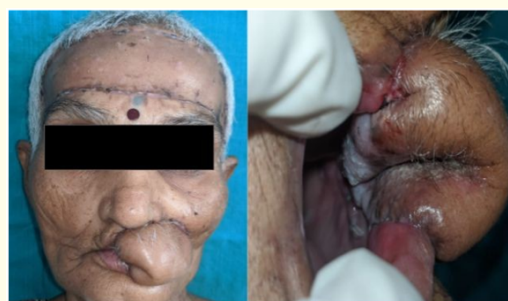

Figure 8: Use of forehead flap.

In our study a gamut of locoregional flaps were used. After adequate wound healing and flap take up, 264 patients were referred for adjuvant treatment based on the histopathology report. Parameters such as aesthetics, oral competence, mouth opening and ability to eat were also noted during follow up period and were found satisfactory.

The huge patient load coming from a challenged socioeconomic background and lack of high expertise centres, locoregional flaps are options which may not fade away completely. The last few years have seen other local flaps being increasingly used such as the submental flap, supraclavicular flap, infrahyoid flap, temporoparietal flap, etc. [21]. Mastering these flaps is essential for the younger surgeons before moving on to the more sophisticated free flaps.

Conclusion

A wide range of reconstructive options are available for composite defects resulting from buccal mucosa cancer resections, the efficacy of which depends on the specific anatomy of the defect, planned outcome, the patient's tolerance for donor site morbidity, and the surgeon's training and experience. Our institute's experience shows locoregional flaps are still an option for buccal mucosa resections with acceptable aesthetic and functional outcomes.

Bibliography

1. Ferlay J, et al. "GLOBOCAN 2012: Cancer Incidence, Mortality and Prevalence Worldwide". *International Agency for Research on Cancer* (2012).
2. Srivastava V, et al. "Consensus Document for Management of Buccal Mucosa Cancer". New Delhi: Indian Council of Medical Research (2014).
3. Fang QG, et al. "Squamous cell carcinoma of the buccal mucosa: analysis of clinical presentation, outcome and prognostic factors". *Molecular and Clinical Oncology* 1 (2013): 531-534.
4. Kalavrezos N and Bhandari R. "Current trends and future perspectives in the surgical management of oral cancer". *Oral Oncology* 46 (2010): 429-432.
5. Fang QG, et al. "Comparison studies of different flaps for reconstruction of buccal defects". *Journal of Craniofacial Surgery* 24 (2013): e450-451.
6. Iyer SG, et al. "Surgical treatment outcomes of localized squamous carcinoma of buccal mucosa". *Head Neck* 26.10 (2004): 897-902.
7. Squaquara R, et al. "Intraoral reconstruction using local and regional flaps". *Seminars in Plastic Surgery* 24.2 (2010): 198-211.
8. Rapidis AD, et al. "The use of the buccal fat pad for reconstruction of oral defects: Review of the literature and report of cases". *Journal of Oral and Maxillofacial Surgery* 58 (2000): 158-163.
9. Hao SP. "Reconstruction of oral defects with the pedicled buccal fat pad flap". *Otolaryngology Head and Neck Surgery* 122 (2000): 863-867.
10. Dean A, et al. "The buccal fat pad in oral reconstruction". *Head Neck* 23 (2001): 383-388.
11. Samman N, et al. "The buccal fat pad in oral reconstruction". *International Journal of Oral and Maxillofacial Surgery* 22 (1993): 2-6.
12. Verghese BT, et al. "Nasolabial flap in oral reconstruction: An analysis of 224 cases". *British Journal of Plastic Surgery* 54 (2001): 499-503.
13. Rahpeyma A and Khajehahmadi S. "The place of nasolabial flap in orofacial reconstruction: A review". *Annals of Medicine and Surgery* (Lond). 12 (2016): 79-87.
14. Mahieu R, et al. "Oral cavity reconstruction with the masseter flap". *ACTA Otorhinolaryngologica Italica* 36 (2016): 139-143.
15. Conley J and Gullane PJ. "The masseter muscle flap". *Laryngoscope* 88 (1978): 605-612.
16. Tobin GR. "Myocutaneous flaps for head and neck reconstruction". *American Journal of Surgery* 147.3 (1984): 305.
17. Ariyan S. "The pectoralis major myocutaneous flap. A versatile flap for reconstruction in the head and neck". *Plastic and Reconstructive Surgery* 63 (1979): 73.
18. Baliarsing AS, et al. "Flap selection in head and neck cancer reconstruction". *International Journal of Otorhinolaryngology Clinics* 5 (2013): 63-76.
19. Nakajima H, et al. "The arterial anatomy of the temporal region and the vascular basis of various flaps". *British Journal of Plastic Surgery* 48 (1995): 439-450.
20. Agbara R, et al. "The forehead flap: a valuable option in resource depleted environment". *Plastic and Aesthetic Research* 3 (2016): 115-120.

21. Patel UA., *et al.* "Locoregional Flaps for Oral Cavity Reconstruction: A Review of Modern Options". *Otolaryngology-Head and Neck Surgery* 157.2 (2017): 201-209.

Assets from publication with us

- Prompt Acknowledgement after receiving the article
- Thorough Double blinded peer review
- Rapid Publication
- Issue of Publication Certificate
- High visibility of your Published work

Website: www.actascientific.com/

Submit Article: www.actascientific.com/submission.php

Email us: editor@actascientific.com

Contact us: +91 9182824667