



## Pyogenic Granuloma - A Simple Treatment Approach with Sclerotherapy

Shalini Subramanyam<sup>1\*</sup> and Peeyush Shivhare<sup>2</sup>

<sup>1</sup>Independent Researcher, Oral and Maxillofacial Pathologist and Microbiology, India

<sup>2</sup>Department of Oral Medicine and Radiology, Nobel Medical College and Teaching Hospital, Nepal

\*Corresponding Author: Shalini Subramanyam, Independent Researcher, Oral and Maxillofacial Pathologist and Microbiology, India.

Received: February 10, 2021

Published: February 25, 2021

© All rights are reserved by **Shalini Subramanyam and Peeyush Shivhare.**

### Abstract

Pyogenic granuloma (PG) is a benign exophytic vascular tumor, which is actually a reactive inflammatory mass of blood vessels with few fibroblasts within the mucosa or skin, was first reported by Hullihen in 1844.

Variety of treatment options such as surgical excision, laser treatment, electrodesiccation, chemical cautery, cryosurgery, intralesional steroid injection etc. are available, but many a times, recurrence has also been reported.

Sclerotherapy is defined as the “targeted elimination of small vessels, varicose veins and vascular anomalies by the injection of a “sclerosant”. It offers an alternative to conventional methods like surgery, lasers, radio frequency ablation and electrodesiccation procedure with success and less chance of recurrences.

Herein, we present a case of 22 years old female with a clinical diagnosis of PG, treated with intralesional 0.2 ml of 3% sodium tetradecyl sulfate (STS). The lesion healed completely at the patient’s 3<sup>rd</sup> visit and recurrence was not reported till the patient was followed up for one year.

**Keywords:** Pyogenic Granuloma; Sclerotherapy; Sodium Tetradecyl Sulfate

### Introduction

Pyogenic granuloma (PG) is a benign exophytic vascular tumor, which is actually a reactive inflammatory mass of blood vessels with few fibroblasts within the mucosa or skin [1]. Pyogenic granuloma (PG) was first reported by Hullihen in 1844, although the term “Pyogenic Granuloma” or “granuloma pyogenicum” was introduced by Hartzell in 1904. It is a misnomer as the lesion is neither pus-producing nor granulomatous [1,2]. Different treatments for PG are surgical excision, laser treatment, electrodesiccation, chemical cautery intralesional steroid injection etc. but many a times recurrences has also been reported [2].

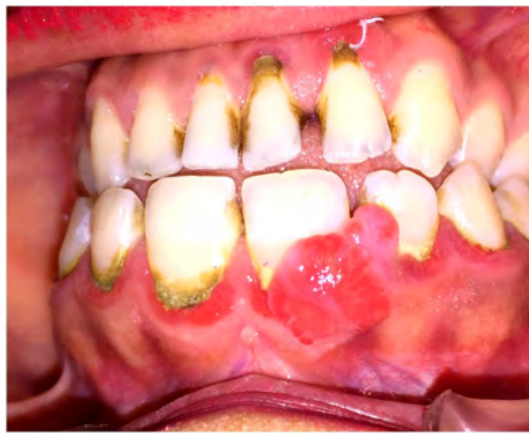Sclerotherapy is defined as the “targeted elimination of small vessels, varicose veins and vascular anomalies by the injection of a “sclerosant” [3]. It offers an alternative to conventional methods like surgery, lasers, radio frequency ablation and electrodesiccation procedure with success and less chance of recurrences [3].

### Case Report

A 22-year-old female reported with complaining of a swelling in the upper left gum region since 2 - 3 month. The patient reported that he noticed the since 2-3 month, which was painless and gradu-

ally increased in size. She also gave history of bleeding brushing the same area.

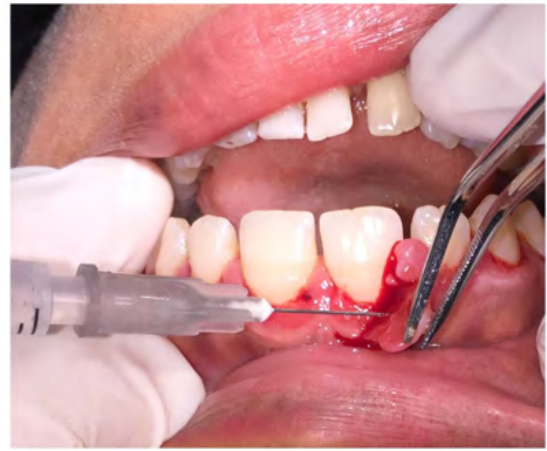Intraoral examination revealed a pedunculated lobulated gingival overgrowth extending on buccal surfaces of 21, 22. It was reddish pink in color and approximately 15 mm × 10 mm in size (Figure 1). The surface was smooth, no ulcerations were seen. Bleeding on touch was evident. Oral hygiene was poor and the oral cavity showed increased amounts of calculus. Teeth associated with it did not show any mobility. Radiographically, there were no visible abnormalities and the alveolar bone in the region of the growth appeared normal. Routine haemogram was found to be normal. A provisional diagnosis of pyogenic granuloma was made.



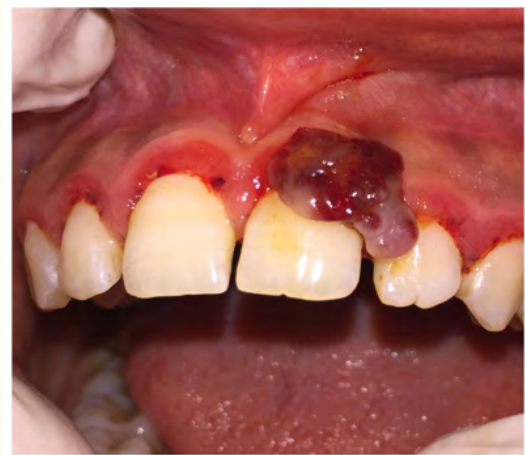**Figure 1:** Clinical appearance of the PG present with respect to 21, 22.

The differential diagnosis included peripheral ossifying fibroma, peripheral giant cell granuloma, hemangioma and fibroma. We advised her for laser excision along with scaling and root planning. Patient was not ready for any surgical procedure, thus we planned for sclerotherapy.

Firstly, Oral prophylaxis was completed. Later, intralesional injection of undiluted 0.2 ml of 3% sodium tetradecyl sulphate injection was given at the base of the pedunculated mass till the point of blanching. After this, the lesion was compressed with cotton gauze for 1 - 2 minutes (Figure 2 and 3). There was no bleeding during the procedure.

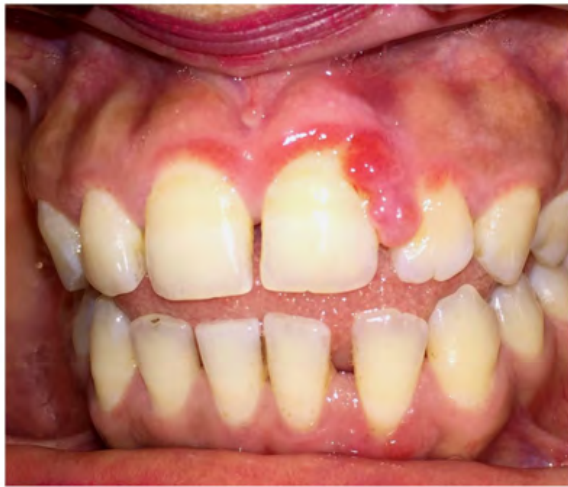

**Figure 2:** Intralesional STS given at the base of the pedunculated mass.

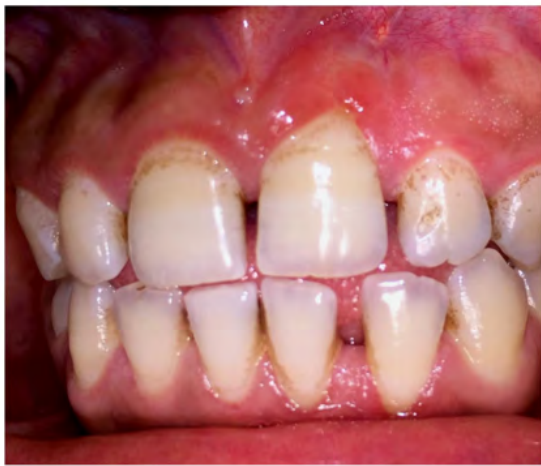

**Figure 3:** Immediately after Intralesional STS lesion color changed to bluish red.

No local anaesthesia was used during the procedure. The patient was completely comfortable. Lesion regressed completely after 2 sessions with no recurrences (Figure 4 and 5).



**Figure 4:** 80% resolution of the mass on 2<sup>nd</sup> visit of patient.



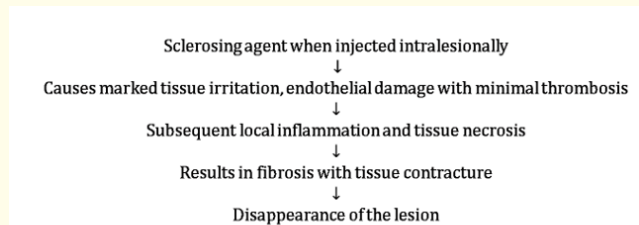
**Figure 5:** Complete resolution of the mass at the patient's 3<sup>rd</sup> visit.

hemorrhage either spontaneously or upon slight trauma. It bleeds easily because of its extreme vascularity. The color varies from red to pink to purple depending on age of the lesion. It arises most frequently on the gingiva, followed by lips tongue and buccal mucosa and occasionally on other areas. It is most common in young female, due to hormonal influences on vasculature. Pyogenic granuloma when appears during pregnancy are termed as pregnancy epulis/tumor or granuloma gravidarum [1,2].

The exact cause is unknown but multiple factors have been implicated in the etiology of pyogenic granuloma. Different precipitating factors for PG are poor oral hygiene, Local irritants such as calculus, foreign material in the gingiva, Chronic low grade trauma, physical trauma, hormonal factors, bacteria, viruses and certain drugs [4].

Different treatments for PG are surgical excision, laser treatment, electrodesiccation, chemical cautery intralesional steroid injection etc. but many a times, recurrence has also been reported [1,2].

Sclerosing agent causes marked tissue irritation, endothelial damage with minimal thrombosis and subsequent local inflammation and tissue necrosis [3]. The inflammation and tissue necrosis results in fibrosis with tissue contracture resulting in the disappearance of the lesion (Figure 6).



**Figure 6:** Mechanism of action of sclerotherapy.

**Discussion**

PG (Pyogenic Granuloma) is an exuberant tissue response to local irritation/bacterial infection or trauma which provides pathway for the invasion of nonspecific microorganisms. Clinically, it is seen as smooth lobulated or even warty, usually pedunculated surface which commonly is ulcerated and shows a tendency for

Varieties of sclerosing agents can be classified based on their chemical properties and their mechanism of action:

- a) Osmotic agents are those which damage the cell by shifting the water balance, example sodium chloride solution with dextrose, hypertonic sodium chloride solution.

- b) Detergents are those which disrupt vein cellular membrane, examples are sodium teradecyl sulfate, sodium morrhuate, Polidocanol, ethanolamine oleate.
- c) Chemical irritants which damage the cell wall, includes chromated glycerin, polyiodinated iodine, OK 432 and Bleomycin [3].

Sodium tetradecyl sulfate (STS) is one of the most commonly used sclerosants for their efficacy and safety profile. It is a long-chain fatty acid manufactured synthetically and is commonly used as a synthetic surfactant (soap). STS is already used in many of the oral lesions such as vascular malformation, lymphangioma, mucocele, and ranula. These agents have been shown promising results [5,6].

A retrospective study was performed by Shivhare P, *et al.* showed complete regression of the pyogenic granuloma in all of the patients [6]. Another study was performed by Khaitan, *et al.* in 40 clinically diagnosed patients of pyogenic granuloma. Patients were treated with 0.2 - 0.5 ml of sodium tetradecyl sulfate. All the patients showed complete regression of the lesions [7]. Maharjan, *et al.* treated a case of Pyogenic granuloma by intralesional injection of undiluted 0.2 ml of STS (30 mg/ml). Lesion regressed completely in 3 sessions with no recurrences [8].

The advantages of this procedure are:

- a) Is easily available.
- b) Safe, reliable and is an effective drug with minimal side effects.
- c) Causes minimal discomfort to the patient.
- d) Negligible blood loss.
- e) Minimal surgical expertise is required.
- f) Economical cost wise.
- g) No requirement of local anesthesia or postoperative dressings or any specific care.
- h) It is Approved by the Food and Drug Association [3].

## Conclusion

Sclerotherapy with sodium tetradecyl sulfate 3% is effective in the treatment of pyogenic granuloma. It offers an alternative to conventional methods like surgery, lasers, radio frequency ablation and electrodesiccation procedure with success and less chance of recurrences.

## Bibliography

1. Jafarzadeh H, *et al.* "Oral pyogenic granuloma: a review". *The Journal of Oral Science* 48.4 (2006): 167-175.
2. Gondivkar SM, *et al.* "Oral pregnancy tumor". *Contemporary Clinical Dentistry* 1.3 (2010): 190-192.
3. Khunger N and Sacchidanand S. "Standard guidelines for care: sclerotherapy in dermatology". *Indian Journal of Dermatology, Venereology and Leprology* 77.2 (2011): 222-231.
4. Gomes SR, *et al.* "Pyogenic granuloma of the gingiva: A misnomer?- A case report and review of literature". *Journal of Indian Society of Periodontology* 17.4 (2013): 514-519.
5. Alakailly X, *et al.* "The Use of Sodium Tetradecyl Sulphate for the Treatment of Venous Malformations of the Head and Neck". *Journal of Oral and Maxillofacial Surgery* 14.2 (2015): 332-338.
6. Shivhare P, *et al.* "Use of Sodium Tetradecyl Sulphate for the Treatment of Oral Lesions". *JCMS Nepal* 15.4 (2019): 282-286.
7. Khaitan T, *et al.* "Conservative approach in the management of oral pyogenic granuloma by sclerotherapy". *Journal of Indian Academy of Oral Medicine and Radiology* 30 (2018): 46-51.
8. Maharjan IK, *et al.* "Sclerotherapy for Oral Pyogenic Granuloma - A case report". *Journal of College of Medical Sciences-Nepal* 13.2 (2017): 290-292.

### Assets from publication with us

- Prompt Acknowledgement after receiving the article
- Thorough Double blinded peer review
- Rapid Publication
- Issue of Publication Certificate
- High visibility of your Published work

Website: [www.actascientific.com/](http://www.actascientific.com/)

Submit Article: [www.actascientific.com/submission.php](http://www.actascientific.com/submission.php)

Email us: [editor@actascientific.com](mailto:editor@actascientific.com)

Contact us: +91 9182824667